



PATIENT

Dixie Watson

PRESENTING CLINICAL SIGNS

History: Has been dribbling urine off and on for at least 2 months

SPECIES

Canine

ULTRASONOGRAPHIC EXAMINATION OF THE ABDOMEN

Urinary System

The **urinary bladder** was mildly thickened with a mildly dilated pelvic urethra. No obvious ectopic ureters were noted; however, further imaging is necessary to rule out this potential.

BREED

French Bulldog

ULTRASONOGRAPHIC FINDINGS

Concentric bladder wall thickening with mildly dilated pelvic urethra.

SEX

Female

INTERPRETATION OF THE FINDINGS & FURTHER RECOMMENDATIONS

IVP or CT with contrast would be ideal to assess for ectopic ureters. Further imaging of the kidneys as well as the region dorsal to the bladder wall and dorsal to the urethra would be appropriate. Urine culture and sensitivity as well as treatment for UTI would be warranted if any inflammatory sediment is present.

WEIGHT

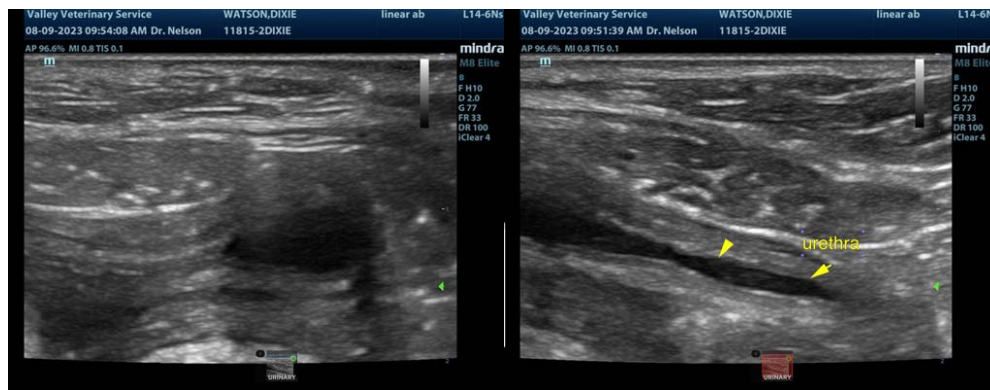
15 lbs

INTERPRETED BY

Eric Lindquist, DMV
DABVP, Cert. IVUSS

IMAGING PERFORMED BY

Peter Nelson

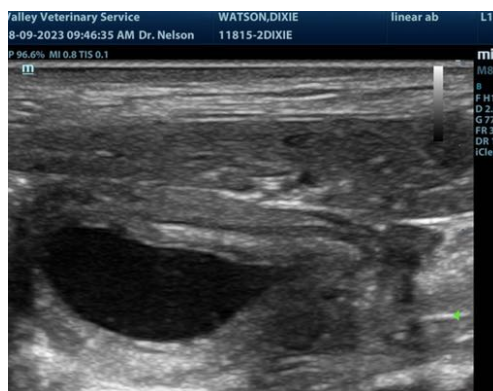

HOSPITAL NAME

Valley Veterinary
Service

REFERRING VET

Dr. Bartus



INVOICE

46516

DATE

8/9/23



PATIENT

Dixie Watson

The information and recommendations provided are based on the images presented by the referring veterinarian/sonographer. No evaluation can be communicated regarding pathology that was not visible in the image/video clips provided.

SPECIES

Canine

Thank you for this referral. If the clinical or image interpretation does not parallel your findings or if I can be of any further assistance please contact me.

BREED

French Bulldog

Eric Lindquist, DMV, DABVP, Cert. IVUSS, CEO of SonoPath.com
info@SonoPath.com

SEX

Female

AGE

5 months

WEIGHT

15 lbs

INTERPRETED BY

Eric Lindquist, DMV
DABVP, Cert. IVUSS

**IMAGING
PERFORMED BY**

Peter Nelson

HOSPITAL NAME

Valley Veterinary
Service

REFERRING VET

Dr. Bartus

INVOICE

46516

DATE

8/9/23