



PATIENT **PRESENTING CLINICAL SIGNS**

Buster Manzer

History: Swelling in the area of the rt salivary gland noted several months ago, another DVM dx salivary mucocele via FNA, progressed and ulcerated, was planning to remove today - Concerned about elevated GGT! Started on antibiotics last week, salivary gland is MUCH improved, given other alterations in labs, elected not to proceed with sx today, US done instead to assess liver and look for cause of GGT elevation. Started Denamarin advanced today, waiting on your review to start Ursodiol. Abnormal PE/Chem/CBC/UA Results: pre-op labs: Chemistry Elevated ALT: 243 (12-118 IU/L) Elevated Alk Phos: 596 (5-131 IU/L) Elevated GGT: 32 (1-12 IU/L) Decreased Creatinine: 0.4 (0.5-1.6 mg/dL) Phosphorus elevated slightly 6.3 (2.5-6.0 mg/dL) Triglyceride 382 (23-291) not a fasted sample, likely incidental Precision PSL 783 - 24-140 U/L supportive of pancreatitis if signs (no GI signs reported per O) Complete Blood Count Neutrophilia/Elevated Total WBC - suspect infectious process Total T4 T4<0.5 Free T4 pending

SPECIES

Canine

BREED

Terrier Mix

SEX

Neutered male

ULTRASONOGRAPHIC EXAMINATION OF THE ABDOMEN

Urinary System

The **urinary bladder**, trigone, and pelvic urethra presented normal thicknesses and normal tone. The ureters were not visible which is normal. No uroliths or sediment were visualized and anechoic urine was present. No evidence of inflammatory or neoplastic changes was noted. Ureteral papillae were normal.

AGE

16 years

The prostate measured 0.6 cm.

WEIGHT

13.5 lbs

The **kidneys** revealed normal size and structure, corticomedullary definition and ratio for this age. The cortices presented largely uniform texture with normal echogenic relationship to liver and spleen. Medullary structure differed distinctly from the cortex and no evidence of pelvic dilation was present.

INTERPRETED BY

Eric Lindquist, DMV
DABVP, Cert. IVUSS

The capsules were acceptably uniform without significant irregularities. The right kidney measured 5.3 cm.

IMAGING PERFORMED BY

Dr. Jackson

Adrenal Glands

The cranial pole of the left adrenal gland was visualized and mildly enlarged measuring 0.85 cm. The right adrenal gland was uniformly enlarged and measured 1.14 cm in maximum width.

HOSPITAL NAME

Ark AH

Spleen

The **spleen** presented a smooth homogeneous parenchyma hyperechoic to liver and renal cortical parenchyma. The capsule was smooth without noticeable expansion or deviation from within the spleen or adjacent pathology. The splenic vasculature demonstrated normal volume without signs of congestion or thrombosis. No sonographic evidence of acute or chronic inflammatory, neoplastic, or infarctual changes was noted.

REFERRING VET

Dr. Lewis

INVOICE

46530

Liver

The **liver** was uniformly swollen with minor, excessive gallbladder debris and over distension with dependent and suspended bile without evidence of overt mucocele formation. However, excessive sludge was present. The liver presented coarse architecture with mildly increased portal markings and subtle, mixed echogenic changes. This is consistent with vacuolar hepatopathy and some level of

DATE

8/9/23



PATIENT

remodeling and history of inflammatory component. Occasional, hypoechoic non-disruptive nodule was noted in the liver. The common bile duct was normal.

Buster Manzer

SPECIES

Gastrointestinal

Canine

Examination of the **gastrointestinal tract** revealed a stomach and intestine free of stasis, of normal wall thickness, acceptable curvilinear mural detail, and peristaltic activity. Small and large intestine demonstrated normal luminal chyme and stool consistency respectively. No obstructive or overt infiltrative disease was noted. No associated abnormal lymphatic activity was noted.

BREED

Terrier Mix

Pancreas

SEX

The base and limbs of the **pancreas** were observed to be largely isoechoic to surrounding omental fat. Pancreatic duct and capsular contour were acceptably normal and parenchyma respected normal curvilinear patterns. No overt evidence of active inflammatory or neoplastic disease was noted.

Neutered male

AGE

ULTRASONOGRAPHIC FINDINGS

16 years

Bilateral adrenal hypertrophy, potential emerging Cushing's/PDH.

WEIGHT

13.5 lbs

INTERPRETATION OF THE FINDINGS & FURTHER RECOMMENDATIONS

INTERPRETED BY

If the urine specific gravity is <1.020 then the following algorithm is recommended. Ursodiol therapy is warranted +/- FNA of the liver, yet this is likely vacuolar hepatopathy/reactive hepatopathy. Reassessment of the gallbladder is recommended in 6 weeks.

Eric Lindquist, DMV
DABVP, Cert. IVUSS

Efficient & Accurate Cushing's Work up-Lindquist

IMAGING PERFORMED BY

Notes regarding Cushing's Clinical Presentations:

Dr. Jackson

Nearly all Cushing's dogs have SAP elevations and true PU/PD (USG < 1.025) and most are polyphagic.

Cushing's dogs are > 6 years and usually > 9 years old, usually have poor skin coats, body scores > 3/5, and are usually sedentary animals.

HOSPITAL NAME

Its important to remember that Cushing's dogs usually look and play the part and other diseases cause false + stress related cortisol spikes. On rare occasion a Cushing's dog will not follow the rules but this is truly an exception.

Ark AH

Potential Cushing's patient workups can be costly and frustrating if not definitive and, in my experience, the non-definitive patient usually has something else going on that may be contributing to some of the clinical signs a Cushing's dog will have, especially SAP elevations or PU/PD. Based on this prelude of information I came up with the following algorithm in the spirit of diagnostic efficiency. The following suggested protocol is based on current available literature on Cushing's disease and extensive clinical-sonographic experience evaluation + Cushing's and False + LDDST & ACTH stim. cases in order to maximize the efficiency of a Cushing's workup in practice.

REFERRING VET

Dr. Lewis

INVOICE

Screen first, workup second

46530

DATE

1) **UA:** Repeatable (2-3 urine samples) Urine specific gravity & urine cortisol/creatinine ratio (UCCR): If **repeatable USG < 10.20 and + UCCR** move to next step 2.

8/9/23



PATIENT

Buster Manzer

SPECIES

Canine

BREED

Terrier Mix

SEX

Neutered male

AGE

16 years

WEIGHT

13.5 lbs

INTERPRETED BY

Eric Lindquist, DMV
DABVP, Cert. IVUSS

IMAGING PERFORMED BY

Dr. Jackson

HOSPITAL NAME

Ark AH

REFERRING VET

Dr. Lewis

INVOICE

46530

DATE

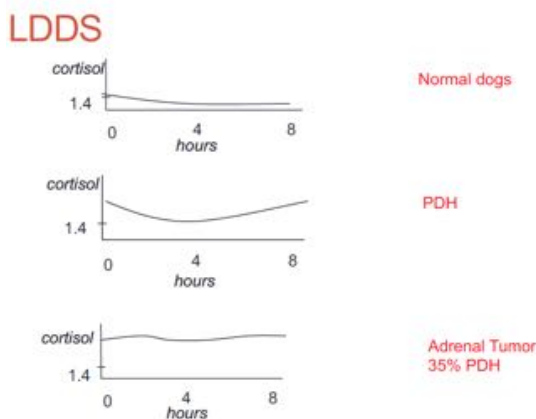
8/9/23

Note: UA is inexpensive and easy to obtain and if UA criteria is not met for Cushing's then resources can be spent into other more pertinent diagnostics or left on hold until the UA criteria is met in emerging Cushing's cases.

2) **Sonogram:** Does the patient **have concurrent disease** clinically or sonographically as non-Cushing's illness will influence the potential false + LDDST or even ACTH stim. The sonogram gives a global perspective of the internal health of the patient to be considered in the Cushing's workup as an assessment of concurrent disease. Is there a concurrent neoplastic process, UTI pancreatitis, mucocele....? Are the adrenals enlarged (Cushing's-PDH, stress, age related or breed variant), or atrophied (iatrogenic Cushing's or adrenal burnout), have asymmetric enlargement (Adrenal tumor, hyperplasia, adenoma, age related variant), or is there vascular invasion (Invasive pheo with false + UA criteria or adenocarcinoma or phrenic thrombosis)? The sonogram answers these questions proactively.

Address & treat concurrent disease first before performing Cushing's testing or testing will be artificially altered increasing false negatives and positives.

3) **LDDST** (0.01 D-Sodium phosphate mg/kg IV **with precise dosing******) (Better screening test but plagued with false + but considered more specific than ACTH stim) Use if there is potential early Cushing's or if adrenal asymmetry present on sonogram suspecting tumor. Use LDDST in cats at a higher dose (0.1 mg/kg IV). **Interpretation LDDST:** Look at 8-hour post first: If > 1.4 = Cushing's. Then look at 4-hour: if > 1.4 or > 50% baseline = Cushing's. 4-hour do then 8-hour spike most consistent with PDH. Flat line high constant curve without dip more consistent with tumor but can be PDH. See attached graph.



Courtesy: Rebecca Berg DACVIM, DECVIM

4) **ACTH stim.** (Better confirming test but can have false +) Use if the patient "looks" Cushingoid or if bilateral adrenal enlargement is present, or high normal width on sonogram, or if iatrogenic Cushing's suspected (Cortisone Tx in past). ACTH stim is better for diagnosis of Addisons, Iatrogenic Cushing's, and Cushing's therapy monitoring but problematic with initial Cushing's diagnosis. First dx LDDST is suggested.

5) If **diabetic** then run both LDDST & ACTH stim but stabilize as much as possible first.

5) Run a **serial blood pressure** in a BP friendly non "white coat effect" atmosphere. Run at least 3 at different times over a few hours or when eating as the patient tends to be calm when eating or give Torbutrol when entering the facility. Cushing's hypertension is usually 150-180 systolic range while pheochromocytoma range is more often > 180 systolic.



PATIENT

Buster Manzer

6) **Perform CT** of the pituitary to identify macro adenoma expansion if any lethargy or dullness or other central clinical CNS signs are minimally present. CT for adrenal may be more thorough for adrenalectomy surgical planning if ultrasound views of the CVC were problematic.

SPECIES

Canine

7) **Adrenectomy** for adrenal mass is prescribed then it is essential to stabilize the patient first regarding secondary disease such as organ dysfunction, hypertension, diabetes mellitus, hypernatremia, thromboembolic risk urinary and other infection in order to minimize potential for operative and postoperative complications as they are common in adrenalectomy. Trilostane stabilization therapy for Cushing's would be the first approach then address surgery and hypertension should be managed ideally < 160 systolic with ace inhibitors, phenoxybenzamine, or amlodipine.

BREED

Terrier Mix

Suggested reading:

SEX

Neutered male

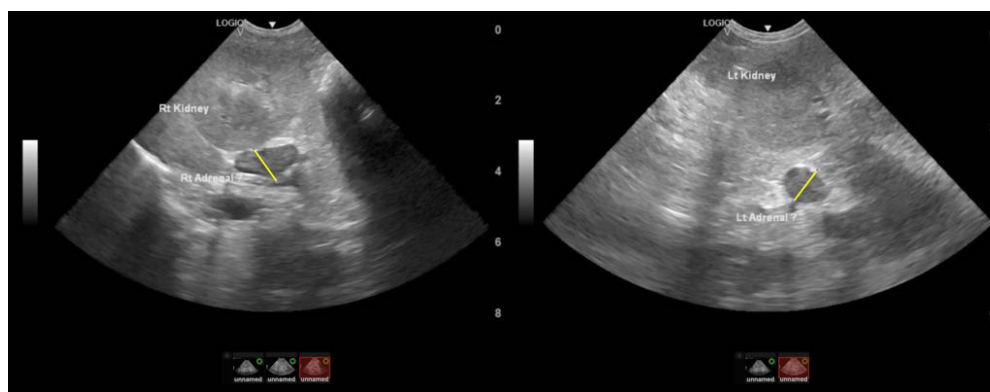
Behrend EN, Kooistra HS, Nelson R, et al. Diagnosis of Spontaneous Canine Hyperadrenocorticism: 2012 ACVIM Consensus Statement (Small Animal). J Vet Intern Med 2013;27:1292-1304 .

AGE

16 years

WEIGHT

13.5 lbs

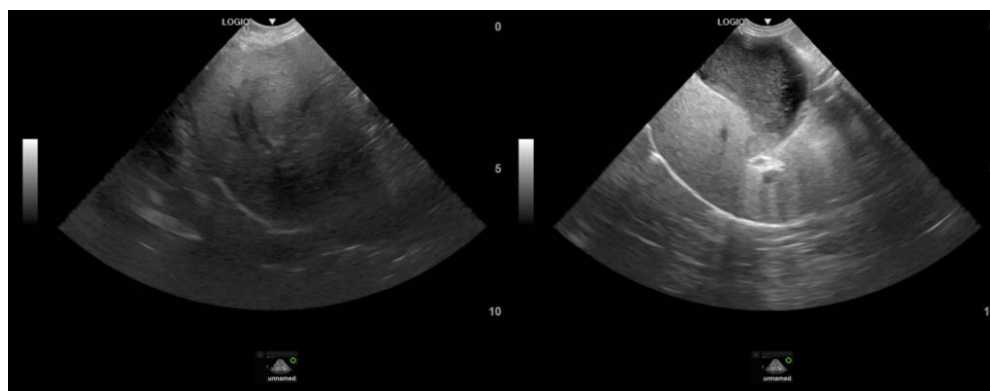


INTERPRETED BY

Eric Lindquist, DMV
DABVP, Cert. IVUSS

IMAGING PERFORMED BY

Dr. Jackson



HOSPITAL NAME

Ark AH

REFERRING VET

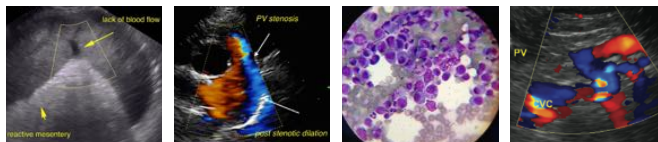
Dr. Lewis

INVOICE

46530

DATE

8/9/23



PATIENT

Buster Manzer

SPECIES

Canine

BREED

Terrier Mix

SEX

Neutered male

AGE

16 years

WEIGHT

13.5 lbs

INTERPRETED BY

Eric Lindquist, DMV
DABVP, Cert. IVUSS

IMAGING PERFORMED BY

Dr. Jackson

HOSPITAL NAME

Ark AH

REFERRING VET

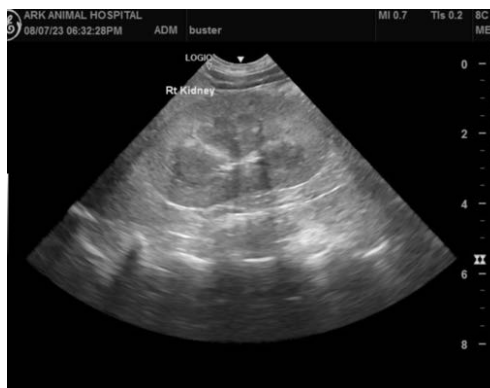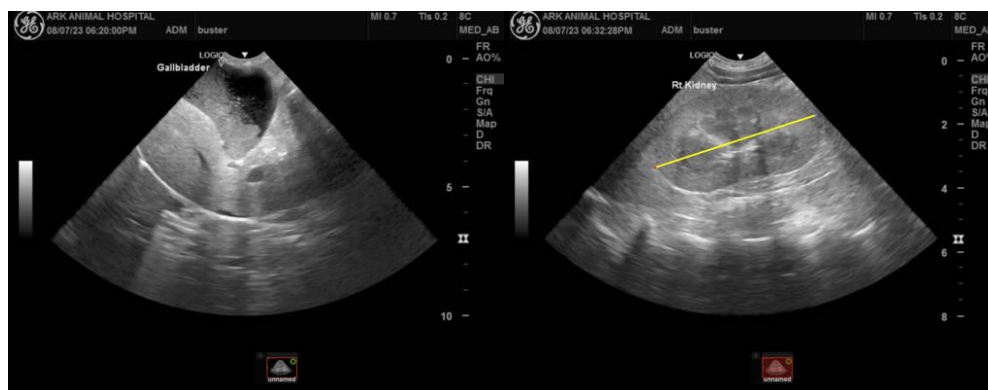
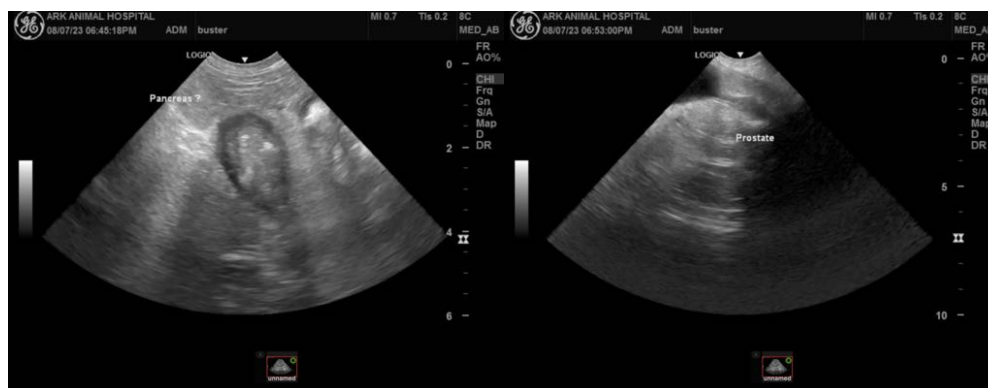
Dr. Lewis

INVOICE

46530

DATE

8/9/23



The information and recommendations provided are based on the images presented by the referring veterinarian/sonographer. No evaluation can be communicated regarding pathology that was not visible in the image/video clips provided.

Thank you for this referral. If the clinical or image interpretation does not parallel your findings or if I can be of any further assistance please contact me.

Eric Lindquist, DMV, DABVP, Cert. IVUSS, CEO of SonoPath.com
info@SonoPath.com