



**PATIENT**

Jake Polley

**SPECIES**

Canine

**BREED**

Boxer

**SEX**

Neutered male

**AGE**

10 years

**WEIGHT**

78 lbs

**INTERPRETED BY**

Eric Lindquist, DMV  
DABVP, Cert. IVUSS

**IMAGING PERFORMED BY**

Dr. Ebersole

**HOSPITAL NAME**

Scanvet

**REFERRING VET**

Dr. Oliver

**INVOICE**

32249

**DATE**

8/9/22

**PRESENTING CLINICAL SIGNS**

History: Ventral neck mass, looking for origin and if it is surgically resectable. US guided FNA done of mass x 2, fat on both sticks.

Abnormal PE/Chem/CBC/UA Results: PE: golf ball sized mass, R ventral neck, deep, near thoracic inlet. BW: all WNL

**ULTRASONOGRAPHIC EXAMINATION**

The right thyroid lobe was uniform and measured 2.22 x 0.38 cm. The left thyroid lobe was uniform and measured 2.36 x 0.32 cm. The parathyroids, salivary glands and regional structures were all unremarkable.

A cervical lipoma was noted in this patient and measured 4.1 x 1.8 cm. The lipoma was in the right cervical region deviating the jugular vein and carotid artery.

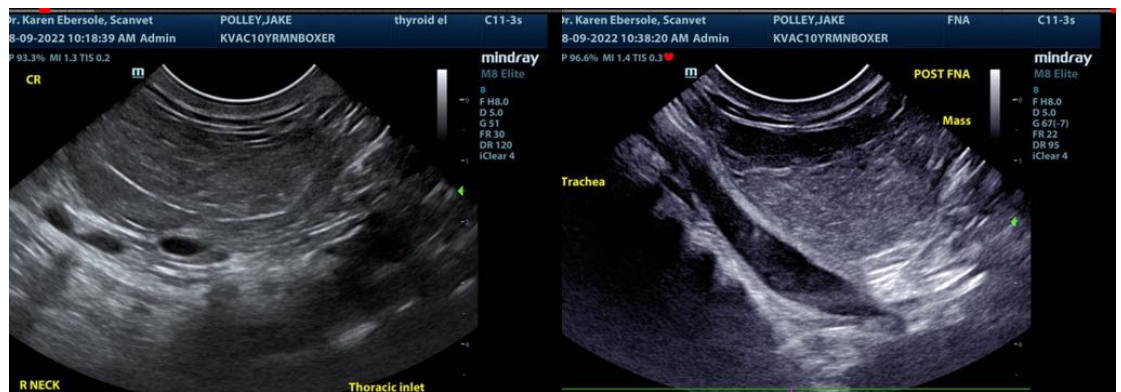
**ULTRASONOGRAPHIC FINDINGS**

Lipomatous type mass with mild deviation of the regional vasculature.

Normal thyroid, parathyroids and salivary glands.

**INTERPRETATION OF THE FINDINGS & FURTHER RECOMMENDATIONS**

The lipoma type mass appears resectable, yet subjectively appears benign.





**PATIENT**

Jake Polley

**SPECIES**

Canine

**BREED**

Boxer

**SEX**

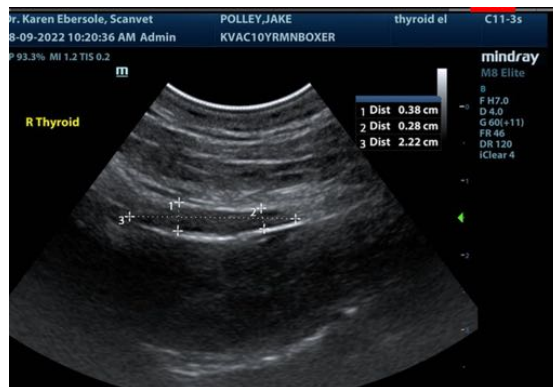
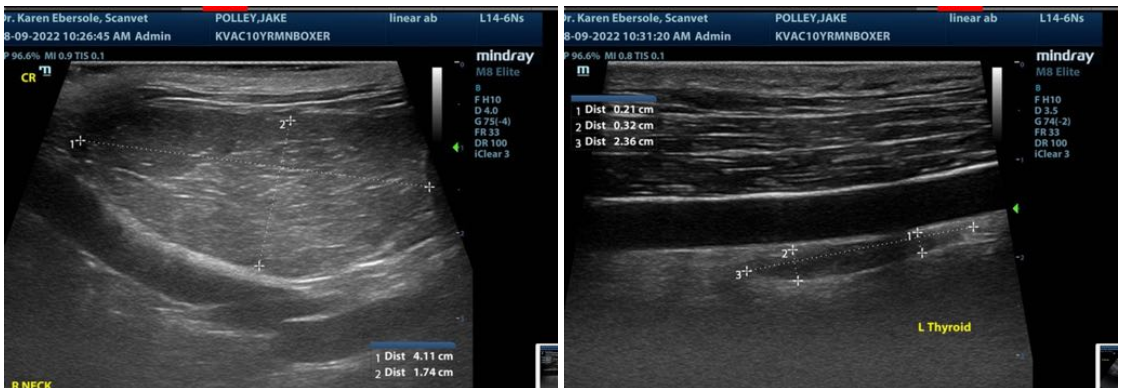
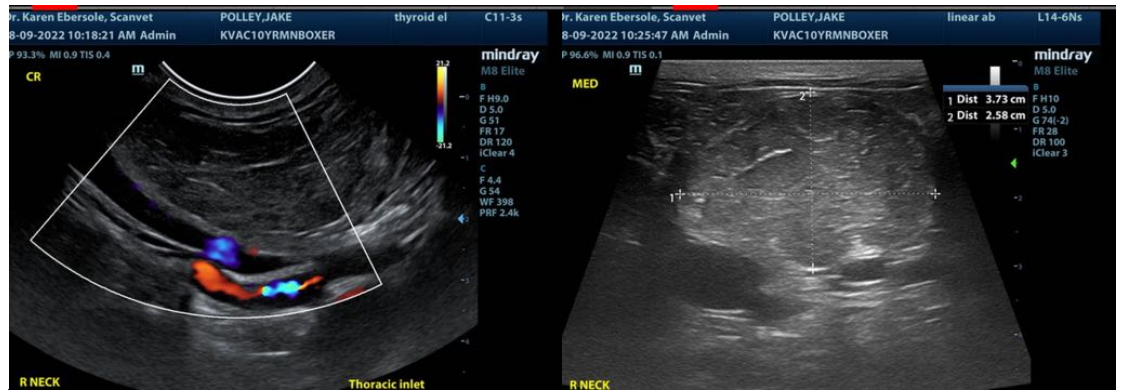
Neutered male

**AGE**

10 years

**WEIGHT**

78 lbs



**INTERPRETED BY**

Eric Lindquist, DMV  
DABVP, Cert. IVUSS

**IMAGING PERFORMED BY**

Dr. Ebersole

**HOSPITAL NAME**

Scanvet

**REFERRING VET**

Dr. Oliver

**INVOICE**

32249

**DATE**

8/9/22

The information and recommendations provided are based on the images presented by the referring veterinarian/sonographer. No evaluation can be communicated regarding pathology that was not visible in the image/video clips provided.

Thank you for this referral. If the clinical or image interpretation does not parallel your findings or if I can be of any further assistance please contact me.

**Eric Lindquist, DMV, DABVP, Cert. IVUSS, CEO of SonoPath.com**  
info@SonoPath.com