



PATIENT

Caspian McCarty

SPECIES

Feline

BREED

Maine Coon

SEX

Neutered male

AGE

13 years

WEIGHT

14.8 lbs

INTERPRETED BY

Eric Lindquist, DMV
DABVP, Cert. IVUSS

IMAGING PERFORMED BY

Dr. Brady

HOSPITAL NAME

Shiloh VH

REFERRING VET

Dr. Schneider

INVOICE

32243

DATE

8/9/22

PRESENTING CLINICAL SIGNS

History: Several week history of recurrent urinary discomfort and hematuria. Concerned about possible mass in bladder vs irregularity of thickened bladder wall

ULTRASONOGRAPHIC EXAMINATION OF THE ABDOMEN

Urinary System

The **urinary bladder** presented minor polypoid wall thickening in cystourethral junction and urethra. At minimal repletion this hyperplastic tissue appears to create a mass effect. Not all neoplastic criteria is met. Reactive fat was noted around the cystourethral junction.

The **kidneys** revealed largely normal size and structure, corticomedullary definition and ratio (cortex 1/3 of medulla) were essentially maintained with some age-related loss of curvilinear patterns regarding the capsule and C/M junction. The cortices presented largely uniform texture with some increased echogenicity expected for his age patient. Medullary structure differed distinctly from that of the cortex and no evidence of pelvic dilation was present. Both kidneys measured 3.5 cm.

Adrenal Glands

Both **adrenal glands** were visualized and recognized as having normal shape, size, position and echogenicity for this breed. The phrenic vasculature, glandular echogenicity and detail were unremarkable. Capsule, cortex, and medullary definition were normal for this age patient.

Spleen

The **spleen** presented a smooth homogeneous parenchyma hyperechoic to liver and renal cortical parenchyma. The capsule was smooth without noticeable expansion or deviation from within the spleen or adjacent pathology. The splenic vasculature demonstrated normal volume without signs of congestion or thrombosis. No sonographic evidence of acute or chronic inflammatory, neoplastic, or infarctual changes was noted.

Liver

The **liver** images submitted revealed subjectively normal liver size, contour, and structure. Parenchymal echogenicity was naturally coarse and hypoechoic to the spleen. Vascular and biliary tracts were of normal volume with no evidence of congestion. The gallbladder presented acceptably thin walls with primarily anechoic content. The cystic and common bile ducts were normal. No pathological hepatic lymphadenopathy was evident. No overt structural evidence of inflammatory, infiltrative or regenerative pathology was evident.

Gastrointestinal

The **gastrointestinal** presentation revealed mild uniform prominence of the gastric mucosa as well as areas of "ropey" small intestinal wall. The muscularis layer was hypertrophied inverting the normal ratio



PATIENT

Caspian McCarty

SPECIES

Feline

BREED

Maine Coon

SEX

Neutered male

AGE

13 years

WEIGHT

14.8 lbs

INTERPRETED BY

Eric Lindquist, DMV
DABVP, Cert. IVUSS

IMAGING PERFORMED BY

Dr. Brady

HOSPITAL NAME

Shiloh VH

REFERRING VET

Dr. Schneider

(1:3). The intestinal submucosa was slightly irregular, thickened and hyperechoic suggestive of low grade, chronic inflammation. No evidence of obstruction was present. Chronic inflammatory bowel disease is probable with a low possibility of an early neoplastic event such as lymphoma or, less likely, dry form FIP can at times be found on biopsy of these presentations. Full thickness tissue biopsies via open laparotomy, ideally guided by intraoperative ultrasound in order to obtain the most representative mural sample, would be necessary to rule more significant disease than IBD.

Pancreas

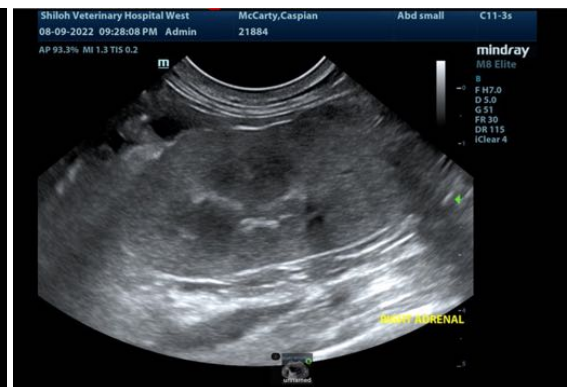
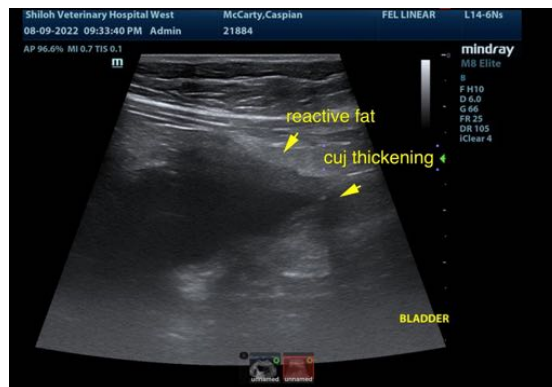
The base and limbs of the **pancreas** were observed to be largely isoechoic to surrounding omental fat. Pancreatic duct and capsular contour were acceptably normal and parenchyma respected normal curvilinear patterns. No overt evidence of active inflammatory or neoplastic disease was noted.

ULTRASONOGRAPHIC FINDINGS

Interstitial cystitis bladder pattern with minor polypoid changes at the cystourethral junction and urethra.

INTERPRETATION OF THE FINDINGS & FURTHER RECOMMENDATIONS

There was no obvious neoplasia in this patient. This is most consistent with interstitial cystitis, urethritis; however, early carcinoma or even bladder lymphoma is a potential given the concurrent intestinal thickening. However, no overt neoplastic criteria is present in the GI tract. I recommend ultrasound-guided traumatic catheterization of the cystourethral junction and urethra to assess cytology. Pain management, broad spectrum antibiotics and supportive care is warranted in the meantime or full thickness bladder biopsies particularly in the caudal ventral wall would be recommended.



INVOICE

32243

DATE

8/9/22



PATIENT

Caspian McCarty

SPECIES

Feline

BREED

Maine Coon

SEX

Neutered male

AGE

13 years

WEIGHT

14.8 lbs

INTERPRETED BY

Eric Lindquist, DMV
DABVP, Cert. IVUSS

IMAGING PERFORMED BY

Dr. Brady

HOSPITAL NAME

Shiloh VH

REFERRING VET

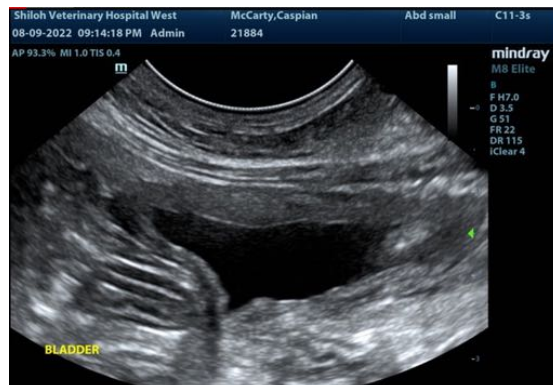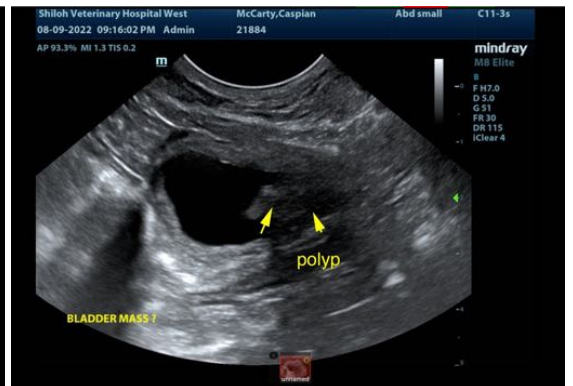
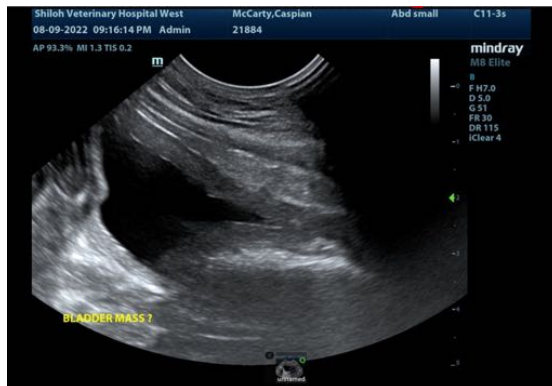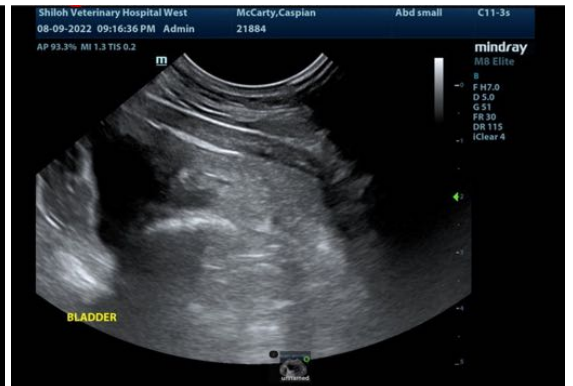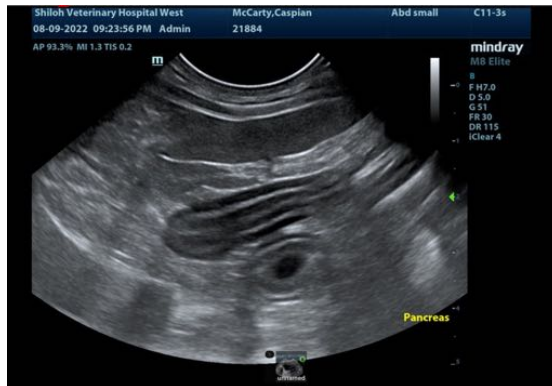Dr. Schneider

INVOICE

32243

DATE

8/9/22



The information and recommendations provided are based on the images presented by the referring veterinarian/sonographer. No evaluation can be communicated regarding pathology that was not visible in the image/video clips provided.

Thank you for this referral. If the clinical or image interpretation does not parallel your findings or if I can be of any further assistance please contact me.

Eric Lindquist, DMV, DABVP, Cert. IVUSS, CEO of SonoPath.com
info@SonoPath.com