



PATIENT

Pixie Mercado

SPECIES

Canine

BREED

Pug

SEX

Female

AGE

7 Months

WEIGHT

5.8 Pounds

INTERPRETED BY

Eric Lindquist, DMV
DABVP, Cert. IVUSS

**IMAGING
PERFORMED BY**

Dra. Yaniris Alvarado

HOSPITAL NAME

Ramey VH

REFERRING VET

Dra. Lesley Rodriguez

INVOICE

23844

DATE

8/8/23

PRESENTING CLINICAL SIGNS

Referred from another clinic for ultrasound. Unable to identify or measure kidneys. Patient started to vomit on Monday, O' though it was due to a change of diet. However, she did not improve with symptomatic treatment. She was hospitalized on Tuesday, but patient is still anorexic and seems more lethargic. In the other clinic they the following blood work and the leptospirosis snap test. Patient has all vaccines UTD. Her family just moved to a new house and they saw rats like a month ago. The O' said that the urine of the patient has always been very clear.

Abnormal PE/Chem/CBC/UA Results: CBC (08/02/2023): RBC, 5.29, HCT 35.7% CBC (08/07/2023): RBC 4.36, HCT 31.4 %, HGB 10.7 g/dL CHEM (08/02/2023): CREA >13.6 mg/dL, BUN >130 mg/dL, PHOS >16.1 mg/dL, CA 13.9 mg/dL, AMYL >2500 U/L, Na 142 mmol/L, Cl 104mmol/L CHEM (08/07/2023): CREA didn't read, BUN >130 mg/dL, PHOS >16.1 mg/dL, ALT 316 U/L, AMYL 2293 U/L, LIPA 4989 U/L, Na 157 mmol/L, Cl 118 mmol/L 4DX: all negative Lepto Snap: Positive

* Near field was excessively dark in this patient. Image quality was nondiagnostic for portions of the abdomen.

ULTRASONOGRAPHIC EXAMINATION OF THE ABDOMEN

Urinary System

The **urinary bladder**, trigone, and pelvic urethra presented normal thicknesses and normal tone. The ureters were not visible which is normal. No uroliths or sediment were visualized and anechoic urine was present. No evidence of inflammatory or neoplastic changes were noted. Ureteral papillae were normal.

The **right kidney** was severely dystrophic and dysplastic. The right kidney was subnormal in size, measuring 2.84 cm.

The **left kidney** was not identified, may be hypoplastic.

Adrenal Glands

The **adrenal glands** were not visualized.

Spleen

The **spleen** was poorly visible. Near field was excessively dark in this patient. Image quality was nondiagnostic for portions of the abdomen.

Liver

The **liver** images submitted revealed subjectively normal liver size, contour, and structure. Parenchymal echogenicity was naturally coarse and hypoechoic to the spleen. Vascular and biliary tracts were of normal volume with no evidence of congestion. The gallbladder presented acceptably thin walls with primarily anechoic content. The cystic and common bile ducts were normal. No pathological hepatic lymphadenopathy was evident. No overt structural evidence of inflammatory, infiltrative or regenerative pathology was evident.

Gastrointestinal

Gastric stasis was present, consistent with ileus. The small intestine and colon were unremarkable.



PATIENT

Pancreas

Pixie Mercado

The base and limbs of the **pancreas** were observed to be largely isoechoic to surrounding omental fat. Pancreatic duct and capsular contour were acceptably normal and parenchyma respected normal curvilinear patterns. No overt evidence of active inflammatory or neoplastic disease was noted.

SPECIES

Canine

ULTRASONOGRAPHIC FINDINGS

BREED

Pug

- Suspect hypoplastic and dysplastic renal disease. Left kidney was not identified/right kidney revealed primary dysplastic pattern.

SEX

Female

INTERPRETATION OF THE FINDINGS & FURTHER RECOMMENDATIONS

Prognosis is poor.

AGE

7 Months

WEIGHT

5.8 Pounds

INTERPRETED BY

Eric Lindquist, DMV
DABVP, Cert. IVUSS

IMAGING PERFORMED BY

Dra. Yaniris Alvarado

HOSPITAL NAME

Ramey VH

REFERRING VET

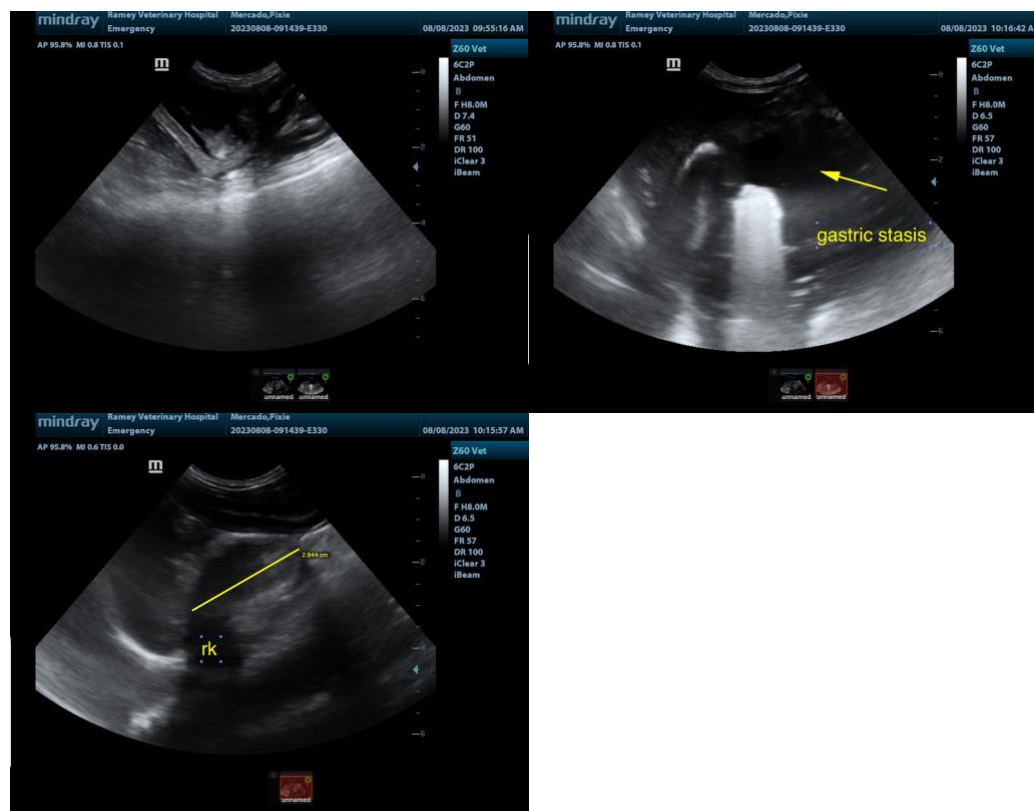
Dra. Lesley Rodriguez

INVOICE

23844

DATE

8/8/23



The information and recommendations provided are based on the images presented by the referring veterinarian. No evaluation can be communicated regarding pathology that was not visible in the image/video clips provided.

Thank you for this referral. If the clinical or image interpretation does not parallel your findings or if I can be of any further assistance please contact me.

Eric Lindquist, DMV, DABVP, Cert. IVUSS, CEO of SonoPath.com



PATIENT

info@SonoPath.com

Pixie Mercado

SPECIES

Canine

BREED

Pug

SEX

Female

AGE

7 Months

WEIGHT

5.8 Pounds

INTERPRETED BY

Eric Lindquist, DMV
DABVP, Cert. IVUSS

**IMAGING
PERFORMED BY**

Dra. Yaniris Alvarado

HOSPITAL NAME

Ramey VH

REFERRING VET

Dra. Lesley Rodriguez

INVOICE

23844

DATE

8/8/23