



**PATIENT**

Vita Stapleton

**SPECIES**

Feline

**BREED**

Tabby

**SEX**

Spayed Female

**AGE**

14 Years

**WEIGHT**

10.28 Pounds

**INTERPRETED BY**

Eric Lindquist, DMV  
DABVP, Cert. IVUSS

**IMAGING PERFORMED BY**

Jessica Miller

**HOSPITAL NAME**

Westwood Regional  
VH

**REFERRING VET**

Dr. Silver

**INVOICE**

16784

**DATE**

8/8/22

**PRESENTING CLINICAL SIGNS**

History: CRD + DM

Abnormal PE/Chem/CBC/UA Results: Elevated WBC, BUN, Creat, Phos and G

**ULTRASONOGRAPHIC EXAMINATION OF THE ABDOMEN**

**Urinary System**

The **urinary bladder**, trigone, and pelvic urethra presented normal thicknesses and normal tone. The ureters were not visible which is normal. No uroliths or sediment were visualized, and anechoic urine was present. No evidence of inflammatory or neoplastic changes were noted. Ureteral papillae were normal.

The **kidneys** were swollen. The left kidney measured 4.1 cm. The right kidney measured 7.09 cm. Hyperechoic ill-defined fat was noted around the kidneys, suggestive for inflammation.

**Adrenal Glands**

The **left adrenal gland** was enlarged, hypoechoic and irregular, measuring 0.75 cm.

The **right adrenal gland** measured the upper limits of normal, 0.72 cm.

**Spleen**

The **spleen** presented a smooth homogeneous parenchyma hyperechoic to liver and renal cortical parenchyma. The capsule was smooth without noticeable expansion or deviation from within the spleen or adjacent pathology. The splenic vasculature demonstrated normal volume without signs of congestion or thrombosis. No sonographic evidence of acute or chronic inflammatory, neoplastic, or infarctual changes were noted.

**Liver**

The **liver** was mildly swollen and hyperechoic to falciform fat. Subtle hypoechoic nodular changes were noted. The gallbladder was empty and unremarkable.

**Gastrointestinal**

The **stomach** was filled with shadowing material in the pyloric outflow, consistent with hairball density. The small intestine and colon were unremarkable.

**Pancreas**

The **pancreas** was hypoechoic and irregular with undulating contour. These are largely age-related changes. The right limb of the pancreas was enlarged, measuring 1.3 cm with hyperechoic surrounding fat, suggestive for inflammation.

**ULTRASONOGRAPHIC FINDINGS**

- Hairball density in the stomach
- Chronic active pancreatitis presentation
- Swollen kidneys, particularly in the right
- Bilateral adrenal enlargement, more prominent in the left adrenal gland
- Hepatic lipidosis pattern



**PATIENT**

Vita Stapleton

**SPECIES**

Feline

**BREED**

Tabby

**SEX**

Spayed Female

**AGE**

14 Years

**WEIGHT**

10.28 Pounds

**INTERPRETED BY**

Eric Lindquist, DMV  
DABVP, Cert. IVUSS

**IMAGING PERFORMED BY**

Jessica Miller

**HOSPITAL NAME**

Westwood Regional  
VH

**REFERRING VET**

Dr. Silver

**INVOICE**

16784

**DATE**

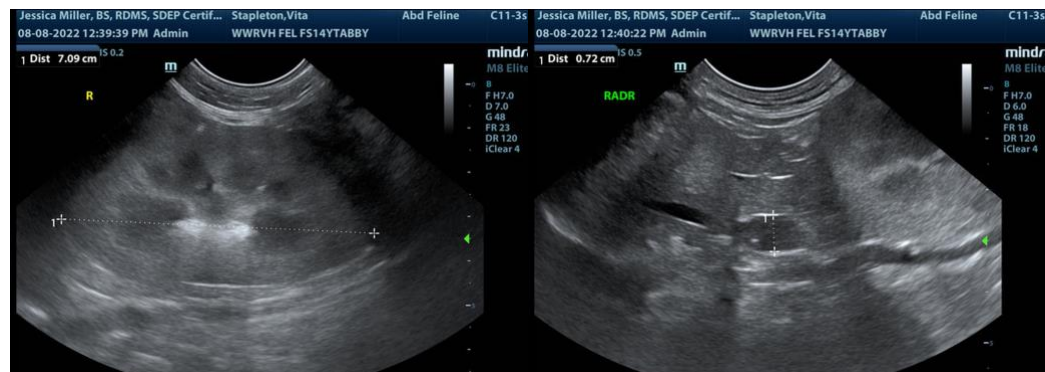
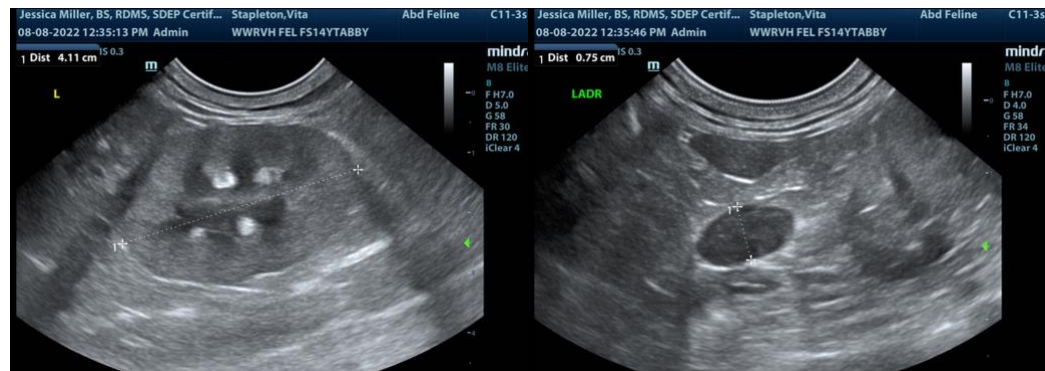
8/8/22

**INTERPRETATION OF THE FINDINGS & FURTHER RECOMMENDATIONS**

There are multiple issues in this patient. The renomegaly is concerning. The renomegaly, in part, is likely owing to the diabetic state, however, the bilateral adrenal enlargement may indicate a fairly rare, but potential Cushings disease/PDH. 72-hour IV fluid support, full urinary work up with culture and sensitivity and blood pressure measurements are indicated +/- aldosterone levels if sodium/potassium ratios are off. Work up for pituitary dependent hyperadrenocorticism should be considered, especially if diabetic dysregulation is an issue. Both prerenal and renal disease is likely playing a role in the azotemia given the chronic active pancreatitis. Treatment for pancreatitis is warranted. Broad spectrum antibiotics and pain management are also indicated.

For an additional charge, internal medicine consult can be utilized through SonoPath.com. You can select the internal medicine drop down at <http://spa.sonopath.com/>.

One of the world's top internists & SonoPath associate Dr. Remo Lobetti BVSc, MMedVet, PhD, DECVIM can evaluate your case through SonoPath. <https://sonopath.com/resources/sonopath-services/internal-medicine-teleconsultation-services>





**PATIENT**

Vita Stapleton

**SPECIES**

Feline

**BREED**

Tabby

**SEX**

Spayed Female

**AGE**

14 Years

**WEIGHT**

10.28 Pounds

**INTERPRETED BY**

Eric Lindquist, DMV  
DABVP, Cert. IVUSS

**IMAGING PERFORMED BY**

Jessica Miller

**HOSPITAL NAME**

Westwood Regional  
VH

**REFERRING VET**

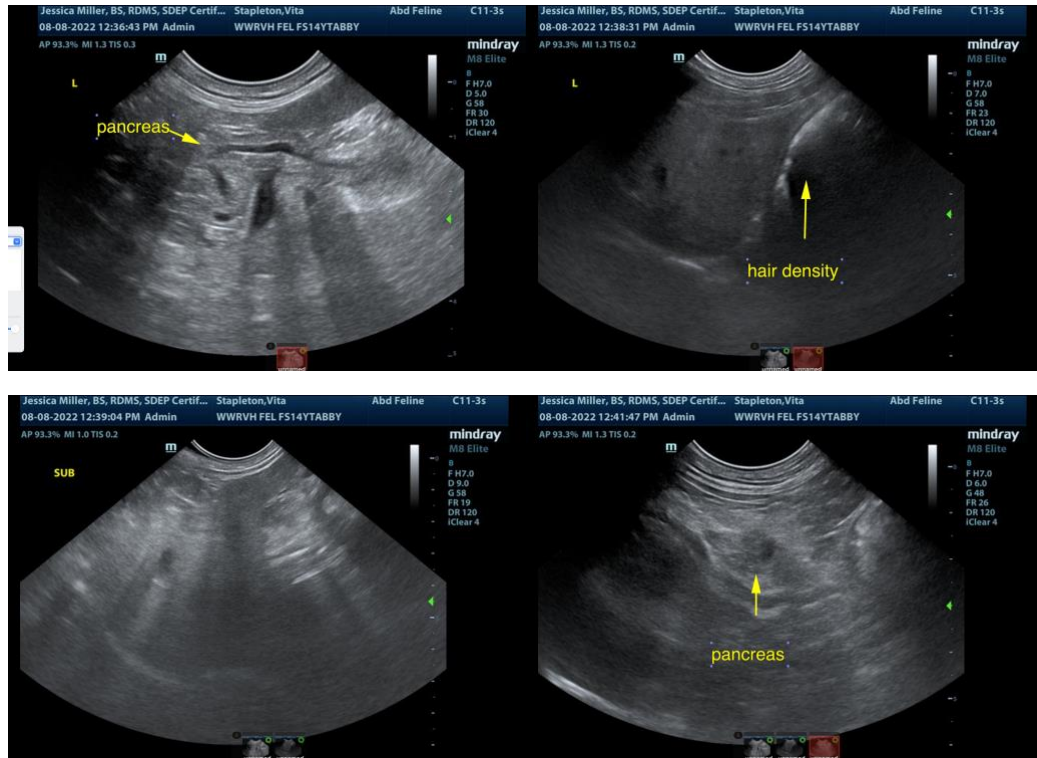
Dr. Silver

**INVOICE**

16784

**DATE**

8/8/22



**The information and recommendations provided are based on the images presented by the referring veterinarian. No evaluation can be communicated regarding pathology that was not visible in the image/video clips provided.**

Thank you for this referral. If the clinical or image interpretation does not parallel your findings or if I can be of any further assistance please contact me.

**Eric Lindquist**, DMV, DABVP, Cert. IVUSS, CEO of SonoPath.com  
info@SonoPath.com