



PATIENT

Pierce Candy

SPECIES

Canine

BREED

Plott Hound

SEX

Neutered male

AGE

11 years

WEIGHT

83.5 lbs

INTERPRETED BY

Eric Lindquist, DMV
DABVP, Cert. IVUSS

IMAGING PERFORMED BY

Dr. Kivircik

HOSPITAL NAME

Kings VH

REFERRING VET

Dr. Kivircik

INVOICE

32225

DATE

8/8/22

PRESENTING CLINICAL SIGNS

History: Vomiting, diarrhea, lethargy. Vomiting and diarrhea resolved with supportive care. Abnormal PE/Chem/CBC/UA Results: Bloodwork ran on 8/8/22- mild anemia, giardia SNAP negative, CPLI and Fecal test pending.

ULTRASONOGRAPHIC EXAMINATION OF THE ABDOMEN

Urinary System

The **urinary bladder**, trigone, and pelvic urethra presented normal thicknesses and normal tone. The ureters were not visible which is normal. No uroliths or sediment were visualized and anechoic urine was present. No evidence of inflammatory or neoplastic changes was noted. Ureteral papillae were normal.

The **kidneys** revealed normal size and structure, corticomedullary definition and ratio for this age. The cortices presented largely uniform texture with normal echogenic relationship to liver and spleen. Medullary structure differed distinctly from the cortex and no evidence of pelvic dilation was present. The capsules were acceptably uniform without significant irregularities. The left kidney measured 5.0 cm.

Adrenal Glands

The **adrenal glands** were not visualized.

Spleen

The **spleen** in this patient was mildly enlarged with uniform parenchyma and was folded upon itself cranially. This is a positional variant and is not pathological. There was no evidence of significant disease.

Liver

The **liver** was uniformly swollen with minor, excessive gallbladder debris and over distension with dependent and suspended bile without evidence of overt mucocele formation. However, excessive sludge was present. The liver presented coarse architecture with mildly increased portal markings and subtle, mixed echogenic changes. This is consistent with vacuolar hepatopathy and some level of remodeling and history of inflammatory component. There was no overt suspicion of neoplasia.

Gastrointestinal

Examination of the **gastrointestinal tract** revealed a stomach and intestine free of stasis, of normal wall thickness, acceptable curvilinear mural detail, and peristaltic activity. Small and large intestine demonstrated normal luminal chyme and stool consistency respectively. No obstructive or overt infiltrative disease was noted. No associated abnormal lymphatic activity was noted.



PATIENT

Pancreas

Pierce Candy

The base and limbs of the **pancreas** were observed to be largely isoechoic to surrounding omental fat. Pancreatic duct and capsular contour were acceptably normal and parenchyma respected normal curvilinear patterns. No overt evidence of active inflammatory or neoplastic disease was noted.

SPECIES

Canine

ULTRASONOGRAPHIC FINDINGS

BREED

Plott Hound

Structurally unremarkable abdomen.

Largely age related abdominal changes.

SEX

Neutered male

INTERPRETATION OF THE FINDINGS & FURTHER RECOMMENDATIONS

Anti-parasitic protocol may prove effective. Screening for Addison's is warranted as the adrenal glands are not visible.

AGE

11 years

Helicobacter/Gastritis protocol

A clinical trial of **Zithromax (Dogs: 5-10 mg/kg p.o. q24h**. May increase dosing interval to q48h after 3-5 days of treatment), **Metronidazole (10-20 mg/kg p.o. b.i.d.)**, **Pepcid (0.5-1 mg/kg s.i.d.)** and **Sucralfate (0.5-2 g/dog PO)** or **Omeprazole (1 mg/kg p.o. s.i.d.)** over the next 3 weeks along with a **novel-protein or hydrolyzed diet** with slurry feeding b.i.d./t.i.d. over the next 2-4 days and then increase to canned diet bid. Dry food should be avoided over the next 4 weeks. A recheck sonogram to assess GI improvement or progression would be ideal in 4 weeks.

WEIGHT

83.5 lbs

INTERPRETED BY

Eric Lindquist, DMV
DABVP, Cert. IVUS

IMAGING PERFORMED BY

Dr. Kivircik

HOSPITAL NAME

Kings VH

REFERRING VET

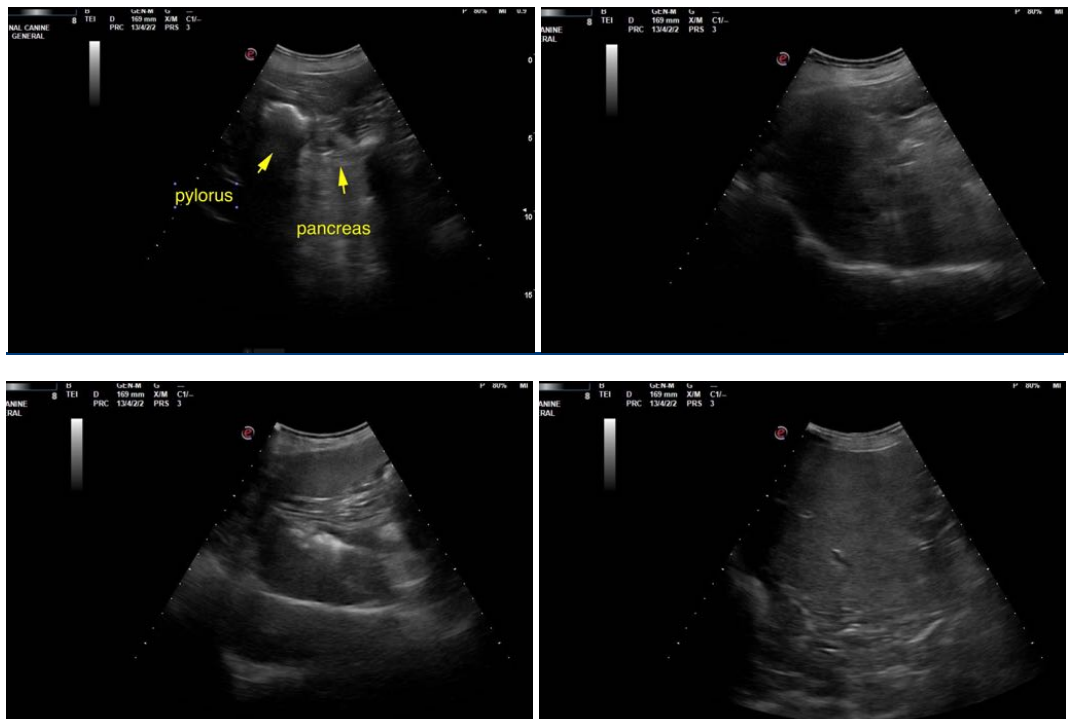
Dr. Kivircik

INVOICE

32225

DATE

8/8/22





PATIENT

Pierce Candy

SPECIES

Canine

BREED

Plott Hound

SEX

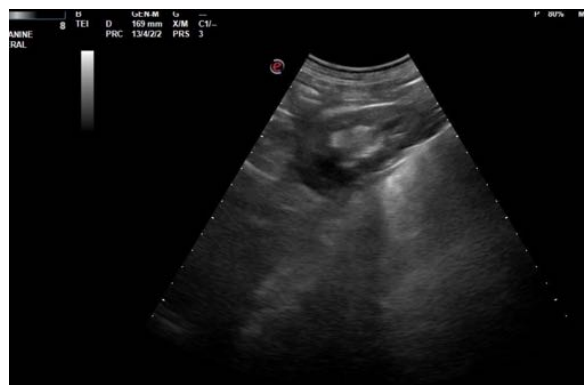Neutered male

AGE

11 years

WEIGHT

83.5 lbs



The information and recommendations provided are based on the images presented by the referring veterinarian/sonographer. No evaluation can be communicated regarding pathology that was not visible in the image/video clips provided.

Thank you for this referral. If the clinical or image interpretation does not parallel your findings or if I can be of any further assistance please contact me.

Eric Lindquist, DMV, DABVP, Cert. IVUSS, CEO of SonoPath.com
info@SonoPath.com

INTERPRETED BY

Eric Lindquist, DMV
DABVP, Cert. IVUSS

IMAGING PERFORMED BY

Dr. Kivircik

HOSPITAL NAME

Kings VH

REFERRING VET

Dr. Kivircik

INVOICE

32225

DATE

8/8/22