


PATIENT

Molly Peterson

PRESENTING CLINICAL SIGNS

History: murmur has progressed, CHF. On furosemide 12.5 mg, enalapril 2.5 mg, pimobendan 1.25mg

SPECIES

Canine

ULTRASONOGRAPHIC EXAMINATION OF THE HEART
BREED

Cavachon

CANINE CARDIAC PARAMETERS	MR VMAX (m/s)	TR VMAX (m/s)	LA/AO (Boon method)	LA/AO (Heart Base; Swe)	FS (%)	EF (%)	EPSS (cm)
NORMAL PARAMETER	4.5-5.5	<2.7	1.3	<1.3	28-40	40-100	<0.6
PATIENT	5.61	3.54	1.6	1.94	41	73	0.1
CANINE CARDIAC PARAMETERS	HR (BPM)	AV VMAX (m/s)	PV MAX (m/s)	BODY WEIGHT (kg)	LA 2D short axis Base view (cm)	LVIDd Avg; 2D and m-mode short axis (cm)	LVIDs Avg; 2D and m-mode short axis (cm)
NORMAL PARAMETER	50-100	0.7-1.7	0.7-1.6				
PATIENT	148	1.21	--	--	3.21	3.39	--

SEX

Spayed Female

AGE

10 Years

WEIGHT

17.5 Pounds

Cardiac Presentation

The cardiac presentation in this patient presented persistent mitral and tricuspid insufficiency. The left ventricular volume was mildly excessive. Aortic insufficiency was noted at 3.50 m/s. The left atrial volume was mildly excessive yet fairly well contained. No pericardial or pleural effusion was noted. Moderate pulmonary hypertension was present. Contractility was adequate. The hepatic veins were noted dilated.

INTERPRETED BY

 Eric Lindquist, DMV
 DABVP, Cert. IVUSS

ULTRASONOGRAPHIC FINDINGS

- Mitral and tricuspid insufficiency with mild persistent volume overload

IMAGING PERFORMED BY

Diane McFadden

HOSPITAL NAME

Fredon AH

INTERPRETATION OF THE FINDINGS & FURTHER RECOMMENDATIONS

I recommend proactively adding Spironolactone (1-2 mg/kg BID) to this patients current triple therapy protocol. BUN, creatinine and urine specific gravity should all be monitored after 5-7 days of adjustment of medications, as well as blood pressures and sleeping respiratory rate, target <25 p/m. Recheck echo in 3-6 months or earlier if clinical signs ensue.

REFERRING VET

Dr. Roche

INVOICE

16779

DATE

8/8/22



PATIENT

Molly Peterson

SPECIES

Canine

BREED

Cavachon

SEX

Spayed Female

AGE

10 Years

WEIGHT

17.5 Pounds

INTERPRETED BY

Eric Lindquist, DMV
DABVP, Cert. IVUSS

IMAGING PERFORMED BY

Diane McFadden

HOSPITAL NAME

Fredon AH

REFERRING VET

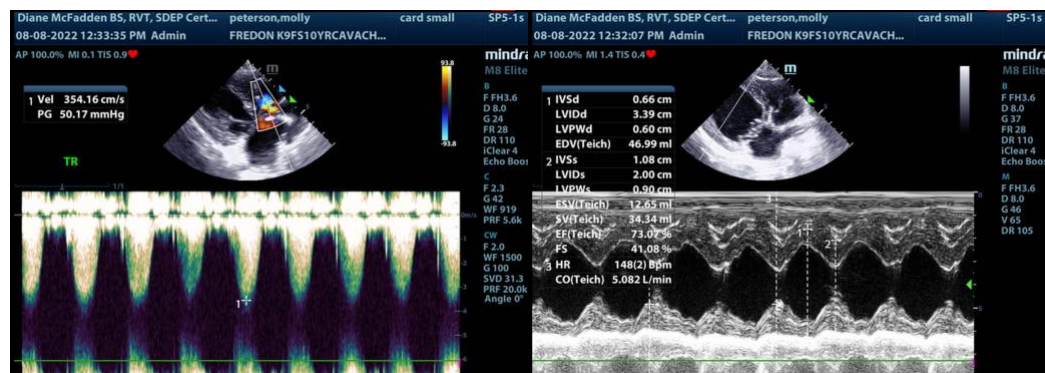
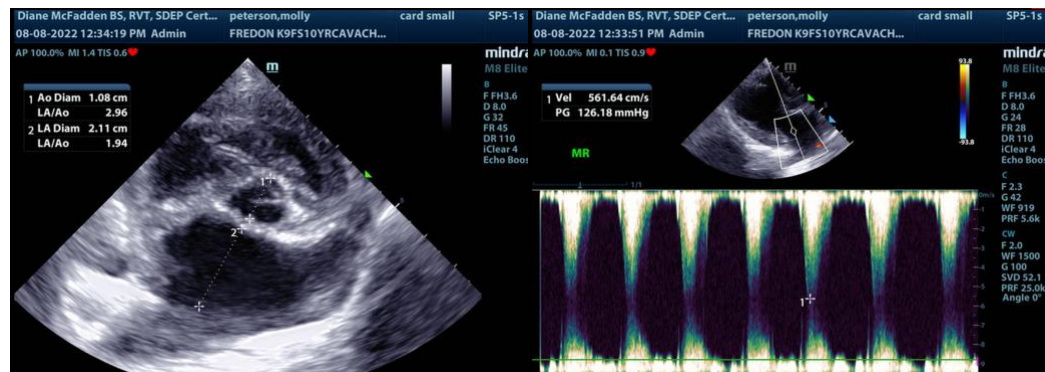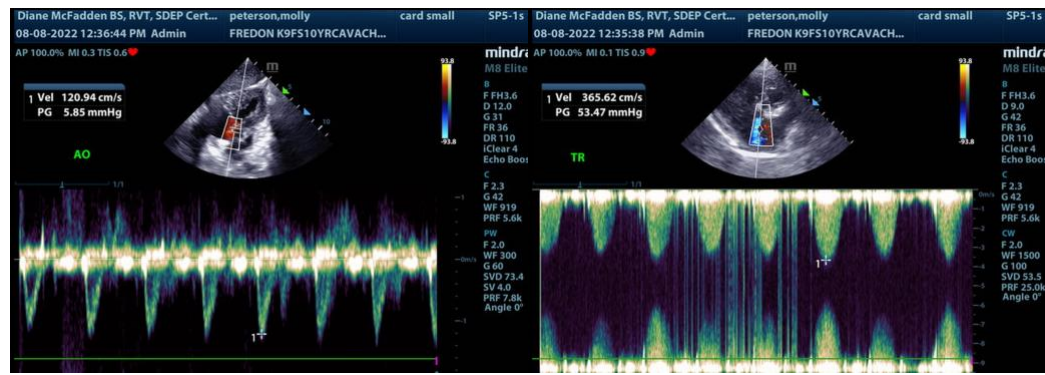
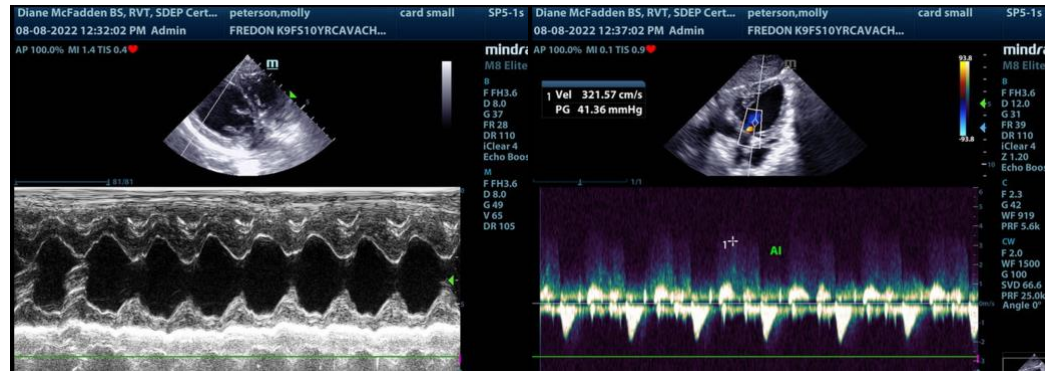
Dr. Roche

INVOICE

16779

DATE

8/8/22





PATIENT

Molly Peterson

SPECIES

Canine

BREED

Cavachon

SEX

Spayed Female

AGE

10 Years

WEIGHT

17.5 Pounds

INTERPRETED BY

Eric Lindquist, DMV
DABVP, Cert. IVUSS

**IMAGING
PERFORMED BY**

Diane McFadden

HOSPITAL NAME

Fredon AH

REFERRING VET

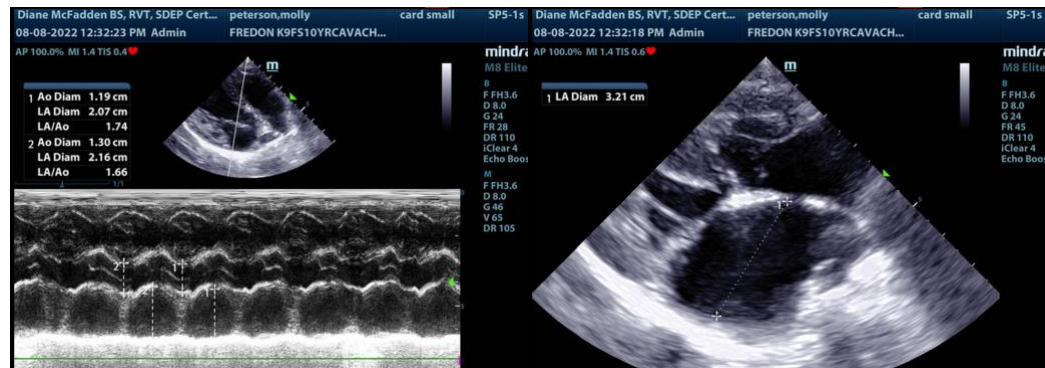Dr. Roche

INVOICE

16779

DATE

8/8/22



The information and recommendations provided are based on the images presented by the referring veterinarian. No evaluation can be communicated regarding pathology that was not visible in the image/video clips provided.

Thank you for this referral. If the clinical or image interpretation does not parallel your findings or if I can be of any further assistance please contact me.

Eric Lindquist, DMV, DABVP, Cert. IVUSS, CEO of SonoPath.com
info@SonoPath.com