



**DATE PRESENTING CLINICAL SIGNS**

8/8/22

Diagnosed with cancer. Oncologist want a pre-treatment ultrasound.  
Current Medications: Clavamox 125 mg BID CPM 4 mg 1 BID.  
Date of Previous IntraPet Ultrasound: No previous.  
Sedation: Declined.  
Stat Report: Not requested.  
Imaging Performed By: Rachel Brillhart, RDMS.

**PATIENT**

Cody Edmiston

**SPECIES**

Canine

**BREED**

Mix

**SEX**

Neutered male

**AGE**

8/23/10

**WEIGHT**

28 lbs

**ULTRASONOGRAPHIC EXAMINATION OF THE ABDOMEN**

**Urinary System**

The **urinary bladder**, trigone, and pelvic urethra presented normal thicknesses and normal tone. The ureters were not visible which is normal. No uroliths or sediment were visualized and anechoic urine was present. No evidence of inflammatory or neoplastic changes was noted. Ureteral papillae were normal.

The **kidneys** revealed largely normal size and structure, corticomedullary definition and ratio (cortex 1/3 of medulla) were essentially maintained with some age-related loss of curvilinear patterns regarding the capsule and C/M junction. The cortices presented largely uniform texture with some increased echogenicity expected for his age patient. Medullary structure differed distinctly from that of the cortex and no evidence of pelvic dilation was present. Mineralization was noted in the kidneys. The left kidney measured 5.4 cm. The right kidney measured 4.83 cm with corticomedullary calculi that measured up to 0.3 cm.

**Adrenal Glands**

The left **adrenal gland** was mildly enlarged and uniform measuring 2.14 x 0.73 cm at the caudal pole and 0.71 cm at the cranial pole. The right adrenal gland was uniform in size and contour measuring 2.16 x 0.65 cm at the caudal pole and 0.62 cm at the cranial pole.

**INTERPRETED BY**

Eric Lindquist, DMV  
DABVP, Cert. IVUSS

**Spleen**

The **spleen** revealed an expansive 7.0 cm echogenic and attenuating parenchymal mass at the caudal pole of the spleen. A separate hypoechoic mass was noted at the cranial pole of the spleen and measured 5.0 cm. Subtle, micronodular changes were noted through the remainder of the spleen.

**HOSPITAL NAME**

Glen Burnie AH

**REFERRING VET**

Dr. Shah

**Liver**

The **liver** images from right and left intercostal as well as subcostal views revealed subjectively normal liver size, contour, and structure. Some age-related parenchymal remodeling was noted but likely not clinically significant at this time. Vascular and biliary tracts were of normal volume and no evidence of congestion was noted. The gallbladder presented some dependent debris with essentially normal contour. The cystic and common bile ducts were normal. No overt evidence of active inflammatory, infiltrative or regenerative pathology was noted but should be paired with current or past LE elevations regarding any clinical significance to this presentation. The hepatic lymph nodes were unremarkable.

**INVOICE**

32207

**Gastrointestinal**

Examination of the **gastrointestinal tract** revealed a stomach and intestine free of stasis, of normal wall thickness, acceptable curvilinear mural detail, and peristaltic activity. Small and large intestine demonstrated normal luminal chyme and stool consistency respectively. No obstructive or overt infiltrative disease was noted. No associated abnormal lymphatic activity was noted.

### **Pancreas**

The base and limbs of the **pancreas** were observed to be largely isoechoic to surrounding omental fat. Pancreatic duct and capsular contour were acceptably normal and parenchyma respected normal curvilinear patterns. No overt evidence of active inflammatory or neoplastic disease was noted.

### **Heart**

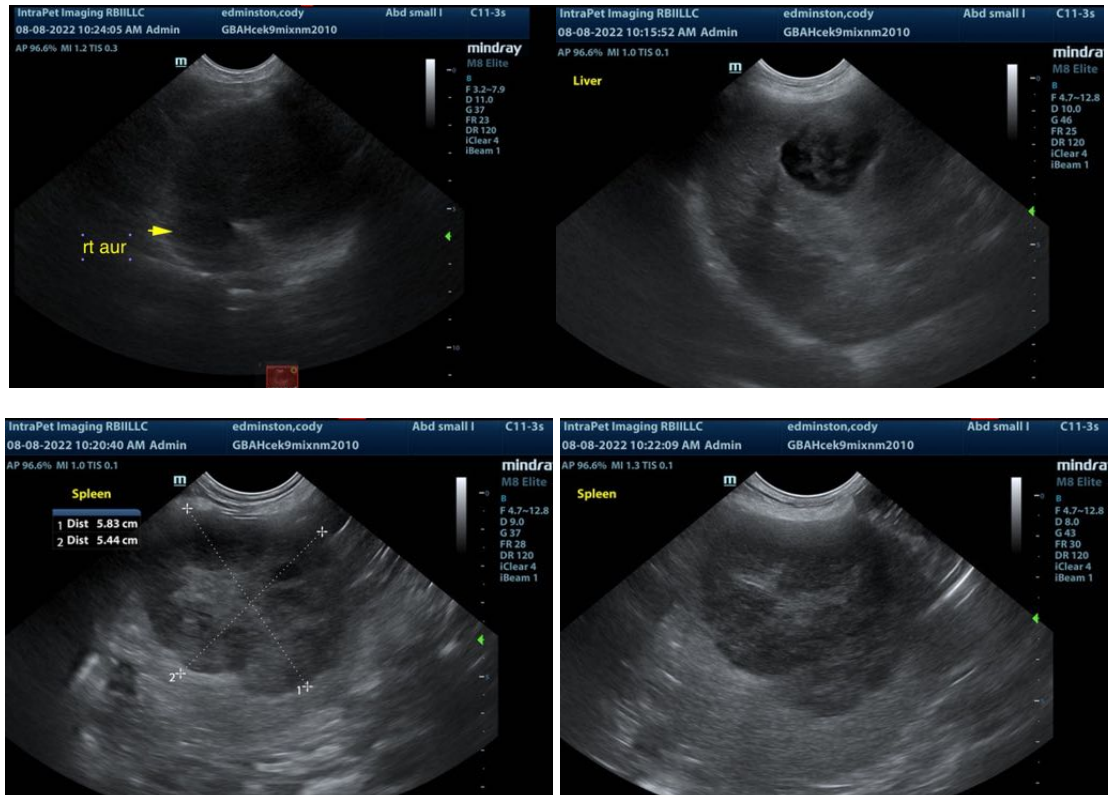
Rapid view of the heart revealed no evidence of pathology.

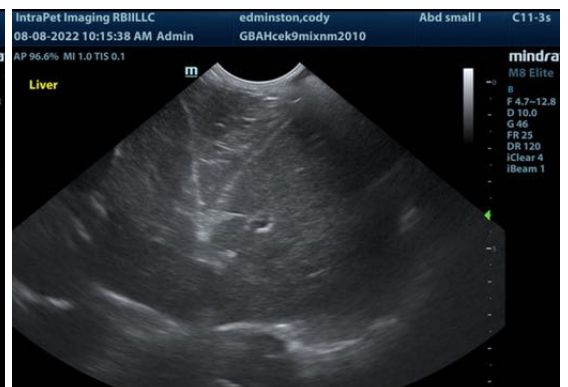
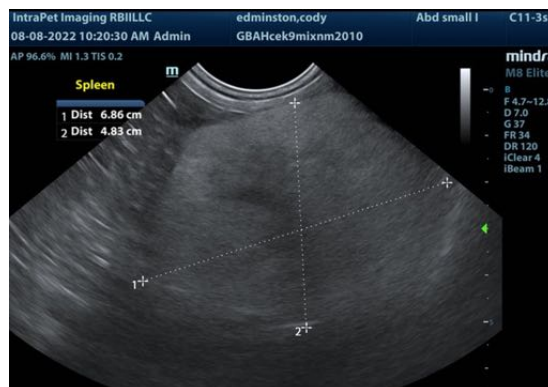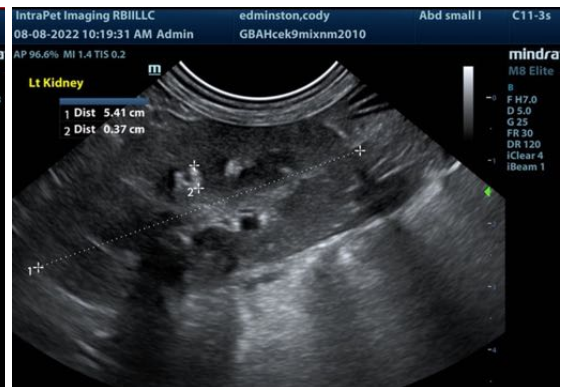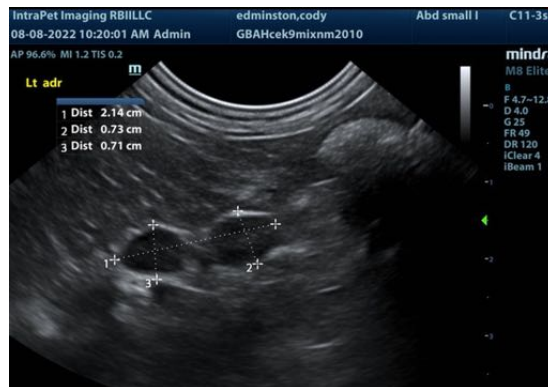
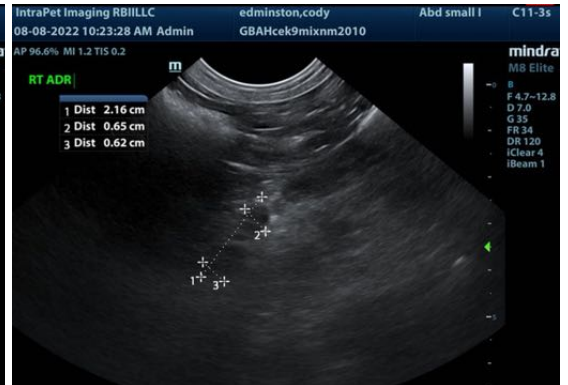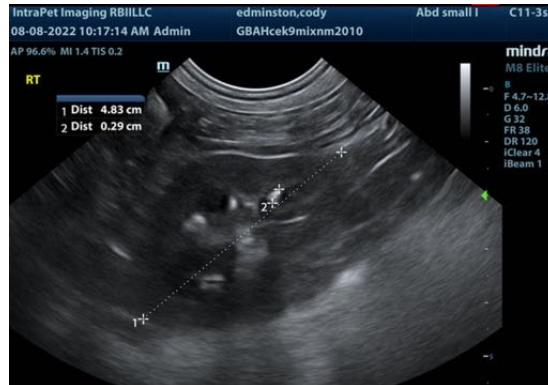### **ULTRASONOGRAPHIC FINDINGS**

Two separate splenic masses, appear isolated. Slightly swollen left adrenal gland.

### **INTERPRETATION OF THE FINDINGS & FURTHER RECOMMENDATIONS**

There was no obvious evidence of metastatic disease. Chest radiographs are warranted followed by exploratory splenectomy and liver biopsy to assess for micrometastasis. Round cell neoplasia and hemangiosarcoma are suspected. The two separate masses may be completely different as the more hyperechoic, attenuating mass may be connective tissue/stromal mass. The more aggressive mass appears to be the hypoechoic larger mass at the cranial pole. This is strongly suggestive for sarcoma.





The information and recommendations provided are based on the images presented by the referring veterinarian. No evaluation can be communicated regarding pathology that was not visible in the image/video clips provided.

Thank you for this referral. If the clinical or image interpretation does not parallel your findings or if I can be of any further assistance please contact me.

**Eric Lindquist**, DMV, DABVP, Cert. IVUSS, CEO of SonoPath.com  
 Eric.Lindquist@SonoPath.com