



PATIENT

Tribble Sanes

SPECIES

Feline

BREED

DSH

SEX

Neutered Male

AGE

12

WEIGHT

8.56

INTERPRETED BY

Eric Lindquist, DMV
DABVP, Cert. IVUSS

IMAGING PERFORMED BY

Melissa Pascucci

HOSPITAL NAME

American AH

REFERRING VET

Dr. Stockmal

INVOICE

23816

DATE

8/7/23

PRESENTING CLINICAL SIGNS

History: Weight loss despite adequate caloric intake. Stools formed but light in color. Today's stool was unformed.

Abnormal PE/Chem/CBC/UA Results: ALT 188 now (was 205 2 months ago), Urine (2 months ago)- pH 7.5, 2+ proteinuria, 1.060

ULTRASONOGRAPHIC EXAMINATION OF THE ABDOMEN

Urinary System

The **urinary bladder**, trigone, and pelvic urethra presented normal thicknesses and normal tone. The ureters were not visible which is normal. No uroliths or sediment were visualized and anechoic urine was present. No evidence of inflammatory or neoplastic changes were noted. Ureteral papillae were normal.

The **kidneys** revealed largely normal size and structure, corticomedullary definition and ratio (cortex 1/3 of medulla) were essentially maintained with some mild age-related loss of curvilinear patterns regarding the capsule and C/M junction. The cortices presented largely uniform texture with some increased echogenicity expected for his age patient. Medullary structure differed distinctly from that of the cortex and no evidence of pelvic dilation was present. The right kidney measured 5.78 cm.

Adrenal Glands

The regions of the **adrenal glands** revealed no evident pathology.

Spleen

The **spleen** presented a smooth homogeneous parenchyma hyperechoic to liver and renal cortical parenchyma. The capsule was smooth without noticeable expansion or deviation from within the spleen or adjacent pathology. The splenic vasculature demonstrated normal volume without signs of congestion or thrombosis. No sonographic evidence of acute or chronic inflammatory, neoplastic, or infarctual changes were noted.

Liver

The **hepatic** parenchyma was uniform with slight increased portal markings. The gallbladder was bifid, and mildly thickened.

Gastrointestinal

The **gastrointestinal tract** revealed minor variable thickening and echogenic submucosal changes most consistent with low grade end result of chronic GI disease such as IBD and may be related to malassimilation of nutrients if any weight loss is present. No obvious neoplastic patterns were noted and luminal content as unremarkable. Gastric wall thickness measured 6.0 mm.

Pancreas

The base and limbs of the **pancreas** were observed to be largely isoechoic to surrounding omental fat. Pancreatic duct and capsular contour were acceptably normal and parenchyma respected normal curvilinear patterns. No overt evidence of active inflammatory or neoplastic disease was noted.

ULTRASONOGRAPHIC FINDINGS



PATIENT

Tribble Sanes

- Minor cholangitis pattern with clinically insignificant bifid gallbladder, normal variant.
- Chronic GI changes
- Age-related renal changes

SPECIES

Feline

BREED

DSH

SEX

Neutered Male

AGE

12

WEIGHT

8.56

INTERPRETED BY

Eric Lindquist, DMV
DABVP, Cert. IVUSS

IMAGING PERFORMED BY

Melissa Pascucci

HOSPITAL NAME

American AH

REFERRING VET

Dr. Stockmal

INVOICE

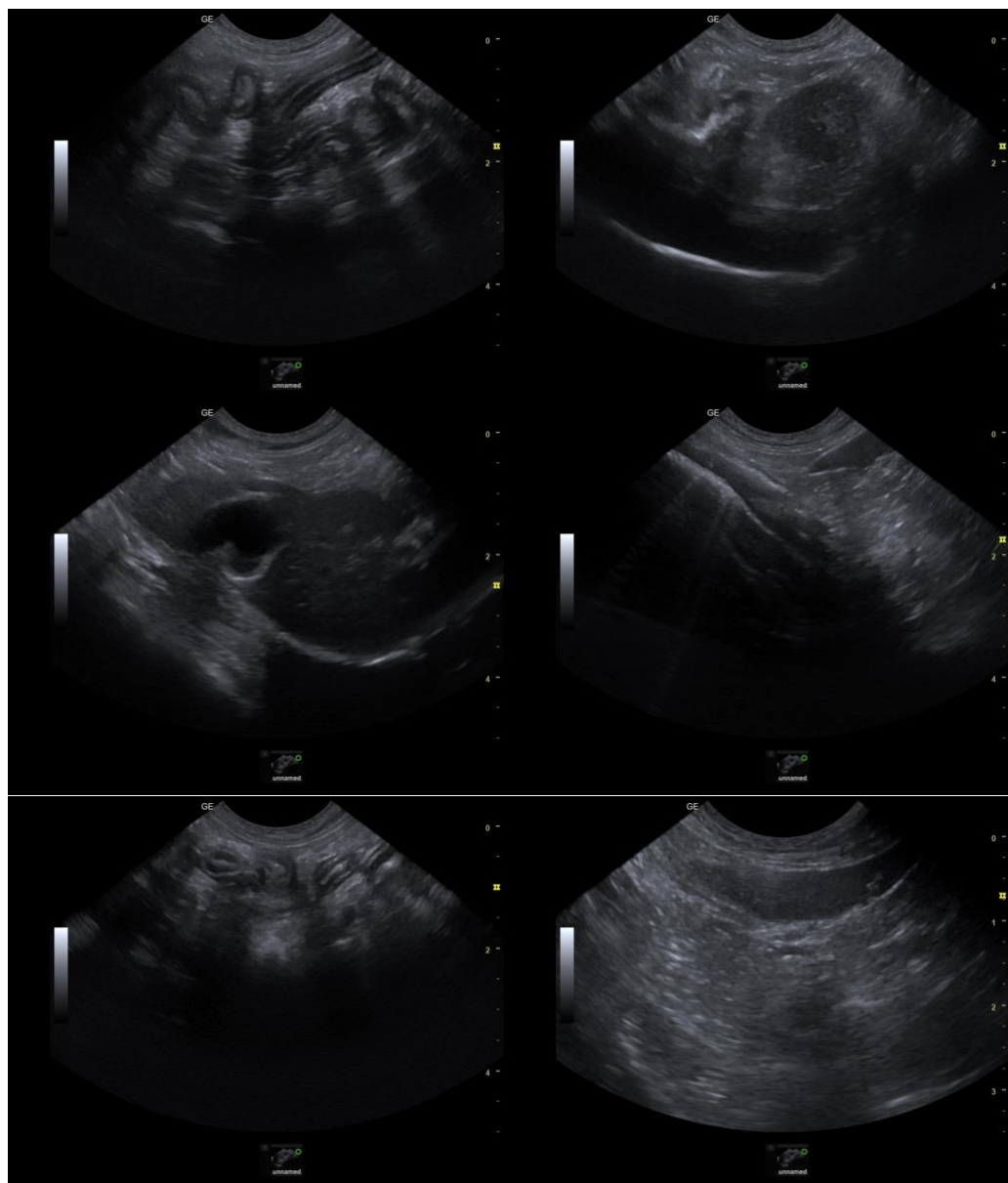
23816

DATE

8/7/23

INTERPRETATION OF THE FINDINGS & FURTHER RECOMMENDATIONS

Inflammatory bowel and reactive hepatopathy are likely. FNA of the liver could be considered for further definition. No overt neoplastic criteria with any organ system are met. Maldigestion panel, three view chest radiographs and full CNS examination is recommended to examine for occult disease that could be responsible for the weight loss. Evaluation for competitive eating environments should also be considered.





PATIENT

Tribble Sanes

SPECIES

Feline

BREED

DSH

SEX

Neutered Male

AGE

12

WEIGHT

8.56

INTERPRETED BY

Eric Lindquist, DMV
DABVP, Cert. IVUSS

**IMAGING
PERFORMED BY**

Melissa Pascucci

HOSPITAL NAME

American AH

REFERRING VET

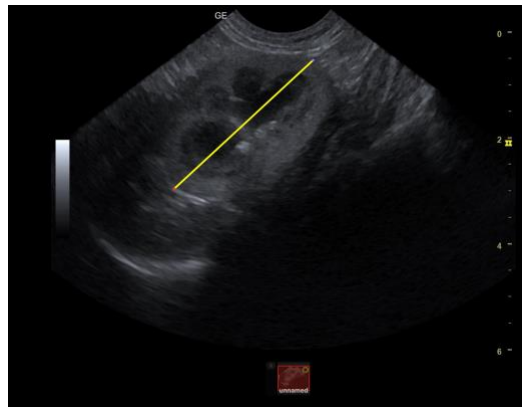
Dr. Stockmal

INVOICE

23816

DATE

8/7/23



The information and recommendations provided are based on the images presented by the referring veterinarian. No evaluation can be communicated regarding pathology that was not visible in the image/video clips provided.

Thank you for this referral. If the clinical or image interpretation does not parallel your findings or if I can be of any further assistance please contact me.

Eric Lindquist, DMV, DABVP, Cert. IVUSS, CEO of SonoPath.com
info@SonoPath.com