



PATIENT

Cooper Holmes

SPECIES

Canine

BREED

Golden Retriever

SEX

Neutered Male

AGE

8 Years

WEIGHT

97

INTERPRETED BY

Eric Lindquist, DMV
DABVP, Cert. IVUSS

**IMAGING
PERFORMED BY**

Brandon Holmes

HOSPITAL NAME

West Newton AC

REFERRING VET

Brandon Holmes

INVOICE

23817

DATE

8/7/23

PRESENTING CLINICAL SIGNS

Vomited all of his dinner last night and collapsed.

Abnormal PE/Chem/CBC/UA Results: Light pink MM, tacky, weak pulses. History of BNP = 1600 about 1 month ago. CBC showing neutrophilia of 25,000, glucose = 63, creatinine = 3.1, BUN = 33, D-dimer = 0.7.

ULTRASONOGRAPHIC EXAMINATION OF THE ABDOMEN

Urinary System

The **urinary bladder**, trigone, and pelvic urethra presented normal thicknesses and normal tone. The ureters were not visible which is normal. No uroliths or sediment were visualized and anechoic urine was present. No evidence of inflammatory or neoplastic changes were noted. Ureteral papillae were normal. The pelvic urethra was imaged 1.0 cm beyond the cystourethral junction.

The **kidneys** revealed normal size and structure, corticomedullary definition and ratio for this age. The cortices presented largely uniform texture with normal echogenic relationship to liver and spleen. Medullary structure differed distinctly from the cortex and no evidence of pelvic dilation was present. The capsules were acceptably uniform without significant irregularities. The left kidney measured 7.0 cm. The right kidney measured 7.0 cm.

Adrenal Glands

The regions of the **adrenal glands** were imaged and revealed no evident pathology.

Spleen

The **spleen** revealed subtle micronodular changes without significant disruption of architecture. Caudal and cranial folding of the spleen was noted.

Liver

Mild passive congestion **liver** pattern was noted with ascites. The gallbladder and common bile duct were unremarkable.

Gastrointestinal

Examination of the **gastrointestinal tract** revealed a stomach and intestine free of stasis, of normal wall thickness, acceptable curvilinear mural detail, and peristaltic activity. Small and large intestine demonstrated normal luminal chyme and stool consistency respectively. No obstructive or overt infiltrative disease was noted. No associated abnormal lymphatic activity was noted.

Pancreas

The base and limbs of the **pancreas** were observed to be largely isoechoic to surrounding omental fat. Pancreatic duct and capsular contour were acceptably normal and parenchyma respected normal curvilinear patterns. No overt evidence of active inflammatory or neoplastic disease was noted.

Free Abdomen

Slight **free fluid** was noted in the cranial abdomen.

Other



PATIENT

Cooper Holmes

SPECIES

Canine

BREED

Golden Retriever

SEX

Neutered Male

AGE

8 Years

WEIGHT

97

INTERPRETED BY

Eric Lindquist, DMV
DABVP, Cert. IVUSS

IMAGING PERFORMED BY

Brandon Holmes

HOSPITAL NAME

West Newton AC

REFERRING VET

Brandon Holmes

INVOICE

23817

DATE

8/7/23

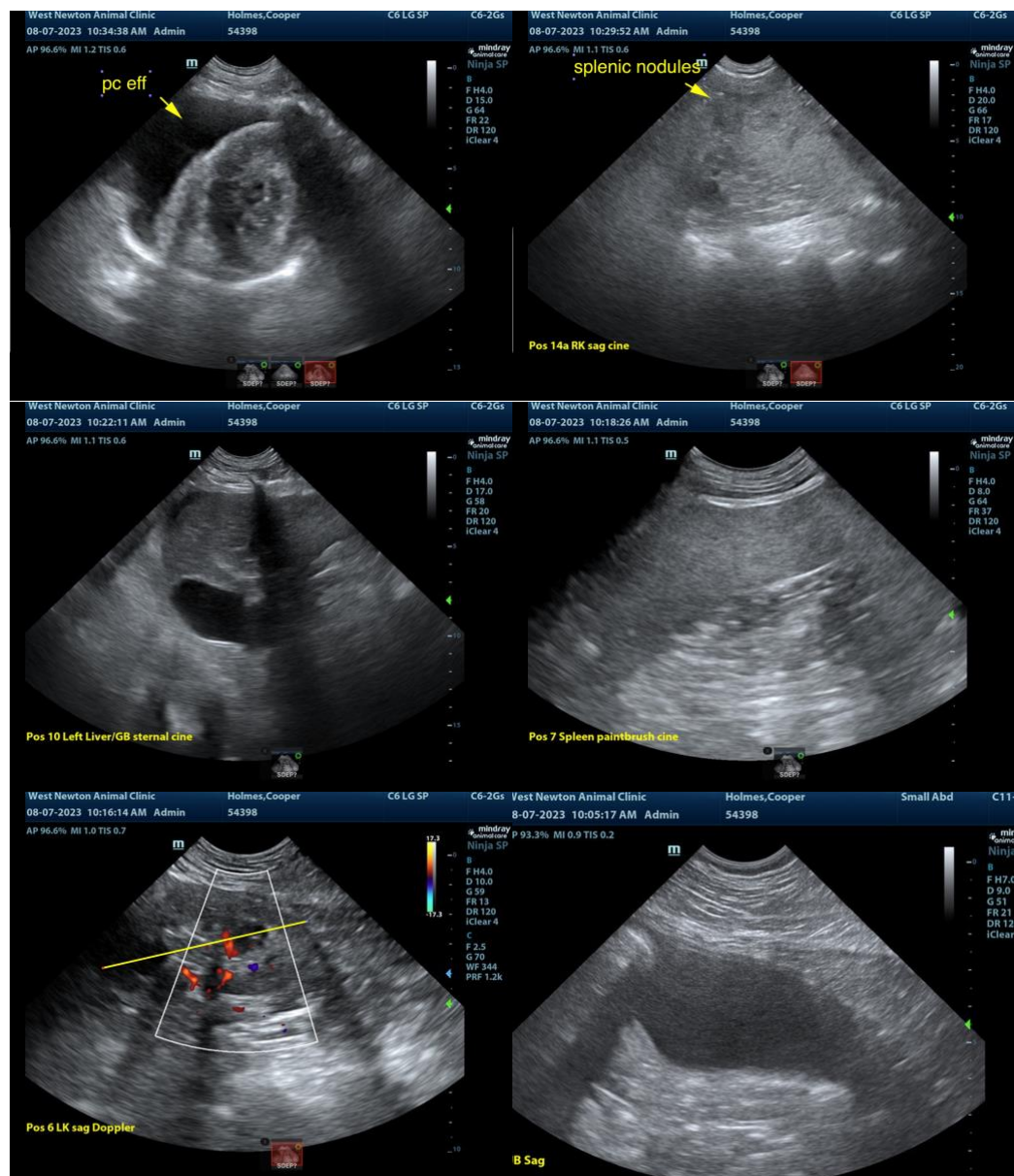
A rapid view of the **heart** revealed pericardial effusion, likely the cause of ascites in this patient. Pericardiocentesis, cytology and analysis and full evaluation of the right auricle is recommended.

ULTRASONOGRAPHIC FINDINGS

- Pericardial effusion with passive congestion liver pattern
- Micronodular spleen- hyperplasia vs emerging round cell neoplasia

INTERPRETATION OF THE FINDINGS & FURTHER RECOMMENDATIONS

Pericardial tap is warranted for further definition.



The information and recommendations provided are based on the images presented by the



PATIENT

Cooper Holmes

SPECIES

Canine

BREED

Golden Retriever

SEX

Neutered Male

AGE

8 Years

WEIGHT

97

INTERPRETED BY

Eric Lindquist, DMV
DABVP, Cert. IVUSS

**IMAGING
PERFORMED BY**

Brandon Holmes

HOSPITAL NAME

West Newton AC

REFERRING VET

Brandon Holmes

INVOICE

23817

DATE

8/7/23

referring veterinarian. No evaluation can be communicated regarding pathology that was not visible in the image/video clips provided.

Thank you for this referral. If the clinical or image interpretation does not parallel your findings or if I can be of any further assistance please contact me.

Eric Lindquist, DMV, DABVP, Cert. IVUSS, CEO of SonoPath.com

info@SonoPath.com