

PATIENT

Ghosty Pilichowska

SPECIES

Canine

BREED

Chihuahua Mix

SEX

Intact Female

AGE

1 Month 13 Days

WEIGHT

0.86 kg

INTERPRETED BY

Eric Lindquist, DMV,
 DABVP, Cert. IVUSS,
 CEO of
 SonoPath.com

IMAGING PERFORMED BY

Pamela Harrigan, RDCS

HOSPITAL NAME

Angell AMC

REFERRING VET

William Odom, DVM

INVOICE

16743

DATE

PRESENTING CLINICAL SIGNS

History: Adopted from McDonald's parking lot in Florida 5 days ago. Extremely lethargic, anemic, distended abdomen, suspected secondary to parasitism. R/O other GI issues. Cerenia, fluids, unasyn, dewormer, blood transfusion overnight.

ULTRASONOGRAPHIC EXAMINATION OF THE ABDOMEN

Urinary System

The **urinary bladder**, trigone, and pelvic urethra presented normal thicknesses and normal tone. The ureters were not visible which is normal. No uroliths or sediment were visualized, and anechoic urine was present. No evidence of inflammatory or neoplastic changes were noted. Ureteral papillae were normal.

The **kidneys** revealed normal size and structure, corticomedullary definition and ratio for this age. The cortices presented largely uniform texture with normal echogenic relationship to liver and spleen. Medullary structure differed distinctly from the cortex and no evidence of pelvic dilation was present. The capsules were acceptably uniform without significant irregularities. The right kidney measured 2.5 cm. The left kidney measured 2.5 cm.

Adrenal Glands

The **adrenal glands** were not visualized.

Spleen

The **spleen** in this patient was uniform, yet volume contracted. Hydration status should be assessed.

Liver

The **liver** images submitted revealed subjectively normal liver size, contour, and structure. Parenchymal echogenicity was naturally coarse and hypoechoic to the spleen. Vascular and biliary tracts were of normal volume with no evidence of congestion. The gallbladder presented acceptably thin walls with primarily anechoic content. The cystic and common bile ducts were normal. No pathological hepatic lymphadenopathy was evident. No overt structural evidence of inflammatory, infiltrative or regenerative pathology was evident.

Gastrointestinal

The **stomach** was filled with anechoic fluid stasis. The small intestine presented dilated lumen and hyperperistalsis.

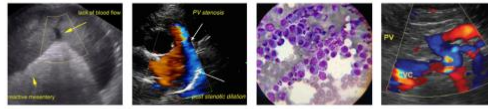
Pancreas

The base and limbs of the **pancreas** were observed to be largely isoechoic to surrounding omental fat. Pancreatic duct and capsular contour were acceptably normal and parenchyma respected normal curvilinear patterns. No overt evidence of active inflammatory or neoplastic disease was noted.

ULTRASONOGRAPHIC FINDINGS

- Nonspecific gastroenteritis
- Volume contracted spleen

INTERPRETATION OF THE FINDINGS & FURTHER RECOMMENDATIONS



PATIENT

Ghosty Pilichowska

SPECIES

Canine

BREED

Chihuahua Mix

SEX

Intact Female

AGE

1 Month 13 Days

WEIGHT

0.86 kg

INTERPRETED BY

Eric Lindquist, DMV,
 DABVP, Cert. IVUSS,
 CEO of
 SonoPath.com

**IMAGING
 PERFORMED BY**

Pamela Harrigan, RDCS

HOSPITAL NAME

Angell AMC

REFERRING VET

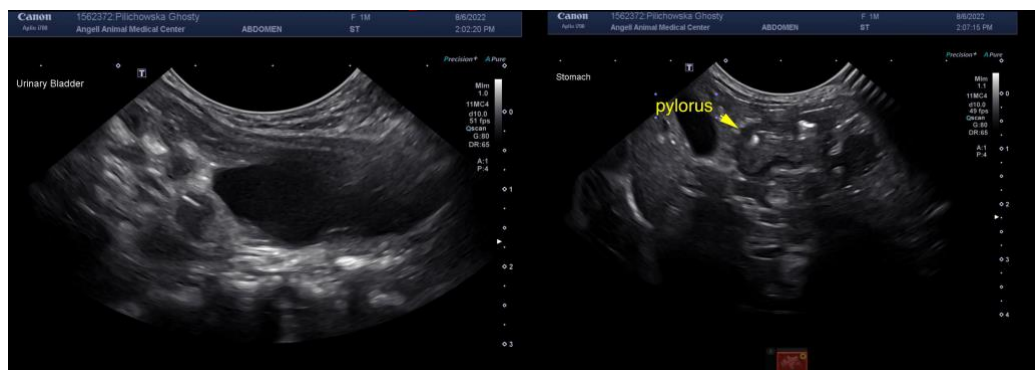
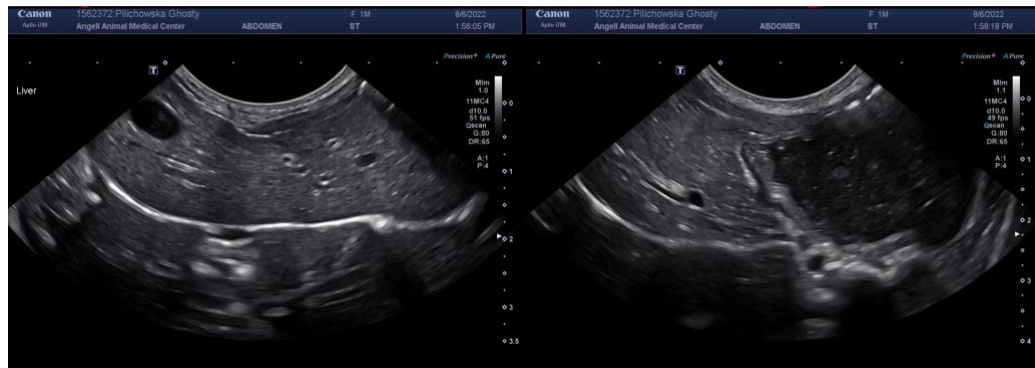
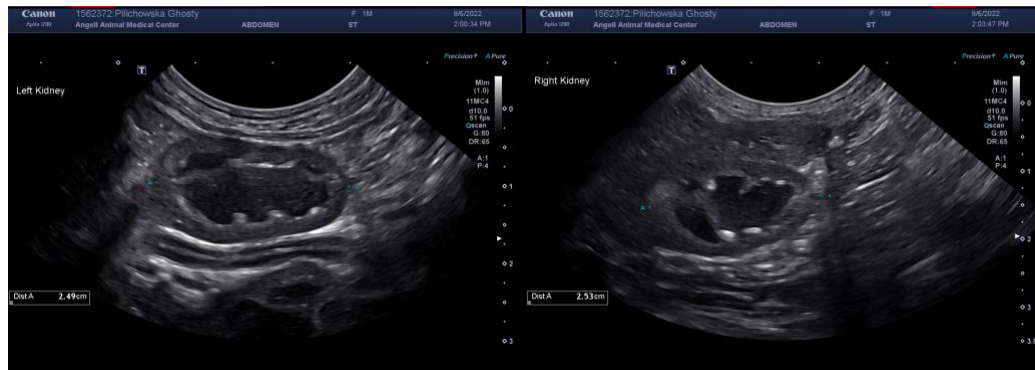
William Odom, DVM

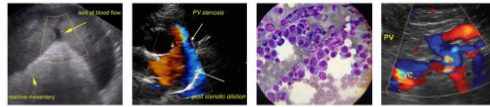
INVOICE

16743

DATE

Parasitism is a strong potential in this patient. I recommend a fresh fecal smear and fecal floatation analysis. Broad spectrum antiparasitic protocol warranted. Screening for occult Addisons is indicated with baseline cortisol or ACTH stimulation. Supportive care should prove effective. The anemia is likely from parasitism, however, GI hemorrhage and/or underlying Addisons may be also playing a role. No overt evidence of ulcerative disease.





PATIENT

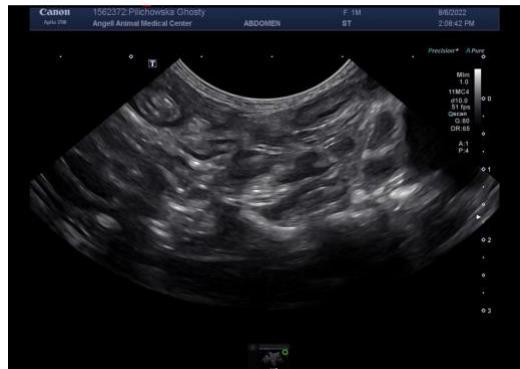Ghosty Pilichowska

SPECIES

Canine

BREED

Chihuahua Mix



SEX

Intact Female

The information and recommendations provided are based on the images presented by the referring veterinarian. No evaluation can be communicated regarding pathology that was not visible in the image/video clips provided.

AGE

1 Month 13 Days

Thank you for this referral. If the clinical or image interpretation does not parallel your findings or if I can be of any further assistance please contact me.

Eric Lindquist, DMV, DABVP, Cert. IVUSS, CEO of SonoPath.com

WEIGHT

0.86 kg

info@SonoPath.com

INTERPRETED BY

Eric Lindquist, DMV,
DABVP, Cert. IVUSS,
CEO of
SonoPath.com

IMAGING PERFORMED BY

Pamela Harrigan, RDCS

HOSPITAL NAME

Angell AMC

REFERRING VET

William Odom, DVM

INVOICE

16743

DATE