


PATIENT PRESENTING CLINICAL SIGNS

AJ Bushinski History: Pleural Edema/ raised trachea - 1/6 systolic - intermittent arrhythmia Current meds - Lasix 12.5mg - 1/2 Tab PO BID, Cyclosporin 2%

SPECIES Abnormal PE/Chem/CBC/UA Results: CBC- EOS (LO) - 0.051, PLATELETS 9625, CHEM TP (HI) 7.6 - GLOB - 4.5(HI) U/A - PLUERAL EDEMA, RAISED TRACHEA, INCREASED RIGHT VENRICLE W/ CARDIOMEGALY, GAS IN COLON

Canine

BREED ULTRASONOGRAPHIC EXAMINATION OF THE HEART

Yorkie

SEX

Neutered Male

AGE

14 Years

WEIGHT

11.4

INTERPRETED BY

 Eric Lindquist, DMV
 DABVP, Cert. IVUSS

IMAGING PERFORMED BY

Carla

HOSPITAL NAME

 Animal Care Clinic of
 Flanders

REFERRING VET

Dr. Villari

INVOICE

23793

DATE

8/5/23

CANINE CARDIAC PARAMETERS	MR VMAX (m/s)	TR VMAX (m/s)	LA/AO (Boon method)	LA/AO (Heart Base; Swe)	FS (%)	EF (%)	EPSS (cm)
NORMAL PARAMETER	4.5-5.5	<2.7	1.3	<1.6	28-40	40-100	<0.6
PATIENT	--	2.0	1.0	1.0	30	--	0.1
CANINE CARDIAC PARAMETERS	HR (BPM)	AV VMAX (m/s)	PV MAX (m/s)	BODY WEIGHT (kg)	LA 2D short axis Base view (cm)	LVIDd Avg; 2D and m-mode short axis (cm)	LVIDs Avg; 2D and m-mode short axis (cm)
NORMAL PARAMETER	50-100	0.7-1.7	0.7-1.6				
PATIENT	--	--	--	--	1.7	1.33	--

Cardiac Presentation

The cardiac presentation in this patient revealed mild to moderate right sided cardiac enlargement with volume contracted left heart. Contractility was mildly subnormal. Mitral insufficiency was present yet minor and compensated. No evidence of left sided cardiac failure in this patient, however, the right side is enlarged, likely owing to increased respiratory pressures. No pleural or pericardial effusion was noted. The hepatic veins were not dilated. No evidence of right sided failure. Tricuspid insufficiency was noted (2.0 m/s), yet minor and septally directed.

ULTRASONOGRAPHIC FINDINGS

- Cor Pulmonale
- Mitral and tricuspid insufficiency

INTERPRETATION OF THE FINDINGS & FURTHER RECOMMENDATIONS

I recommend primary respiratory protocol in this patient. Lasix should be diminished gradually, as there is no left sided cardiac disease.



PATIENT

AJ Bushinski

SPECIES

Canine

BREED

Yorkie

SEX

Neutered Male

AGE

14 Years

WEIGHT

11.4

INTERPRETED BY

Eric Lindquist, DMV
DABVP, Cert. IVUSS

IMAGING PERFORMED BY

Carla

HOSPITAL NAME

Animal Care Clinic of
Flanders

REFERRING VET

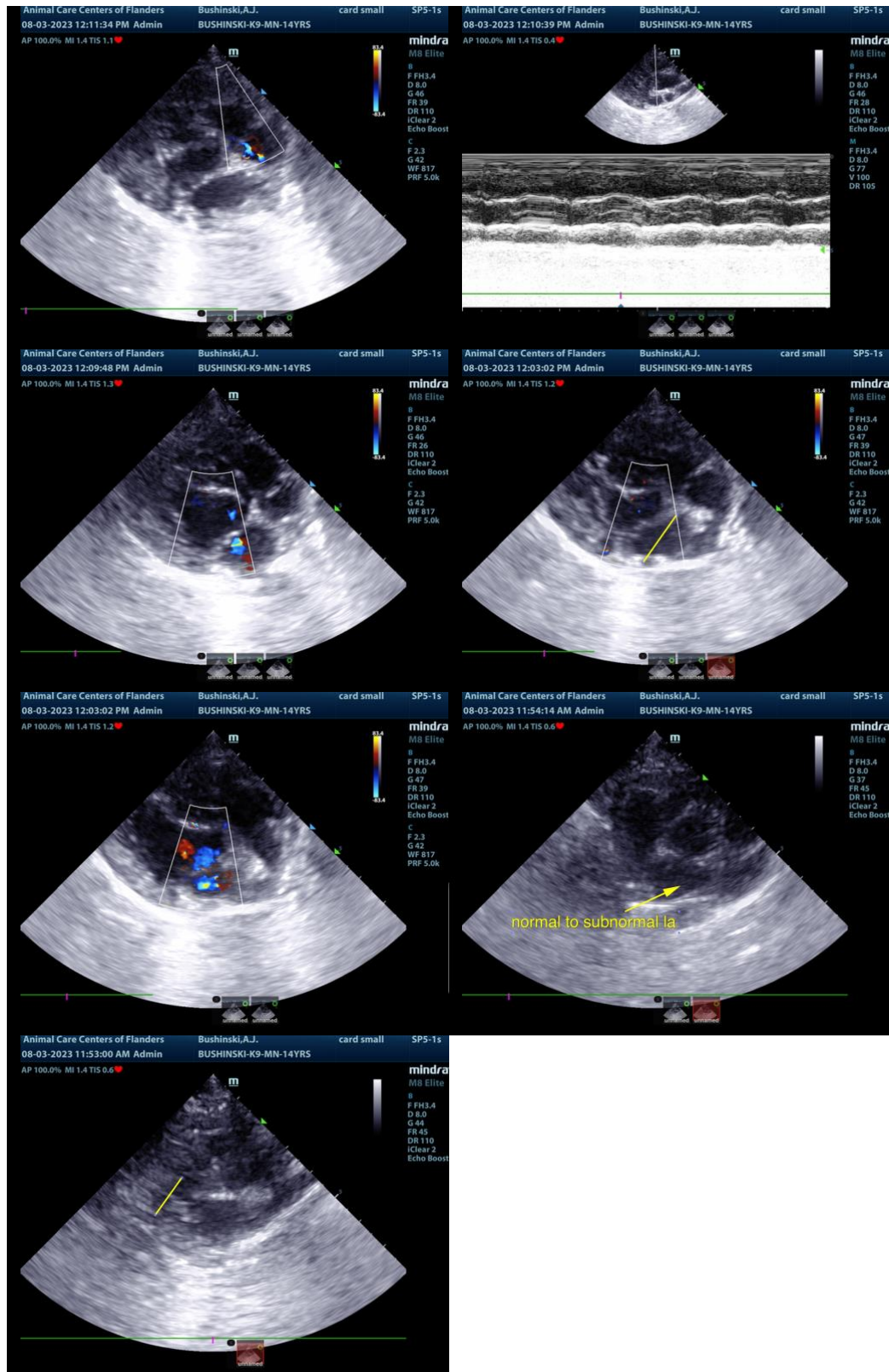
Dr. Villari

INVOICE

23793

DATE

8/5/23





PATIENT

AJ Bushinski

The information and recommendations provided are based on the images presented by the referring veterinarian. No evaluation can be communicated regarding pathology that was not visible in the image/video clips provided.

SPECIES

Canine

Thank you for this referral. If the clinical or image interpretation does not parallel your findings or if I can be of any further assistance please contact me.

BREED

Yorkie

Eric Lindquist, DMV, DABVP, Cert. IVUSS, CEO of SonoPath.com
info@SonoPath.com

SEX

Neutered Male

AGE

14 Years

WEIGHT

11.4

INTERPRETED BY

Eric Lindquist, DMV
DABVP, Cert. IVUSS

IMAGING PERFORMED BY

Carla

HOSPITAL NAME

Animal Care Clinic of
Flanders

REFERRING VET

Dr. Villari

INVOICE

23793

DATE

8/5/23