



**PATIENT**

Taylor Batula

**SPECIES**

Canine

**BREED**

German Shepherd

**SEX**

Spayed Female

**AGE**

2 Years 8 Months

**WEIGHT**

36.2 kg

**INTERPRETED BY**

Eric Lindquist, DMV  
DABVP, Cert. IVUSS

**IMAGING PERFORMED BY**

Dallas Reynolds, LVT

**HOSPITAL NAME**

Lone Mtn. AH

**REFERRING VET**

Dr. Munoz

**INVOICE**

16739

**DATE**

8/5/22

**PRESENTING CLINICAL SIGNS**

History: Presents for evaluation of lethargy, hyporexia, and feeling warm. Last time p presented similar clinical signs she was diagnosed with erlichia and treated for it. O hasn't gone out of the house in a long time, no hiking.

Abnormal PE/Chem/CBC/UA Results: T - 105.3, temperature has been fluctuating while hosp's with fluids between 103-105 cbc - WBC 18.58, NEU 15.44, RBC 8.73, HCT 57.47, PLT 155 chem - nsf Accuplex 4 - Neg for lyme, erlichia, anaplasma, heartworm UA: USG 1.046, protein 2+ Rocky Mountain Spotted fever - pending Urine culture - pending Radiographs: Findings: 6 radiographic images dated 8/4/22 are available for review. The cardiac silhouette appears to be of normal size and shape. If anything pulmonary vasculature appears decreased in size. No soft-tissue interstitial infiltrates or nodules are identified. Osseous structures included with the thoracic cavity appear normal. The stomach is mildly distended with gas. There is fecal material within descending colon. No radiopaque foreign material is noted within the small intestinal track detail the central abdomen appears slightly hazy on lateral view. Urinary bladder is minimally distended. Spleen is position caudal to the stomach resulting in increased opacity of the perigastric region on lateral image. Liver is of normal size and shape. Kidneys are of normal size and shape. Assessment: Subjectively pulmonary vasculature appears decreased in size. Radiographic appearance could indicate reduced cardiac return secondary to dehydration. The gastrointestinal track appears relatively empty. Hazy appearance to central abdominal detail could be secondary to positioning of the spleen within central abdominal cavity. If patient has focal abdominal pain possibility of emerging peritonitis due to pancreatitis cannot be excluded. At this time consider medical management and possible fluid therapy with monitoring for clinical improvement. Follow-up images are recommended if patient develops progressive abdominal pain or continues to vomit.

**ULTRASONOGRAPHIC EXAMINATION OF THE ABDOMEN**

**Urinary System**

The **urinary bladder**, trigone, and pelvic urethra presented normal thicknesses and normal tone. The ureters were not visible which is normal. No uroliths or sediment were visualized and anechoic urine was present. No evidence of inflammatory or neoplastic changes were noted. Ureteral papillae were normal.

The **kidneys** revealed normal size and structure, corticomedullary definition and ratio for this age. The cortices presented largely uniform texture with normal echogenic relationship to liver and spleen. Medullary structure differed distinctly from the cortex and no evidence of pelvic dilation was present. The capsules were acceptably uniform without significant irregularities. Both kidneys measured 7.0 cm.

**Adrenal Glands**

The **adrenal glands** were not visualized.

**Spleen**

The **spleen** presented a smooth homogeneous parenchyma hyperechoic to liver and renal cortical parenchyma. The capsule was smooth without noticeable expansion or deviation from within the spleen or adjacent pathology. The splenic vasculature demonstrated normal volume without signs of congestion or thrombosis. No sonographic evidence of acute or chronic inflammatory, neoplastic, or infarctual changes were noted. Caudal folding of the spleen was noted.



**PATIENT**

**Liver**

Taylor Batula

The **liver** images submitted revealed subjectively normal liver size, contour, and structure. Parenchymal echogenicity was naturally coarse and hypoechoic to the spleen. Vascular and biliary tracts were of normal volume with no evidence of congestion. The gallbladder presented acceptably thin walls with primarily anechoic content. The cystic and common bile ducts were normal. No pathological hepatic lymphadenopathy was evident. No overt structural evidence of inflammatory, infiltrative or regenerative pathology was evident.

**SPECIES**

Canine

**BREED**

**Gastrointestinal**

German Shepherd

Examination of the **gastrointestinal tract** revealed a stomach and intestine free of stasis, of normal wall thickness, acceptable curvilinear mural detail, and peristaltic activity. Small and large intestine demonstrated normal luminal chyme and stool consistency respectively. No obstructive or overt infiltrative disease was noted. No associated abnormal lymphatic activity was noted.

**SEX**

Spayed Female

**Pancreas**

**AGE**

2 Years 8 Months

The base and limbs of the **pancreas** were observed to be largely isoechoic to surrounding omental fat. Pancreatic duct and capsular contour were acceptably normal and parenchyma respected normal curvilinear patterns. No overt evidence of active inflammatory or neoplastic disease was noted.

**ULTRASONOGRAPHIC FINDINGS**

**WEIGHT**

36.2 kg

- Structurally unremarkable abdomen
- No evidence of visceral pathology.

**INTERPRETATION OF THE FINDINGS & FURTHER RECOMMENDATIONS**

**INTERPRETED BY**

Eric Lindquist, DMV  
DABVP, Cert. IVUSS

Systemic infection suspected. Doxycycline/clindamycin combination could be considered, subjectively, to cover for a majority of infectious agents.

**IMAGING PERFORMED BY**

Dallas Reynolds, LVT

**HOSPITAL NAME**

Lone Mtn. AH

**REFERRING VET**

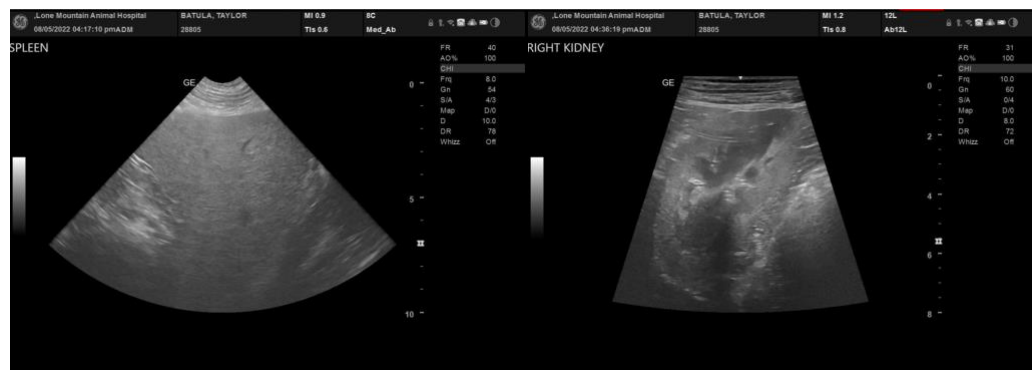
Dr. Munoz

**INVOICE**

16739

**DATE**

8/5/22





**PATIENT**

Taylor Batula

**SPECIES**

Canine

**BREED**

German Shepherd

**SEX**

Spayed Female

**AGE**

2 Years 8 Months

**WEIGHT**

36.2 kg

**INTERPRETED BY**

Eric Lindquist, DMV  
DABVP, Cert. IVUSS

**IMAGING PERFORMED BY**

Dallas Reynolds, LVT

**HOSPITAL NAME**

Lone Mtn. AH

**REFERRING VET**

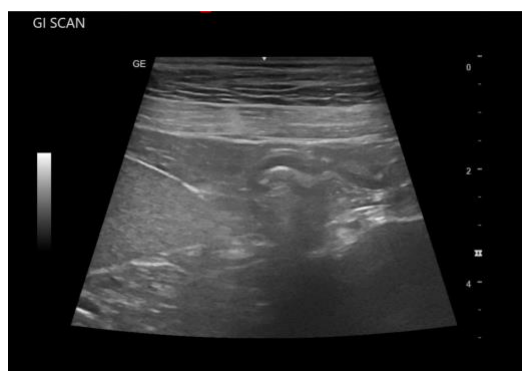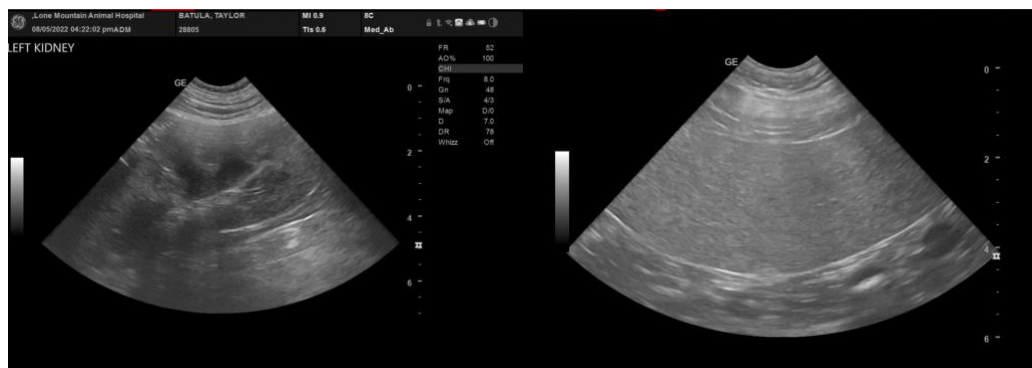
Dr. Munoz

**INVOICE**

16739

**DATE**

8/5/22



The information and recommendations provided are based on the images presented by the referring veterinarian. No evaluation can be communicated regarding pathology that was not visible in the image/video clips provided.

Thank you for this referral. If the clinical or image interpretation does not parallel your findings or if I can be of any further assistance please contact me.

**Eric Lindquist**, DMV, DABVP, Cert. IVUSS, CEO of SonoPath.com  
info@SonoPath.com

**Fever of Unknown Origin**

<http://www.sonopath.com/FUO>

**Description:** The definition of a fever of unknown origin (FUO) has not been clearly defined for animals. Currently, it is either understood to be a fever that does not resolve within the period one would expect for a “self-limiting infection” being treated with appropriate antimicrobial therapy, or that for which an underlying diagnosis has not been determined despite considerable diagnostic effort. The common causes of FUO were summarized concisely in a presentation at the American



**PATIENT**

Taylor Batula

College of Veterinary Internal Medicine 2004 Forum. The presenters synthesized information from three veterinary papers on the subject, which suggested the following:

**SPECIES**

Canine

**BREED**

German Shepherd

**SEX**

Spayed Female

**AGE**

2 Years 8 Months

**WEIGHT**

36.2 kg

Final Diagnosis	Bennett (dogs & cats)	Dunn and Dunn (dogs only)	Lunn (dogs & one cat)	Total
Infection	21	16	10	47
Immune	18	22	6	46
Bone marrow disease	4	22	2	28
Neoplasia (outside marrow)	0	10	2	12
Miscellaneous	2	12	2	16
No diagnosis	0	19	2	21
<b>TOTALS</b>	<b>45</b>	<b>101</b>	<b>24</b>	<b>170</b>

**INTERPRETED BY**

Eric Lindquist, DMV  
DABVP, Cert. IVUSS

**IMAGING PERFORMED BY**

Dallas Reynolds, LVT

**HOSPITAL NAME**

Lone Mtn. AH

**REFERRING VET**

Dr. Munoz

**INVOICE**

16739

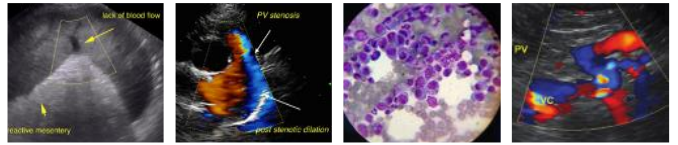
**DATE**

8/5/22

The types of infection diagnosed in this case series were varied, ranging from discospondylitis (8 cases), blastomycosis (6), and bacterial endocarditis (4), to leishmaniasis (1), prostatitis (1), and *Ehrlichia canis* infection (1); a multitude of other infectious causes also fell within the spectrum. Of the cases in which immune-mediated disease was found, 44% had immune-mediated polyarthritis. Bone marrow diseases included myeloproliferative disease, myelodysplasia (8), lymphocytic leukemia (8), myeloma (3), chronic granulocytic leukemia (3), lymphoblastic leukemia, and malignant histiocytosis. The types of neoplasia located outside the bone marrow included lymphoma (6), metastatic disease (2), and neoplasms of the lung, spleen, and stomach. Finally, miscellaneous diseases included hypertrophic osteodystrophy (6), meningitis (3), portosystemic shunt (3), lymphadenitis (2), panosteitis, and intervertebral disc disease. Overall, the most common causes across all cases were polyarthritis (44), lymphoid neoplasia (15), discospondylitis (8), myelodysplasia (8), hypertrophic osteodystrophy (6), and blastomycosis (6).

**Clinical Signs:** Animals usually present with either persistent or waxing and waning fevers ranging from 103°F to 106°F. Other clinical signs depend on the underlying cause of the fever. Careful and thorough physical examination is required to assess potential causes.

**Diagnostics:** FOU etiologies are partly related to geography, and thus locale or travel history should factor into a practitioner's diagnostic approach. A patient's lifestyle may also provide clues regarding exposure to certain etiologic agents. Therefore, conducting a thorough history can unveil important pieces of the diagnostic puzzle. Physical examination is especially important and should include an inspection of all accessible lymph nodes, palpation and movement of the joints, a fundic



**PATIENT**

Taylor Batula

examination, a neurological evaluation, spinal and limb palpation and range of motion tests, and a rectal examination.

**SPECIES**

Canine

A minimum database should include a CBC reviewed by a clinical pathologist, as well as a biochemical profile and urinalysis. Retroviral testing should also be considered in cats. In areas where tick-borne disease is prevalent, in-house testing should be performed early. Advanced laboratory work can include: urine culture, blood culture, and infectious disease panels (PCR and/or serology). In dogs, one may screen for the following infectious agents: *Ehrlichia* spp., *Borrelia burgdorferi*, Rock Mountain Spotted Fever, *Bartonella* spp. (culture and PCR), and *Leptospira* spp. in cases of hepatic or renal involvement. In cats, one should evaluate for FeLV, FIV, feline infectious peritonitis (FIP) virus, toxoplasmosis, *Hemoplasma* spp. (*Mycoplasma*), and *Bartonella* spp. (culture and PCR). Testing for *Ehrlichia* spp., *Rickettsia* spp., and *Anaplasma phagocytophilum* can also be considered. A fungal assay is indicated if the patient lives in or has had exposure to a region with a higher incidence of fungal disease. Other infectious disease tests may be performed depending on the geographical location of the pet. Screening for *Brucella* should be done in breeding dogs. Immune-mediated disease screening can include a Coomb's test, a slide agglutination test (if the patient is anemic), and an antinuclear antibody (ANA) test. Immune disease is often a diagnosis of exclusion.

**BREED**

German Shepherd

**SEX**

Spayed Female

**AGE**

2 Years 8 Months

**WEIGHT**

36.2 kg

Imaging should include thoracic radiographs, abdominal ultrasound, and/or abdominal radiographs. Ultrasound can be very useful for assessing evidence of cholangiohepatitis, pyelonephritis, chronic urinary tract infection, abscess formation, peritonitis, and neoplasia; it also permits an examination of the intra-abdominal lymph nodes. An echocardiogram can offer assessment for vegetative endocarditis, whereas spinal radiographs offer assessment for discospondylitis. In cases where all other testing has proven negative and the patient has not responded to broad-spectrum antibiotics and supportive care, arthrocentesis should be considered to evaluate for septic joint disease, immune-mediated polyarthritis, and infectious disease. Finally, one can consider assessing the cerebrospinal fluid for meningoencephalitis, GME, and meningitis/arteritis. A bone marrow exam should be performed if blood dyscrasias are noted on the CBC.

**INTERPRETED BY**

Eric Lindquist, DMV  
DABVP, Cert. IVUSS

**IMAGING PERFORMED BY**

Dallas Reynolds, LVT

**HOSPITAL NAME**

Lone Mtn. AH

**Treatment:** Treatment of the fever depends entirely on the underlying cause. Ideally, a thorough diagnostic plan will yield a diagnosis that will guide the appropriate therapeutic course. However, if an exhaustive approach has not produced a definitive diagnosis and there is no response to broad-spectrum antibiotics, trial therapy with immunosuppressive agents such as prednisolone can be considered to treat presumed immune-mediated diseases. Given the potential for negative sequelae should an underlying infection be present, one must be certain that the investigation is thorough and monitor the patient's response carefully.

**REFERRING VET**

Dr. Munoz

**Conclusion:** If a documented fever has not responded to antibiotics, antipyretics, or general nursing care, it is important to obtain a diagnosis to guide more specific treatment. A systematic physical examination and thorough history-taking will help inform further diagnostics in addition to what is revealed by the minimum database.

**INVOICE**

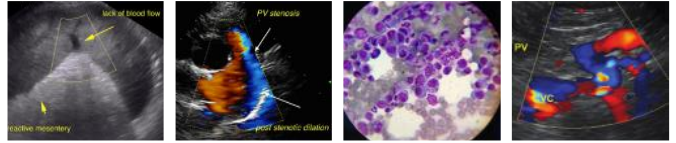
16739

**References:**

**DATE**

8/5/22

Bennet D. Diagnosis of pyrexia of unknown origin. *In Practice* 1995;17(10):470-81.



**PATIENT**

Taylor Batula

Dunn KJ, Dunn JK. Diagnostic investigations in 101 dogs with pyrexia of unknown origin. *J Sm Anim Pract* 1998;39(12):574-80.

**SPECIES**

Canine

Flood J. The diagnostic approach to fever of unknown origin in cats. *Compend Contin Educ Vet* 2009;31(1):26-31.

**BREED**

German Shepherd

Flood J. The diagnostic approach to fever of unknown origin in dogs. *Compend Contin Educ Vet* 2009;31(1):14-21.

**SEX**

Spayed Female

Lappin MR. The role of blood borne pathogens in feline fever of unknown origin. Proceedings from the American College of Veterinary Internal Medicine, Denver, CO, June 15-18, 2011.

**AGE**

2 Years 8 Months

Lunn KF. Fever of unknown origin: a systematic approach to diagnosis. *Compend Contin Educ Vet* 2001;23(11):976-92.

Lunn KF. Fever of unknown origin: appropriate choice of diagnostic tests. Proceedings from the American College of Veterinary Internal Medicine, Minneapolis, MN, June 9-12, 2004.

**WEIGHT**

36.2 kg

**INTERPRETED BY**

Eric Lindquist, DMV  
DABVP, Cert. IVUSS

**IMAGING PERFORMED BY**

Dallas Reynolds, LVT

**HOSPITAL NAME**

Lone Mtn. AH

**REFERRING VET**

Dr. Munoz

**INVOICE**

16739

**DATE**

8/5/22