



**PATIENT**

Sophie Romero

**PRESENTING CLINICAL SIGNS**

Poor appetite, fever, No improvement on medications  
Abnormal PE/Chem/CBC/UA Results: 104.0 fever, blood normal,

**SPECIES**

Feline

**ULTRASONOGRAPHIC EXAMINATION OF THE ABDOMEN**

**Urinary System**

**BREED**

DSH

The **urinary bladder**, trigone, and pelvic urethra presented normal thicknesses and normal tone. The ureters were not visible which is normal. No uroliths or sediment were visualized and anechoic urine was present. No evidence of inflammatory or neoplastic changes were noted. Ureteral papillae were normal.

**SEX**

Spayed Female

The **kidneys** revealed largely normal size and structure, corticomedullary definition and ratio (cortex 1/3 of medulla) were essentially maintained with some age-related loss of curvilinear patterns regarding the capsule and C/M junction. The cortices presented largely uniform texture with some increased echogenicity expected for his age patient. Medullary structure differed distinctly from that of the cortex and no evidence of pelvic dilation was present. The left kidney measured 3.8 cm. The right kidney measured 4.08 cm.

**AGE**

10 Years

**Adrenal Glands**

**WEIGHT**

12.8 Pounds

The regions of the **adrenal glands** were unremarkable.

**Spleen**

**INTERPRETED BY**

Eric Lindquist, DMV

DABVP, Cert. IVUSS

The **spleen** presented a smooth homogeneous parenchyma hyperechoic to liver and renal cortical parenchyma. The capsule was smooth without noticeable expansion or deviation from within the spleen or adjacent pathology. The splenic vasculature demonstrated normal volume without signs of congestion or thrombosis. No sonographic evidence of acute or chronic inflammatory, neoplastic, or infarctual changes were noted.

**Liver**

**IMAGING PERFORMED BY**

JK

The **liver** images submitted revealed subjectively normal liver size, contour, and structure. Parenchymal echogenicity was naturally coarse and hypoechoic to the spleen. Vascular and biliary tracts were of normal volume with no evidence of congestion. The gallbladder presented acceptably thin walls with primarily anechoic content. The cystic and common bile ducts were normal. No pathological hepatic lymphadenopathy was evident. No overt structural evidence of inflammatory, infiltrative or regenerative pathology was evident.

**HOSPITAL NAME**

Hamburg Vet Clinic

**Gastrointestinal**

**REFERRING VET**

Dr. Bingaman

A gastric fundic mass was noted, measuring approximately 4.0 cm, impinging upon the diaphragm and liver dorsally. The small intestine and colon were unremarkable.

**Pancreas**

**INVOICE**

40234

The base and limbs of the **pancreas** were observed to be largely isoechoic to surrounding omental fat. Pancreatic duct and capsular contour were acceptably normal and parenchyma respected normal curvilinear patterns. No overt evidence of active inflammatory or neoplastic disease was noted.

**ULTRASONOGRAPHIC FINDINGS**

**DATE**

8/5/22

- Gastric mass – strongly consistent with lymphoma, less likely granulomatous disease.
- Age related abdominal changes elsewhere, no evidence of metastatic disease.



**PATIENT**

Sophie Romero

**INTERPRETATION OF THE FINDINGS & FURTHER RECOMMENDATIONS**

FNA of the mass warranted for further definition.

**SPECIES**

Feline

**BREED**

DSH

**SEX**

Spayed Female

**AGE**

10 Years

**WEIGHT**

12.8 Pounds

**INTERPRETED BY**

Eric Lindquist, DMV

DABVP, Cert. IVUSS

**IMAGING PERFORMED BY**

JK

**HOSPITAL NAME**

Hamburg Vet Clinic

**REFERRING VET**

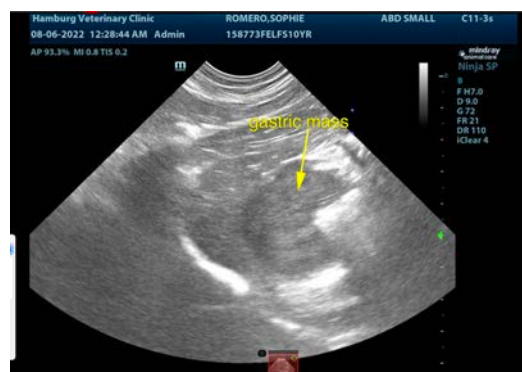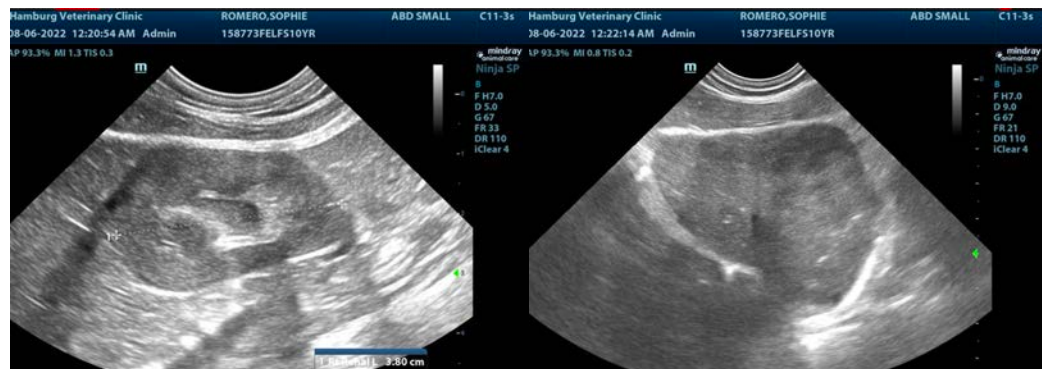
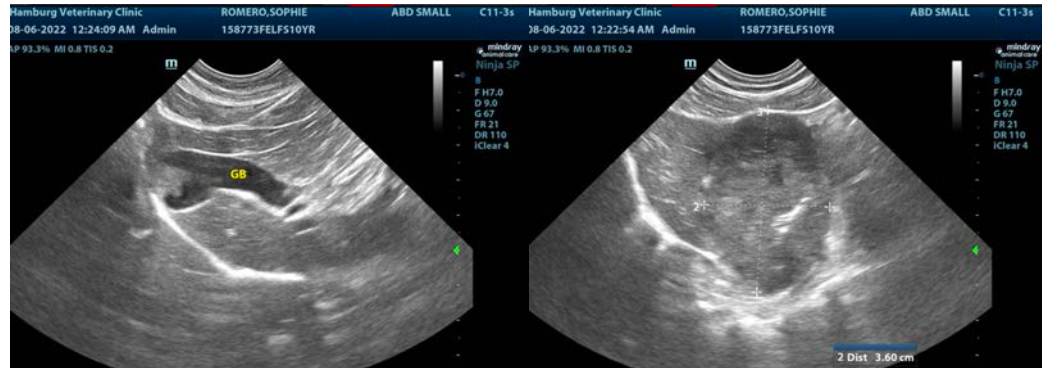Dr. Bingaman

**INVOICE**

40234

**DATE**

8/5/22



The information and recommendations provided are based on the images presented by the referring veterinarian/sonographer. No evaluation can be communicated regarding pathology that was not visible in the image/video clips provided.

Thank you for this referral. If the clinical or image interpretation does not parallel your findings or if I can be of any further assistance please contact me.

**Eric Lindquist, DMV, DABVP, Cert. IVUSS, CEO of SonoPath.com**

[info@SonoPath.com](mailto:info@SonoPath.com)