



**PATIENT**

Oliver Lewis

**SPECIES**

Feline

**BREED**

DSH

**SEX**

Neutered Male

**AGE**

14 Years

**WEIGHT**

8.75 Pounds

**INTERPRETED BY**

Eric Lindquist, DMV,  
DABVP, Cert. IVUSS

**IMAGING PERFORMED BY**

Sara Hansen

**HOSPITAL NAME**

Countryside AC

**REFERRING VET**

Dr. Cox

**DATE**

8/5/22

**Invoice**

16719

**PRESENTING CLINICAL SIGNS**

History: history of seizures - managed on Phenobarbital weight loss tachycardia vomiting daily for months dental disease

Abnormal PE/Chem/CBC/UA Results: Slight Howell Jolly Bodies Ca 12.4, Cl 113 Spec fPL = 5.3 T4 is wnl; at 1.5 Phenobarbital leve = 30 Urinalysis: spgr 1.030, ph = 7.5, 2+ epi cells, occasional fine granular cast Current Medications Phenobarbital 16mg 1/2 tab BID

**ULTRASONOGRAPHIC EXAMINATION OF THE ABDOMEN**

**Urinary System**

The **urinary bladder**, trigone, and pelvic urethra presented normal thicknesses and normal tone. The ureters were not visible which is normal. No uroliths or sediment were visualized, and anechoic urine was present. No evidence of inflammatory or neoplastic changes were noted. Ureteral papillae were normal.

The **kidneys** revealed largely normal size and structure, corticomedullary definition and ratio (cortex 1/3 of medulla) were essentially maintained with some moderate age-related loss of curvilinear patterns regarding the capsule and C/M junction. The cortices presented largely uniform texture with some increased echogenicity expected for his age patient. Medullary structure differed distinctly from that of the cortex and no evidence of pelvic dilation was present. The left kidney measured 3.53 cm. The right kidney measured 3.58 cm.

**Adrenal Glands**

The **left adrenal gland** was visualized and recognized as having normal shape, size, position and echogenicity for this breed. The phrenic vasculature, glandular echogenicity and detail were unremarkable. Capsule, cortex, and medullary definition were normal for this age patient. The left adrenal gland measured 0.48 cm.

The region of the **right adrenal gland** revealed no evident pathology.

**Spleen**

The **spleen** presented a smooth homogeneous parenchyma hyperechoic to liver and renal cortical parenchyma. The capsule was smooth without noticeable expansion or deviation from within the spleen or adjacent pathology. The splenic vasculature demonstrated normal volume without signs of congestion or thrombosis. No sonographic evidence of acute or chronic inflammatory, neoplastic, or infarctual changes were noted.

**Liver**

The **liver** images from right and left intercostal as well as subcostal views revealed subjectively normal liver size, contour, and structure. Some mild age-related parenchymal remodeling was noted but likely not clinically significant at this time. Vascular and biliary tracts were of normal volume and no evidence of congestion was noted. The gallbladder presented some dependent debris with essentially normal contour. The cystic and common bile ducts were normal. No overt evidence of active



**PATIENT**

Oliver Lewis

inflammatory, infiltrative or regenerative pathology was noted but should be paired with current or past LE elevations regarding any clinical significance to this presentation. The hepatic lymph nodes were unremarkable.

**SPECIES**

Feline

**Gastrointestinal**

The **gastrointestinal tract** revealed minor variable thickening and echogenic submucosal changes most consistent with low grade end result of chronic GI disease such as IBD and may be related to malassimilation of nutrients if any weight loss is present. No obvious neoplastic patterns were noted and luminal content as unremarkable. This is a mild change.

**BREED**

DSH

**Pancreas**

The base and limbs of the **pancreas** were observed to be largely isoechoic to surrounding omental fat. Pancreatic duct and capsular contour were acceptably normal and parenchyma respected normal curvilinear patterns. No overt evidence of active inflammatory or neoplastic disease was noted.

**SEX**

Neutered Male

**ULTRASONOGRAPHIC FINDINGS**

- Geriatric abdomen

**AGE**

14 Years

**INTERPRETATION OF THE FINDINGS & FURTHER RECOMMENDATIONS**

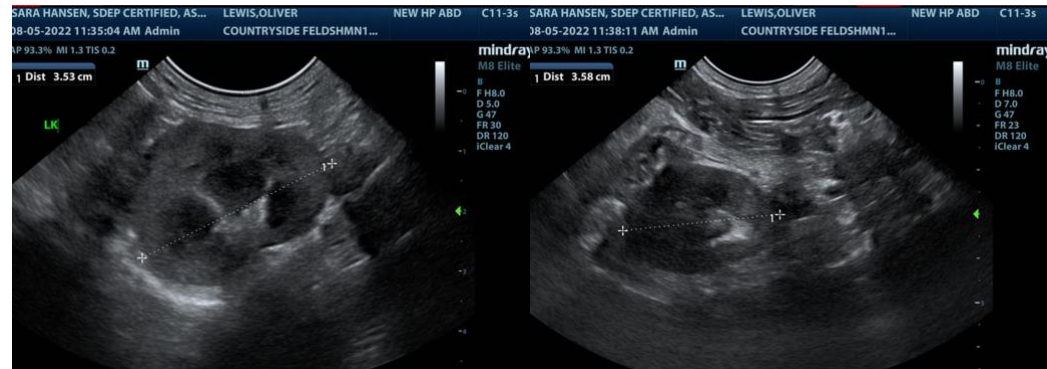
**WEIGHT**

8.75 Pounds

No evidence of structural/visceral disease.

**INTERPRETED BY**

Eric Lindquist, DMV,  
DABVP, Cert. IVUSS

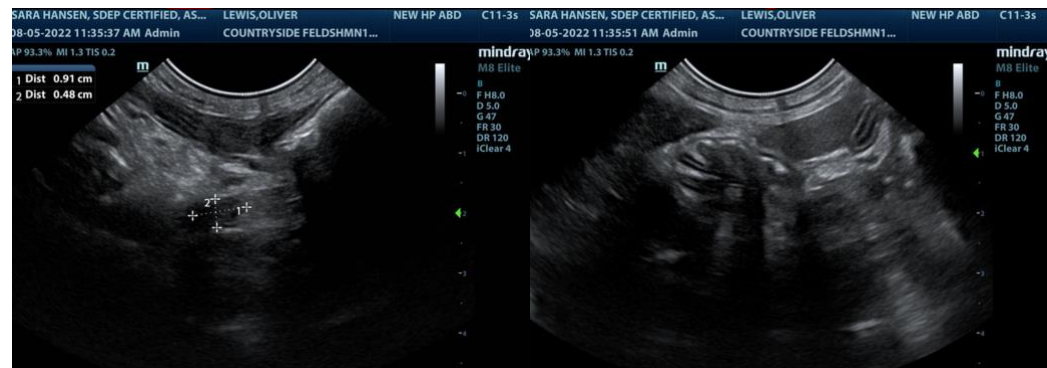

**IMAGING PERFORMED BY**

Sara Hansen

**HOSPITAL NAME**

Countryside AC



**REFERRING VET**

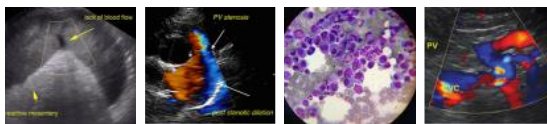
Dr. Cox

**DATE**

8/5/22

**Invoice**

16719



**PATIENT**

Oliver Lewis

**SPECIES**

Feline

**BREED**

DSH

**SEX**

Neutered Male

**AGE**

14 Years

**WEIGHT**

8.75 Pounds

**INTERPRETED BY**

**Eric Lindquist**, DMV,  
DABVP, Cert. IVUSS

**IMAGING PERFORMED BY**

Sara Hansen

**HOSPITAL NAME**

Countryside AC

**REFERRING VET**

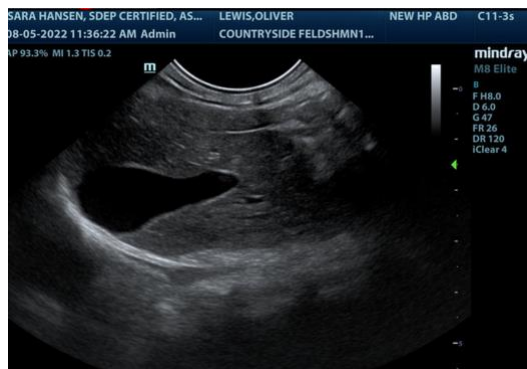Dr. Cox

**DATE**

8/5/22

**Invoice**

16719



The information and recommendations provided are based on the images presented by the referring veterinarian. No evaluation can be communicated regarding pathology that was not visible in the image/video clips provided.

Thank you for this referral. If the clinical or image interpretation does not parallel your findings or if I can be of any further assistance please contact me.

**Eric Lindquist**, DMV, DABVP, Cert. IVUSS, CEO of SonoPath.com

info@SonoPath.com