

**DATE**

08/05/2022

PRESENTING CLINICAL SIGNS

Recheck spleen- possible abnormal scan in June. Pet doing well.

PATIENT

Lyssa Martin

Current Medications: None listed.

Date of Previous IntraPet Ultrasound: May 17, 2022. See attached.

Sedation: Declined.

Stat Report: Not requested.

Imaging Performed By: Rachel Brillhart, RDMS.

SPECIES

Canine

ULTRASONOGRAPHIC EXAMINATION OF THE ABDOMEN**BREED**

Basset Hound

Urinary System

The urinary bladder, trigone, and pelvic urethra presented normal thicknesses and normal tone. The ureters were not visible which is normal. No uroliths or sediment were visualized and anechoic urine was present. No evidence of inflammatory or neoplastic changes were noted. Ureteral papillae were normal.

SEX

FI

The kidneys revealed normal size and structure, corticomedullary definition and ratio for this age. The cortices presented largely uniform texture with normal echogenic relationship to liver and spleen. Medullary structure differed distinctly from the cortex and no evidence of pelvic dilation was present. The capsules were acceptably uniform without significant irregularities. The left kidney measured 7.06 cm in length. The right kidney measured 5.95 cm in length.

AGE

2018

WEIGHT

60lb

The residual uterus appears to have an extended body to the level of the mid bladder. Suture granuloma measuring 1.72 cm was present. Clean separation from the urinary bladder was not evident.

Adrenal Glands

Both adrenal glands were visualized and recognized as having normal shape, size, position and echogenicity for this breed. The phrenic vasculature, glandular echogenicity and detail were unremarkable. Capsule, cortex, and medullary definition were normal for this age patient. The left adrenal gland measured 2.74 cm in length by 0.52 cm caudal pole width by 0.56 cm cranial pole width. The right adrenal gland measured 2.75 cm in length by 0.52 cm caudal pole width by 0.67 cm cranial pole width.

INTERPRETED BY

Eric Lindquist, DMV
DABVP, Cert. IVUSS

HOSPITAL NAME

Cambria Vet Canter

Spleen

The spleen nodule/mass is persistently present and is smaller measuring 2.3 cm although other heterogenous changes are noted there is significant improvement over the prior sonogram.

REFERRING VET

Dr. Hartman

Liver

The liver images submitted revealed subjectively normal liver size, contour, and structure. Parenchymal echogenicity was naturally coarse and hypoechoic to the spleen. Vascular and biliary tracts were of normal volume with no evidence of congestion.

INVOICE

11295ag

The gallbladder presented acceptably thin walls with primarily anechoic content. The cystic and common bile ducts were normal. No pathological hepatic lymphadenopathy was evident. No overt structural evidence of inflammatory, infiltrative or regenerative pathology was evident.

Gastrointestinal

Examination of the gastrointestinal tract revealed a stomach and intestine free of stasis, of normal wall thickness, acceptable curvilinear mural detail, and peristaltic activity. Small and large intestine demonstrated normal luminal chyme and stool consistency respectively. No obstructive or overt infiltrative disease was noted. No associated abnormal lymphatic activity was noted.

Pancreas

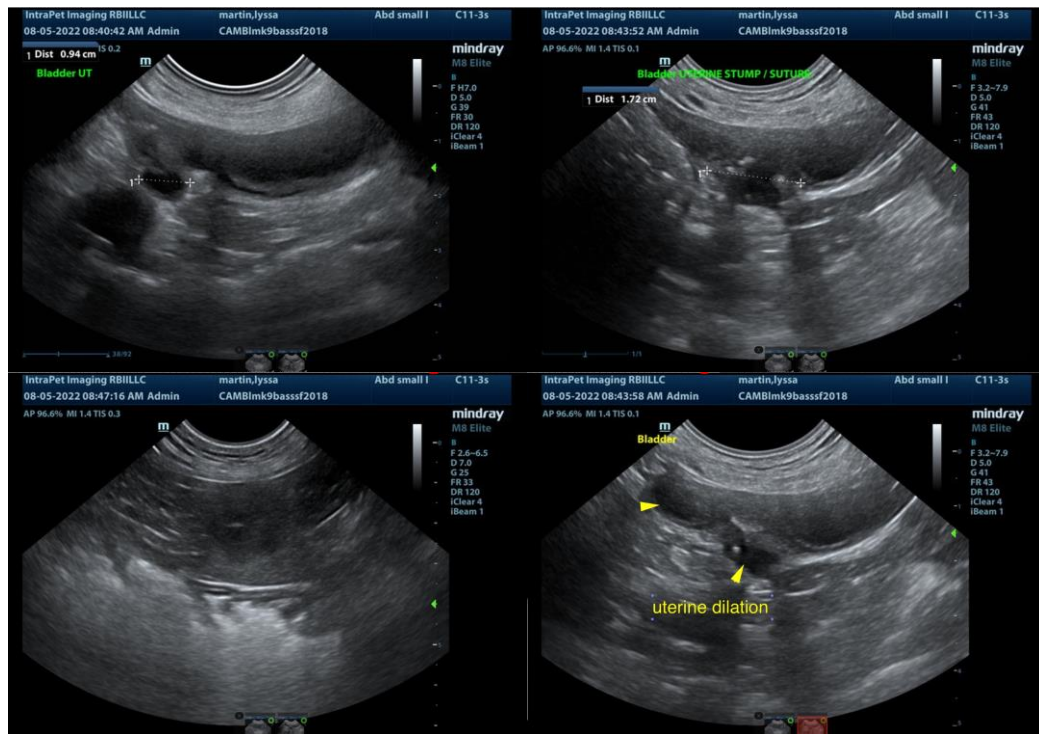
The base and limbs of the pancreas were observed to be largely isoechoic to surrounding omental fat. Pancreatic duct and capsular contour were acceptably normal and parenchyma respected normal curvilinear patterns. No overt evidence of active inflammatory or neoplastic disease was noted.

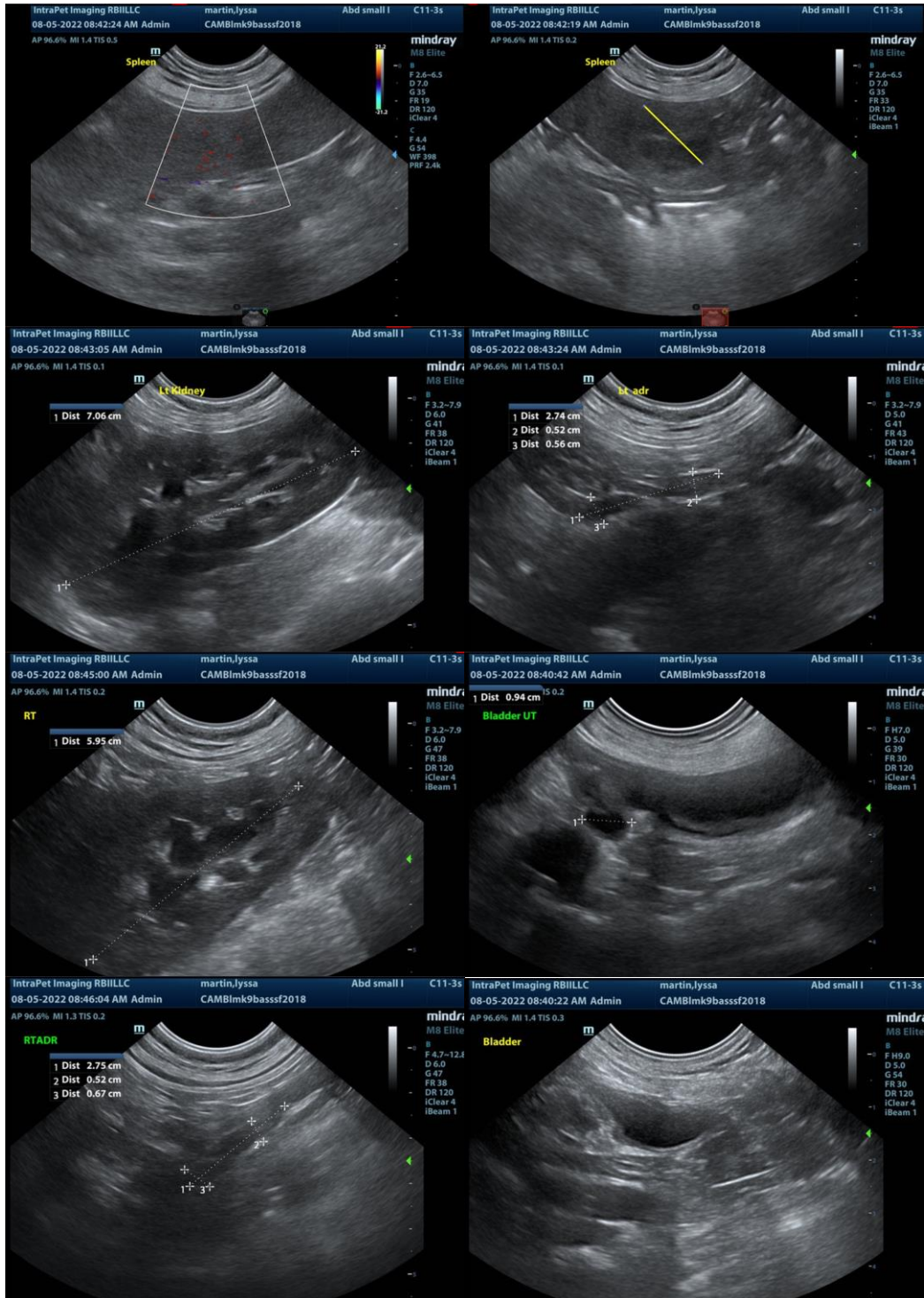
ULTRASONOGRAPHIC FINDINGS

- Persistent yet regressed splenic nodule, likely history of abscessation or necrosis
- Uterine suture granuloma
- Rapid view of the heart revealed no evident pathology

INTERPRETATION OF THE FINDINGS & FURTHER RECOMMENDATIONS

As a preventive measure surgical intervention with resection of the residual uterine stump to the level of the cervix as well as ensuring there is no adhesion to the urinary bladder wall is recommended. Preventive splenectomy could be considered at this time as well.





The information and recommendations provided are based on the images presented by the referring veterinarian. No evaluation can be communicated regarding pathology that was not visible in the image/video clips provided.

Thank you for this referral. If the clinical or image interpretation does not parallel your findings or if I can be of any further assistance please contact me.

Eric Lindquist, DMV, DABVP, Cert. IVUSS, CEO of SonoPath.com
Eric.Lindquist@SonoPath.com