



PATIENT PRESENTING CLINICAL SIGNS

Luna Ore History: Recent surgical removal of 2 masses (L ear and R hip) Staging for neoplasia

SPECIES Abnormal PE/Chem/CBC/UA Results: PE: BCS 6/9 Pre-op CBC/Chem: NAF Histopath: 1. L ear = Grade 2, low grade, MCT, dirty margins 2. R hip = Peripheral Nerve sheath tumor (intermediate grade 2), dirty margins

Canine

ULTRASONOGRAPHIC EXAMINATION OF THE ABDOMEN

BREED
Urinary System

Golden Retriever

The **urinary bladder**, trigone, and pelvic urethra presented normal thicknesses and normal tone. The ureters were not visible which is normal. No uroliths or sediment were visualized, and anechoic urine was present. No evidence of inflammatory or neoplastic changes were noted. Ureteral papillae were normal.

SEX

Spayed Female

AGE

8 Years

The **kidneys** revealed largely normal size and structure, corticomedullary definition and ratio (cortex 1/3 of medulla) were essentially maintained with some minor age-related loss of curvilinear patterns regarding the capsule and C/M junction. The cortices presented largely uniform texture with some increased echogenicity expected for his age patient. Medullary structure differed distinctly from that of the cortex and no evidence of pelvic dilation was present. The left kidney measured 6.7 cm. The right kidney measured 7.25 cm.

WEIGHT

81 Pounds

Adrenal Glands

The **adrenal glands** were not visualized.

INTERPRETED BY

Eric Lindquist, DMV
DABVP, Cert. IVUSS

Spleen

The **spleen** presented a smooth homogeneous parenchyma hyperechoic to liver and renal cortical parenchyma. The capsule was smooth without noticeable expansion or deviation from within the spleen or adjacent pathology. The splenic vasculature demonstrated normal volume without signs of congestion or thrombosis. No sonographic evidence of acute or chronic inflammatory, neoplastic, or infarctual changes were noted. Caudal folding of the spleen was noted, uniform.

IMAGING PERFORMED BY

Mayra Sanchez

Liver

HOSPITAL NAME

Sunset AH

The **liver** images from right and left intercostal as well as subcostal views revealed subjectively normal liver size, contour, and structure. Some minor age-related parenchymal remodeling was noted but likely not clinically significant at this time. Vascular and biliary tracts were of normal volume and no evidence of congestion was noted. The gallbladder presented some dependent debris with essentially normal contour. The cystic and common bile ducts were normal. No overt evidence of active inflammatory, infiltrative or regenerative pathology was noted but should be paired with current or past LE elevations regarding any clinical significance to this presentation. The hepatic lymph nodes were unremarkable.

REFERRING VET

Cristina Polit

INVOICE

16732

Gastrointestinal

DATE

8/5/22

The **gastrointestinal tract** presented considerable gastric artifact due to the presence of ingesta. This did not permit thorough evaluation of portions of the gastric and upper intestinal structure. No overt abnormality was seen in the visualized tissue, however. This is consistent with a post-prandial presentation within a few hours of mealtime. If the prandial temporal interval does not fit the case



PATIENT

Luna Ore

history, and the patient presents a history of post-prandial vomiting, this could indicate a delayed upper gastrointestinal outflow due to primary or secondary pyloric hypertrophy, upper GI infiltrative disease, motor deficits, or a non-visualized foreign body. A prudent approach would be to rescan this patient at 24 hour NPO status to further review the non-visible regions if stomach primarily as well as assess any delayed outflow issue.

SPECIES

Canine

Pancreas

BREED

Golden Retriever

The base and limbs of the **pancreas** were observed to be largely isoechoic to surrounding omental fat. Pancreatic duct and capsular contour were acceptably normal and parenchyma respected normal curvilinear patterns. No overt evidence of active inflammatory or neoplastic disease was noted.

SEX

Spayed Female

- Age-related hepatic and renal changes
- Full stomach, post prandial presentation

AGE

8 Years

INTERPRETATION OF THE FINDINGS & FURTHER RECOMMENDATIONS

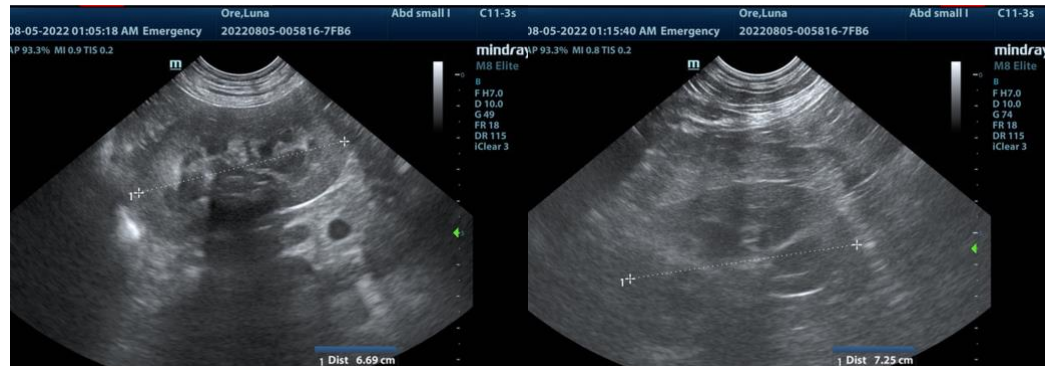
No evidence of pathology related to mast cell or other disease.

WEIGHT

81 Pounds

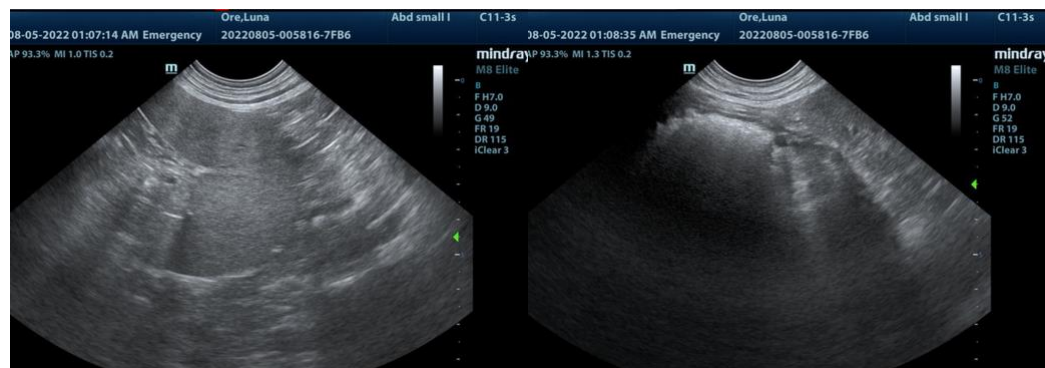
INTERPRETED BY

Eric Lindquist, DMV
DABVP, Cert. IVUSS



IMAGING PERFORMED BY

Mayra Sanchez



HOSPITAL NAME

Sunset AH

REFERRING VET

Cristina Polit

INVOICE

16732

DATE

8/5/22



PATIENT

Luna Ore

SPECIES

Canine

BREED

Golden Retriever

SEX

Spayed Female

AGE

8 Years

WEIGHT

81 Pounds

INTERPRETED BY

Eric Lindquist, DMV
DABVP, Cert. IVUSS

**IMAGING
PERFORMED BY**

Mayra Sanchez

HOSPITAL NAME

Sunset AH

REFERRING VET

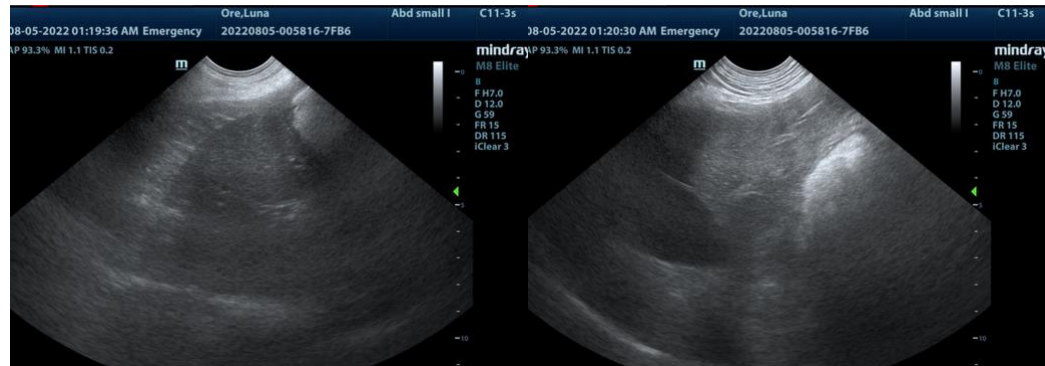
Cristina Polit

INVOICE

16732

DATE

8/5/22



The information and recommendations provided are based on the images presented by the referring veterinarian. No evaluation can be communicated regarding pathology that was not visible in the image/video clips provided.

Thank you for this referral. If the clinical or image interpretation does not parallel your findings or if I can be of any further assistance please contact me.

Eric Lindquist, DMV, DABVP, Cert. IVUSS, CEO of SonoPath.com
info@SonoPath.com