

**DATE**

08/05/2022

PRESENTING CLINICAL SIGNS

Chronic intermittent diarrhea starting end of June 2022. Occ vomiting. Treated and responds to metro and probiotic, but returns once discontinued. Has been on EN and now recently switched to hydrolyzed protein. Also adding fiber to diet. Appetite and energy normal. Bloodwork and rads unremarkable.

PATIENT

Jackson Jacobs

Current Medications: Fortiflora, metamucil and hydrolyzed protein diet.

Lab Results: PCV, Chem 10 WNL.

Radiographs: WNL.

Date of Previous IntraPet Ultrasound: No previous.

Sedation: Not required to complete full diagnostic ultrasound.

Stat Report: Not requested.

Imaging Performed By: Stephanie Warga RDCS, RVT.

SPECIES

Canine

BREED

Labrador

ULTRASONOGRAPHIC EXAMINATION OF THE ABDOMEN**SEX**

MN

Urinary System

The urinary bladder, trigone, and pelvic urethra presented normal thicknesses and normal tone. The ureters were not visible which is normal. No uroliths or sediment were visualized and anechoic urine was present.

No evidence of inflammatory or neoplastic changes were noted. Ureteral papillae were normal.

AGE

2013

The kidneys revealed normal size and structure, corticomedullary definition and ratio for this age. The cortices presented largely uniform texture with normal echogenic relationship to liver and spleen. Medullary structure differed distinctly from the cortex and no evidence of pelvic dilation was present. The capsules were acceptably uniform without significant irregularities. The left kidney measured 6.82 cm in length. The right kidney measured 6.2 cm in length.

WEIGHT

85lb

The residual prostate was mildly enlarged and uniform measuring 1.86 cm.

INTERPRETED BY

Eric Lindquist, DMV
DABVP, Cert. IVUSS

Adrenal Glands

Both adrenal glands were visualized and recognized as having normal shape, size, position and echogenicity for this breed. The phrenic vasculature, glandular echogenicity and detail were unremarkable. Capsule, cortex, and medullary definition were normal for this age patient. The left adrenal gland measured 3.02 cm in length by 0.52 cm caudal pole width by 0.58 cm cranial pole width. The right adrenal gland measured 2.39 cm in length by 0.88 cm caudal pole width by 0.82 cm cranial pole width.

HOSPITAL NAME

Hickory Veterinary
Hospital

Spleen**REFERRING VET**

Dr. Lyle

The spleen presented a smooth homogeneous parenchyma hyperechoic to liver and renal cortical parenchyma. The capsule was smooth without noticeable expansion or deviation from within the spleen or adjacent pathology. The splenic vasculature demonstrated normal volume without signs of congestion or thrombosis. No sonographic evidence of acute or chronic inflammatory, neoplastic, or infarctual changes were noted.

INVOICE

11290ag

Liver

The liver images submitted revealed subjectively normal liver size, contour, and structure. Parenchymal echogenicity was naturally coarse and hypoechoic to the spleen. Vascular and biliary tracts were of normal volume with no evidence of congestion. The gallbladder presented acceptably thin walls with primarily anechoic content. The cystic and common bile ducts were normal. No pathological hepatic

lymphadenopathy was evident. No overt structural evidence of inflammatory, infiltrative or regenerative pathology was evident.

Gastrointestinal

Examination of the gastrointestinal tract revealed a stomach and intestine free of stasis, of normal wall thickness, acceptable curvilinear mural detail, and peristaltic activity. Small and large intestine demonstrated normal luminal chyme and stool consistency respectively. No obstructive or overt infiltrative disease was noted. No associated abnormal lymphatic activity was noted.

Pancreas

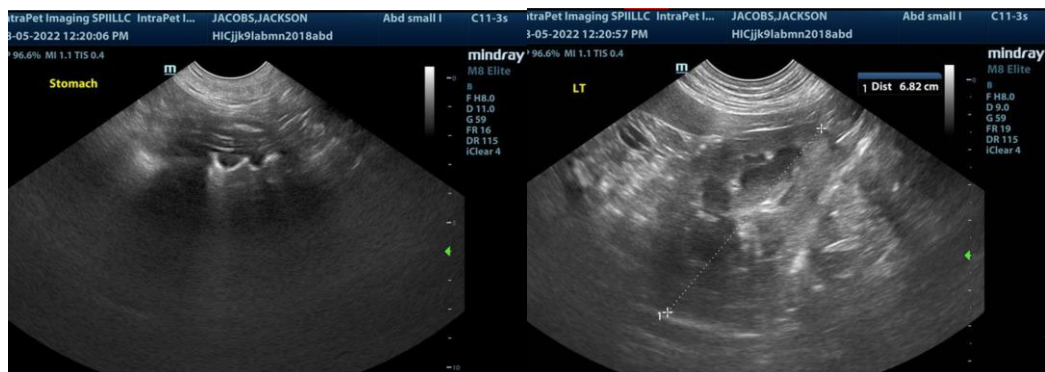The base and limbs of the pancreas were observed to be largely isoechoic to surrounding omental fat. Pancreatic duct and capsular contour were acceptably normal and parenchyma respected normal curvilinear patterns. No overt evidence of active inflammatory or neoplastic disease was noted.

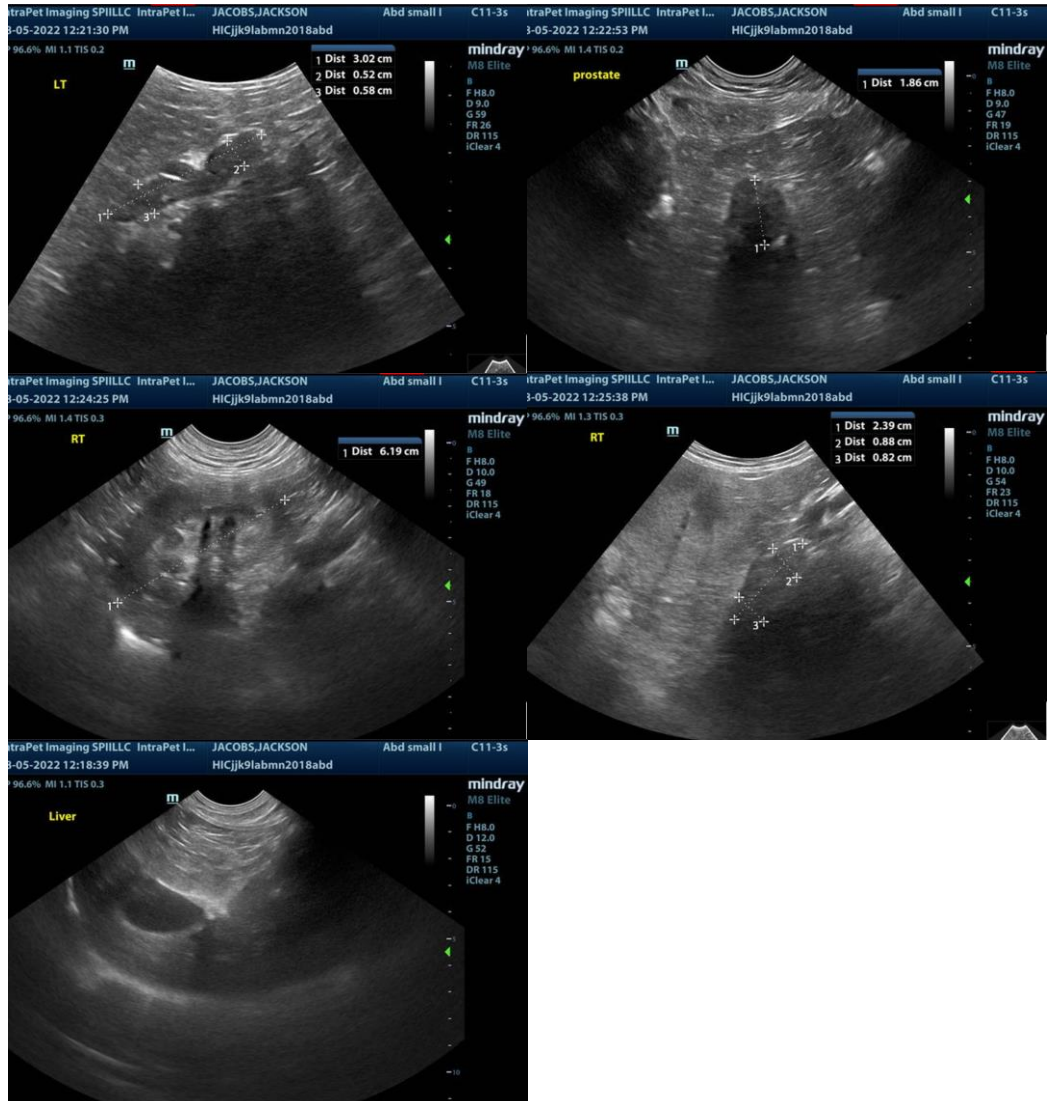
ULTRASONOGRAPHIC FINDINGS

- Structurally unremarkable abdomen

INTERPRETATION OF THE FINDINGS & FURTHER RECOMMENDATIONS

No evidence of abdominal pathology was present on this study. Occult parasitism, dietary intolerance, structurally insignificant inflammatory bowel or occult Addison's disease are all possible even though the adrenal glands appear structurally normal. A baseline cortisol is indicated to rule out the potential for Addison's disease. A diet change to a hydrolyzed diet and a broad spectrum anti parasitic protocol may be beneficial.





The information and recommendations provided are based on the images presented by the referring veterinarian. No evaluation can be communicated regarding pathology that was not visible in the image/video clips provided.

Thank you for this referral. If the clinical or image interpretation does not parallel your findings or if I can be of any further assistance please contact me.

Eric Lindquist, DMV, DABVP, Cert. IVUSS, CEO of SonoPath.com
 Eric.Lindquist@SonoPath.com