



PATIENT

Hershey Martin

SPECIES

Canine

BREED

Boston Terrier

SEX

Neutered Male

AGE

10 Years

WEIGHT

15 Pounds

PRESENTING CLINICAL SIGNS

History: Grade 2/6 mitral.aortic, reg rate/rhythm , cardiac work up. No current meds.

Abnormal PE/Chem/CBC/UA Results: AST (SGOT)9 (low), PSL 205 (high), Platelet count 474 (high).

ULTRASONOGRAPHIC EXAMINATION OF THE HEART

CANINE CARDIAC PARAMETERS	MR VMAX (m/s)	TR VMAX (m/s)	LA/AO (Boon method)	LA/AO (Heart Base; Swe)	FS (%)	EF (%)	EPSS (cm)
NORMAL PARAMETER	4.5-5.5	<2.7	1.3	<1.3	28-40	40-100	<0.6
PATIENT			NM		57	89	0.15
CANINE CARDIAC PARAMETERS	HR (BPM)	AV VMAX (m/s)	PV MAX (m/s)	BODY WEIGHT (kg)	LA 2D short axis Base view (cm)	LVIDd Avg; 2D and m-mode short axis (cm)	LVIDs Avg; 2D and m-mode short axis (cm)
NORMAL PARAMETER	50-100	0.7-1.7	0.7-1.6				
PATIENT	105	1.77	1.10	--	2.08	2.39	--

INTERPRETED BY

Eric Lindquist, DMV
DABVP, Cert. IVUSS

IMAGING PERFORMED BY

Kelly Vazquez

HOSPITAL NAME

Brenda King VS

REFERRING VET

Dr. Brenda King

Cardiac Presentation

The echocardiogram in this patient demonstrated normal **left atrial** size based on 3 separate methods of LA evaluation. Trivial mitral insufficiency noted. The **left ventricle** presented thicknesses with linear contour and was not dilated nor restricted. The **myocardium** presented normal echogenicity without subjective evidence of significant fibrotic or ischemic disease. **Contractility** and internal volumes appear to be intact. The **left ventricular outflow** tract demonstrated normal laminar flow and subjective structural integrity. The **right atrium** and auricle revealed normal size, structure and content. No evidence of masses was noted. Tricuspid insufficiency noted. The **right ventricle** was of normal size (1/3 diameter of LV), chordae structure, myocardial echogenicity and thickness. **Pulmonary outflow** tract assessment revealed normal valve structure, laminar flow, and diameter (approx.1:1 pa/ao ratio). A 3.36 cm x 3.3 cm echogenic heart base mass was noted adjacent to the aorta overlying the left atrium. Portions of the mass extend out beyond the acoustic window and may actually be larger. Chest CT would be ideal for further definition. The deep pulmonary artery appeared to be deviated owing to the mass.

ULTRASONOGRAPHIC FINDINGS

- Heart base mass. Aortic body tumor/chemodectoma pattern
- Trivial mitral and tricuspid insufficiency, not clinically significant

INTERPRETATION OF THE FINDINGS & FURTHER RECOMMENDATIONS

Blood pressure and EKG warranted, if not already performed. Recheck echo in 3 months or sooner if

INVOICE

16715

DATE

8/5/22



PATIENT

clinical signs develop.

Hershey Martin

SPECIES

Canine

BREED

Boston Terrier

SEX

Neutered Male

AGE

10 Years

WEIGHT

15 Pounds

INTERPRETED BY

Eric Lindquist, DMV
DABVP, Cert. IVUSS

IMAGING PERFORMED BY

Kelly Vazquez

HOSPITAL NAME

Brenda King VS

REFERRING VET

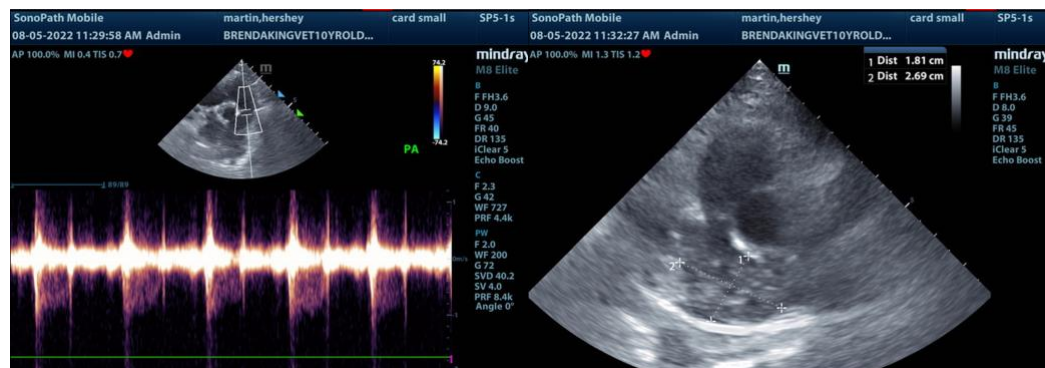
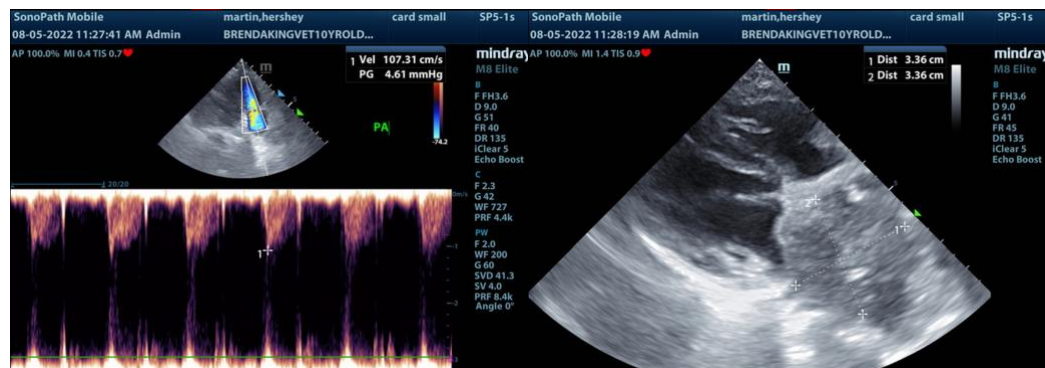
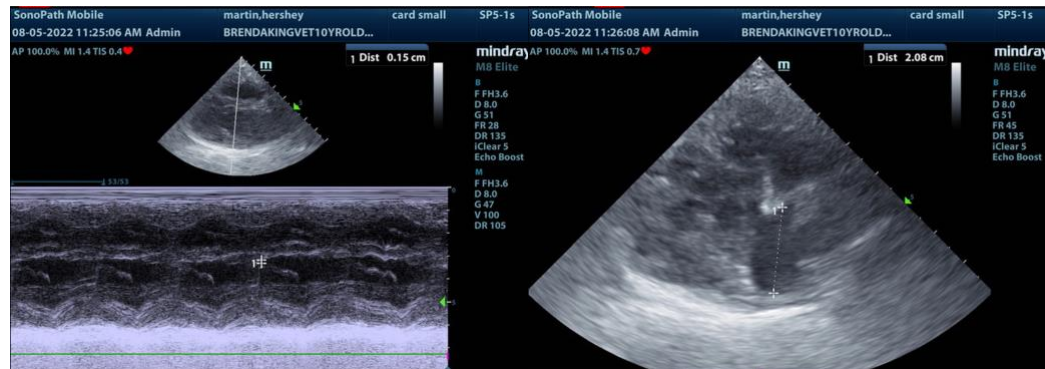
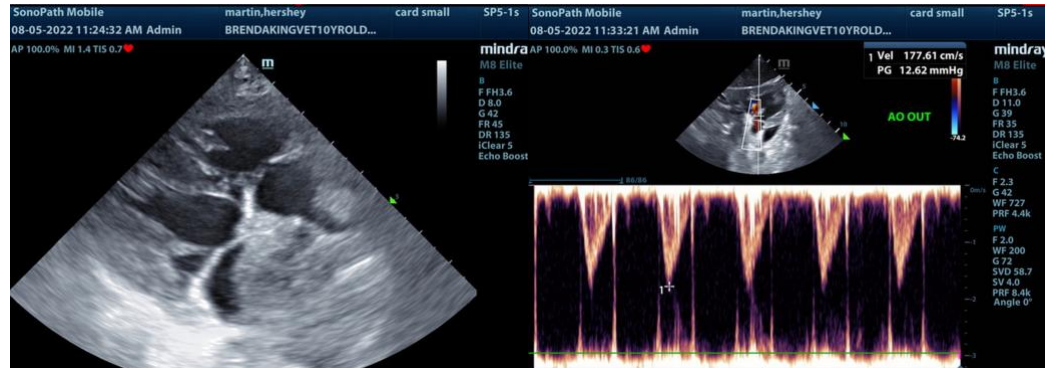Dr. Brenda King

INVOICE

16715

DATE

8/5/22





PATIENT

Hershey Martin

SPECIES

Canine

BREED

Boston Terrier

SEX

Neutered Male

AGE

10 Years

WEIGHT

15 Pounds

INTERPRETED BY

Eric Lindquist, DMV
DABVP, Cert. IVUSS

IMAGING PERFORMED BY

Kelly Vazquez

HOSPITAL NAME

Brenda King VS

REFERRING VET

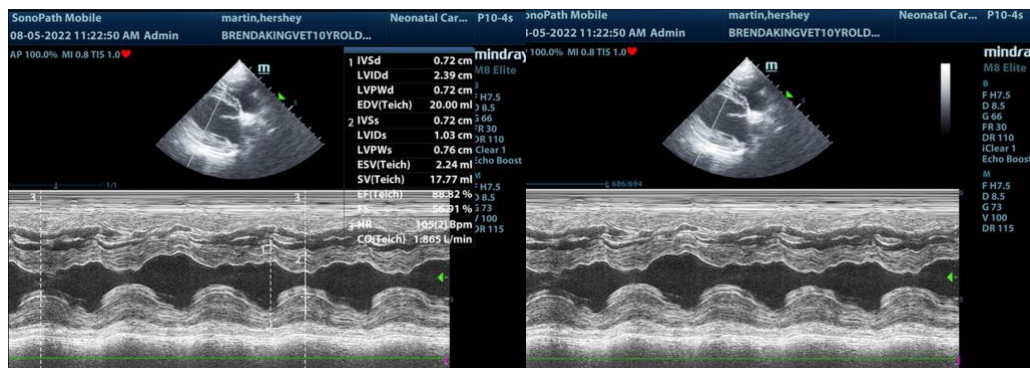Dr. Brenda King

INVOICE

16715

DATE

8/5/22



The information and recommendations provided are based on the images presented by the referring veterinarian. No evaluation can be communicated regarding pathology that was not visible in the image/video clips provided.

Thank you for this referral. If the clinical or image interpretation does not parallel your findings or if I can be of any further assistance please contact me.

Eric Lindquist, DMV, DABVP, Cert. IVUSS, CEO of SonoPath.com
info@SonoPath.com

Pericardial Effusion and Cardiac Neoplasia

<http://www.sonopath.com/CardiacNeoplasiaEffusion>

Description: The pericardium is a fibrous sac that encloses the heart and the great vessels—aorta, pulmonary artery, proximal pulmonary veins, and vena cava—located at the heart’s base. It is attached caudally to the diaphragm and under normal circumstances contains 1-15 mL of fluid. The latter is comprised of phospholipids that lubricate the heart and allow it to expand and contract without generating friction. The pericardium also fixes the heart, prevents excess motion, and links the diastolic distensibility of the ventricles, thus limiting the degree to which either the left or the right ventricle will distend during diastole. When there are acute changes in venous return (i.e., during exercise), the pericardium plays a critical role in limiting ventricular filling. In cases of chronic cardiac enlargement, the pericardium also becomes distended, and its ability to limit ventricular filling, especially when the heart is at rest, becomes compromised. Pericardial tamponade occurs when there is a rapid accumulation of fluid and the pressure inside the pericardium increases significantly. With tamponade, ventricular filling is restricted and cardiac output is decreased. The right atrium and ventricle are the most vulnerable to this condition as these compartments have thinner walls and a lower pressure.

Etiology: Causes of pericardial effusion include:

- Neoplasia



PATIENT

Hershey Martin

SPECIES

Canine

BREED

Boston Terrier

SEX

Neutered Male

- Right atrial (RA) hemangiosarcoma
- Heart base (aortic body) tumors
- Mesothelioma
- Rhabdomyosarcoma
- Ectopic thyroid carcinoma
- Metastatic neoplasia

- Idiopathic
- Congestive heart failure
- Peritoneal-pericardial diaphragmatic hernia
- Pericardial cyst
- Hypoalbuminemia
- Infectious pericarditis (bacterial, *Coccidioides immitus*)
- Feline infectious peritonitis
- Left atrial tear secondary to valvular disease
- Coagulopathy

AGE

10 Years

WEIGHT

15 Pounds

The majority of neoplastic masses consist of hemangiosarcoma and heart-based tumors (chemodectomas or ectopic thyroid adenocarcinoma). Idiopathic pericardial effusion is a diagnosis of exclusion; the effusion is typically hemorrhagic. Approximately 50% of dogs will be cured with a single pericardiocentesis, while some dogs will require multiple pericardiocenteses as well as surgery. A peritoneal-pericardial diaphragmatic hernia is a congenital hernia seen in dogs and cats in which the abdominal contents (i.e., liver, small intestine, spleen, stomach) herniate into the pericardial sac. Constrictive pericarditis is an uncommon condition in which a non-distensible, thickened, fibrotic pericardium develops over time.

INTERPRETED BY

Eric Lindquist, DMV
DABVP, Cert. IVUSS

Clinical Signs: One will observe the following clinical signs, which often present in combination: ascites, lethargy, exercise intolerance, pale mucous membranes, weak pulses, *pulsus paradoxus*, and respiratory distress.

IMAGING PERFORMED BY

Kelly Vazquez

HOSPITAL NAME

Brenda King VS

Diagnostics: Survey radiographs will reveal hepatomegaly, cardiomegaly (generalized or sectorial globoid), and small pulmonary vessels. Pulmonary edema is typically not found, although one may discover concurrent pulmonary metastatic disease. An ECG will show electrical alternans or small complexes, but often the changes are very subtle and difficult to detect.

REFERRING VET

Dr. Brenda King

Echocardiography is usually considered the gold standard for diagnosing pericardial effusion. Findings include:

INVOICE

16715

DATE

8/5/22

- Anechoic space between the heart and the pericardium.
- Abnormal side-to-side cardiac motion.
- Decreased chamber size (right ventricle [RV] and left ventricle [LV]).
- Presence of a pericardial or cardiac mass.
- Tamponade with early diastolic RA and RV collapse.



PATIENT

Cytology is helpful in the diagnosis of lymphoma, septic pericarditis, and idiopathic effusion, but not in cases of neoplasia.

Hershey Martin

SPECIES

According to a study that found troponin I levels to be higher in dogs with neoplastic pericardial effusion, the cardiac troponin I assay can be helpful in the diagnosis hemangiosarcoma.

Canine

BREED

Prognosis:

Boston Terrier

SEX

- Cardiac hemangiosarcoma: < 8 months with surgical debulking and chemotherapy.
- Chemodectoma (aortic derived): MST 730 days post pericardectomy.
- Idiopathic: 50% complete resolution post cardiocentesis; curative with pericardectomy, which can be done via thoracotomy, or thorascopy, or using a balloon to tear the pericardium.
- Mesothelioma: Poor.
- Restrictive pericarditis: Poor, especially when the pericardium has not been surgical stripped.

Neutered Male

AGE

10 Years

WEIGHT

15 Pounds

References:

Cagle LA, Epstein SE, Owens SD, et al. Diagnostic yield of cytology analysis of pericardial effusion in dogs. *J Vet Int Med* 2014;28:66-71.

INTERPRETED BY

Eric Lindquist, DMV
DABVP, Cert. IVUSS

Feigenbaum H. Pericardial disease. In: Feigenbaum H, ed. *Echocardiography, 5th ed.* Philadelphia, PA: Lippincott, Williams & Wilkins; 1994:556-588.

IMAGING PERFORMED BY

Kelly Vazquez

Jackson J, Richter KP, Launer DP. Thorascopic partial pericardectomy in 13 dogs. *J Vet Int Med* 1999;13:529-33.

HOSPITAL NAME

Brenda King VS

Johnson MS, Martin M, Binns S. A retrospective study of clinical findings, treatment and outcome in 143 dogs with pericardial effusion. *J Small Anim Prac* 2004;45:546-52.

REFERRING VET

Dr. Brenda King

Kienle RD, Thomas WP. Echocardiography. In: Nyland TG and Mattoon JS, eds. *Small Animal Diagnostic Ultrasound, 2nd ed.* Philadelphia, PA: WB Saunders; 2000:354-423.

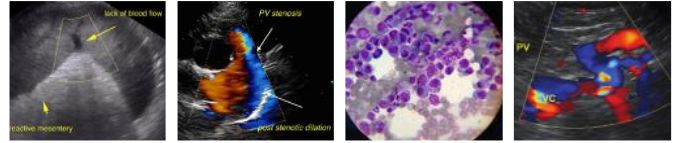
INVOICE

16715

Miller MW, Sisson DD. Pericardial disorders. In: Ettinger SJ and Feldman EC, eds. *Textbook of Veterinary Internal Medicine, 5th ed.* Philadelphia, PA: WB Saunders; 2000:923-36.

DATE

8/5/22



PATIENT

Rajagopalan V, Jesty SA, Craig LE, et al. Comparison of presumptive echocardiographic and definitive diagnoses of cardiac tumors in dogs. *J Vet Int Med* 2013;27:1092-96.

Hershey Martin

SPECIES

Shaw SP, Rozanski EA, Ruhs JE. Cardiac troponins I and T in dogs with pericardial effusion. *J Vet Int Med* 2004;18:322-24.

Canine

BREED

Sidley JA, Atkins CE, Keene BW, et al. Percutaneous balloon pericardiectomy as a treatment for recurrent pericardial effusion in 6 dogs. *J Vet Intern Med* 2002;16:541.

Boston Terrier

SEX

Sisson D, Thomas WP. Pericardial disease and cardiac tumors. In: Fox PR, Sisson D, Moise NS, eds. *Textbook of Canine and Feline Cardiology*, 2nd ed. Philadelphia, PA: WB Saunders; 1999:679-701.

Neutered Male

AGE

Sisson D, Thomas WP, Reed J, et al. Intrapericardial cysts in the dog. *J Vet Int Med* 1993;7:364-69.

10 Years

WEIGHT

15 Pounds

INTERPRETED BY

Eric Lindquist, DMV
DABVP, Cert. IVUSS

IMAGING PERFORMED BY

Kelly Vazquez

HOSPITAL NAME

Brenda King VS

REFERRING VET

Dr. Brenda King

INVOICE

16715

DATE

8/5/22