



PATIENT

Cutie Rivera

SPECIES

Canine

BREED

Shih Tzu

SEX

Spayed Female

AGE

9 Years

WEIGHT

16.8 Pounds

INTERPRETED BY

Eric Lindquist, DMV
DABVP, Cert. IVUSS

**IMAGING
PERFORMED BY**

Kelly Vazquez

HOSPITAL NAME

Animal Paradise
Hospital

REFERRING VET

Dr. Hellwarth

INVOICE

16717

DATE

8/6/22

PRESENTING CLINICAL SIGNS

History: Drinking more water than usual.

Abnormal PE/Chem/CBC/UA Results: BUN 29.8, creat. 1.9, Ca. 14.1, Ca 13.9, ALP 151. USG: 1.010.

ULTRASONOGRAPHIC EXAMINATION OF THE ABDOMEN

Urinary System

The **urinary bladder**, trigone, and pelvic urethra presented normal thicknesses and normal tone. The ureters were not visible which is normal. No uroliths or sediment were visualized, and anechoic urine was present. No evidence of inflammatory or neoplastic changes were noted. Ureteral papillae were normal.

The **kidneys** revealed largely normal size and structure, corticomedullary definition and ratio (cortex 1/3 of medulla) were essentially maintained with some moderate age-related loss of curvilinear patterns regarding the capsule and C/M junction. The cortices presented largely uniform texture with some increased echogenicity expected for his age patient. Medullary structure differed distinctly from that of the cortex and no evidence of pelvic dilation was present. Corticomedullary calculi were noted, nonobstructive. The left kidney measured 3.91 cm. The left kidney measured 3.91 cm.

Adrenal Glands

Both **adrenal glands** were visualized and recognized as having normal shape, size, position and echogenicity for this breed. The phrenic vasculature, glandular echogenicity and detail were unremarkable. Capsule, cortex, and medullary definition were normal for this age patient. The left adrenal gland measured 1.34 cm x 0.43 cm at the caudal pole and 0.42 cm at the cranial pole. The right adrenal gland measured 1.55 cm x 0.9 cm at the cranial pole and 0.65 cm at the caudal pole.

Spleen

Hyperechoic lipogranulomatous changes were noted in the **spleen**.

Liver

The **liver** images from right and left intercostal as well as subcostal views revealed subjectively normal liver size, contour, and structure. Some age-related parenchymal remodeling was noted but likely not clinically significant at this time. Vascular and biliary tracts were of normal volume and no evidence of congestion was noted. The gallbladder presented some dependent debris with essentially normal contour. The cystic and common bile ducts were normal. No overt evidence of active inflammatory, infiltrative or regenerative pathology was noted but should be paired with current or past LE elevations regarding any clinical significance to this presentation. The hepatic lymph nodes were unremarkable.

Gastrointestinal

Examination of the **gastrointestinal tract** revealed a stomach and intestine free of stasis, of normal wall thickness, acceptable curvilinear mural detail, and peristaltic activity. Small and large intestine demonstrated normal luminal chyme and stool consistency respectively. No obstructive or overt infiltrative disease was noted. No associated abnormal lymphatic activity was noted.

Pancreas



PATIENT

Cutie Rivera

The base and limbs of the **pancreas** were observed to be largely isoechoic to surrounding omental fat. Pancreatic duct and capsular contour were acceptably normal and parenchyma respected normal curvilinear patterns. No overt evidence of active inflammatory or neoplastic disease was noted.

SPECIES

Canine

ULTRASONOGRAPHIC FINDINGS

- Age-related abdominal changes
- Mild to moderate degenerative renal changes with corticomedullary mineralization
- Hyperechoic lipogranulomatous changes in the spleen

BREED

Shih Tzu

INTERPRETATION OF THE FINDINGS & FURTHER RECOMMENDATIONS

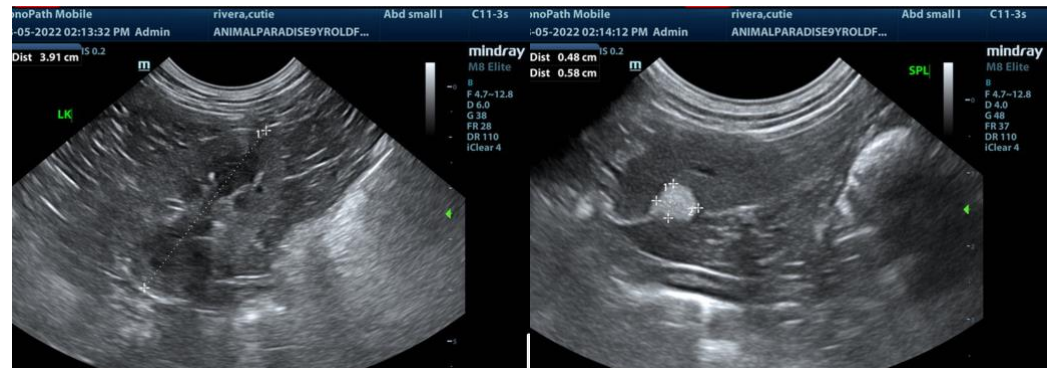No evidence of cause of hypercalcemia in this patient. A hypercalcemia panel is warranted. If primary hypercalcemia is a potential, then parathyroid imaging is warranted. Anal gland palpation, chest radiographs and spinal radiographs warranted as well to assess for hypercalcemia related disease.

SEX

Spayed Female

AGE

9 Years

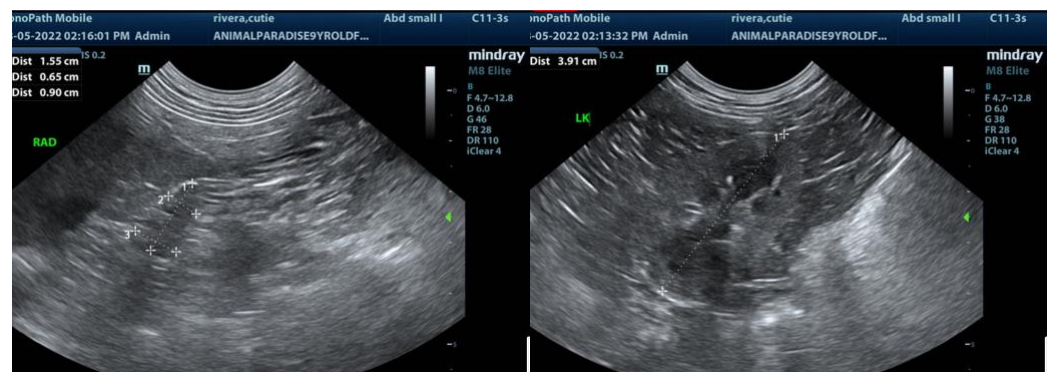


WEIGHT

16.8 Pounds

INTERPRETED BY

Eric Lindquist, DMV
DABVP, Cert. IVUSS



IMAGING PERFORMED BY

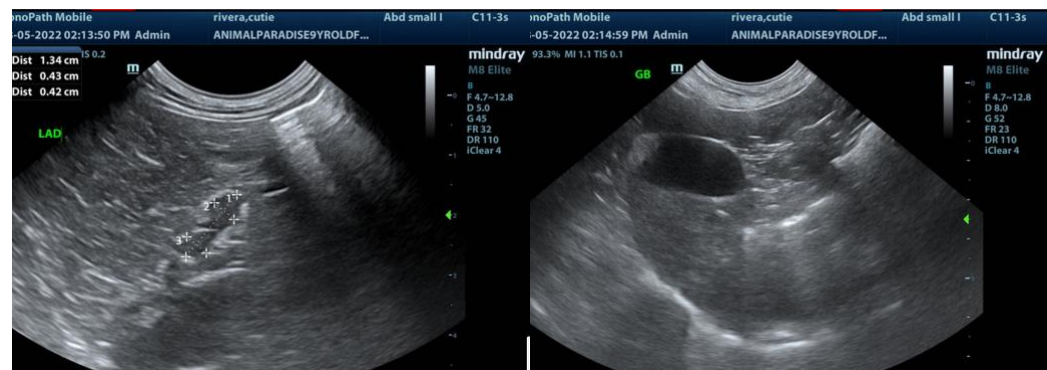
Kelly Vazquez

HOSPITAL NAME

Animal Paradise
Hospital

REFERRING VET

Dr. Hellwarth



INVOICE

16717

DATE

8/6/22



PATIENT

Cutie Rivera

SPECIES

Canine

BREED

Shih Tzu

SEX

Spayed Female

AGE

9 Years

WEIGHT

16.8 Pounds

INTERPRETED BY

Eric Lindquist, DMV
DABVP, Cert. IVUSS

IMAGING PERFORMED BY

Kelly Vazquez

HOSPITAL NAME

Animal Paradise
Hospital

REFERRING VET

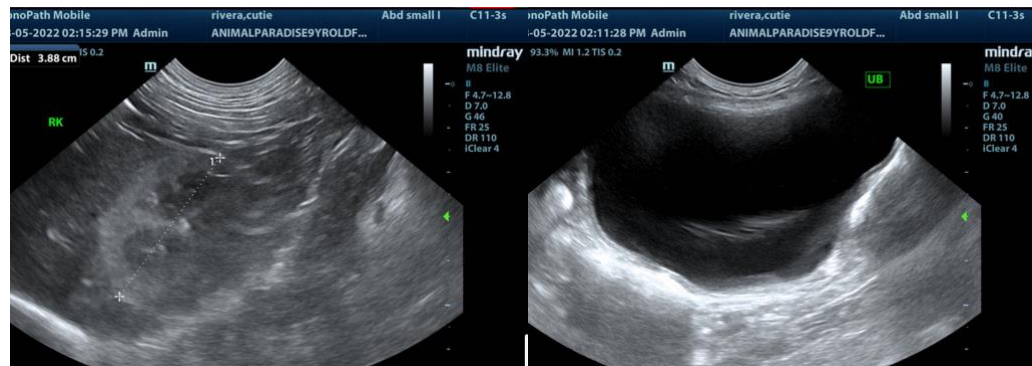
Dr. Hellwarth

INVOICE

16717

DATE

8/6/22



The information and recommendations provided are based on the images presented by the referring veterinarian. No evaluation can be communicated regarding pathology that was not visible in the image/video clips provided.

Thank you for this referral. If the clinical or image interpretation does not parallel your findings or if I can be of any further assistance please contact me.

Eric Lindquist, DMV, DABVP, Cert. IVUSS, CEO of SonoPath.com
info@SonoPath.com

CANINE HYPERCALCEMIA

<http://www.sonopath.com/CanineHypercalcemia>

Description: Hypercalcemia is defined as either a persistently elevated total calcium serum (> 12 mg/dl) or ionized calcium (> 1.45 mmol/l) concentration. Clinical signs are often absent with mild hypercalcemia (< 13 mg/dl). In fact, hypercalcemia is often only discovered when serum biochemistry is done for unrelated reasons. Clinical signs are usually mild when the serum calcium concentration is less than 14 mg/dl; however, signs become more readily apparent when the concentration exceeds 15 mg/dl. Life-threatening cardiac arrhythmias can develop when the serum calcium exceeds 18 mg/dl.

Common etiologies of hypercalcemia include humoral hypercalcemia of malignancy (HHM), hypoadrenocorticism, chronic kidney disease (CKD), hypervitaminosis D, and primary hyperparathyroidism. Less common etiologies include bone neoplasia, osteomyelitis, hypertrophic osteodystrophy, granulomatous disease, calcium supplementation, and oral phosphate binders.

Clinical Signs: Common clinical signs include polyuria, polydipsia, lethargy, inappetence, and weakness. With chronic hypercalcemia, calcium oxalate and calcium phosphate uroliths can form, resulting in clinical signs suggestive of lower urinary tract disease. Systemic signs of illness are suggestive of HHM.



PATIENT

Cutie Rivera

SPECIES

Canine

BREED

Shih Tzu

SEX

Spayed Female

AGE

9 Years

WEIGHT

16.8 Pounds

INTERPRETED BY

Eric Lindquist, DMV
DABVP, Cert. IVUSS

IMAGING PERFORMED BY

Kelly Vazquez

HOSPITAL NAME

Animal Paradise
Hospital

REFERRING VET

Dr. Hellwarth

INVOICE

16717

DATE

8/6/22

Diagnostics: One important etiology of hypercalcemia is laboratory error; therefore, hypercalcemia should always be confirmed before embarking on any further diagnostic evaluation. Results of a CBC, serum biochemistry panel, and urinalysis, in conjunction with a patient history and findings from a physical examination, can often provide enough information to arrive at a diagnosis. The appendicular skeleton, peripheral lymph nodes, abdominal cavity, and rectum should all be carefully palpated for masses, lymphadenopathy, hepatomegaly, splenomegaly, and/or pain in the long bones. The following diagnostic tests are helpful for identifying an underlying malignancy: thoracic and abdominal radiographs; abdominal ultrasound; cytological evaluation of aspirates of the liver, spleen, lymph nodes, and bone marrow; determination of serum ionized calcium, parathyroid hormone (PTH), and parathyroid hormone-related protein concentration (PTHrP); and ultrasound of the neck. Ascertaining the concentrations of serum ionized calcium, PTH, and PTHrP helps differentiate primary hyperparathyroidism from HHM. The finding of one or more enlarged parathyroid glands upon conducting an ultrasound of the neck supports a diagnosis of primary hyperparathyroidism.

Hypoadrenocorticism-induced hypercalcemia usually occurs in conjunction with hyponatremia, hyperkalemia, and prerenal azotemia. With HHM and primary hyperparathyroidism, serum phosphorus concentration is often in the low to low-normal reference range. If the serum phosphorus concentration is high but kidney function is normal, hypervitaminosis D or osteolysis should be suspected.

It can be difficult to determine whether kidney failure is primary or secondary to hypercalcemia when hyperphosphatemia and hypercalcemia coexist with azotemia. Serum ionized calcium concentrations are typically normal or decreased in cases of renal failure and increased in cases of hypercalcemia caused by other disorders.

Sternal and hilar lymphadenopathy is common with lymphoma-induced hypercalcemia and can be readily identified on thoracic radiographs. In cases of multiple myeloma, discrete lytic lesions in the vertebrae or long bones, hyperproteinemia, proteinuria, and plasma cell infiltration in the bone marrow may be present. Cytological evaluation of the peripheral lymph nodes, bone marrow, and spleen can be helpful in identifying lymphoma.

Increased serum ionized calcium concentrations, detectable serum PTHrP concentrations, and non-detectable serum PTH concentrations are all diagnostic for HHM. Lymphoma is the most common etiology of HHM, but other tumors, such as apocrine gland adenocarcinoma and various carcinomas (e.g. mammary gland, squamous cell, bronchogenic), can all give rise to hypercalcemia. Increased serum ionized calcium, normal to increased serum PTH, and non-detectable PTHrP concentrations are diagnostic of primary hyperparathyroidism.

Differentials for Hypercalcemia: "HARD IONS"



PATIENT

Hyperparathyroid

Cutie Rivera

Addison's

SPECIES

Canine

Renal

D-toxicity

Idiopathic

BREED

Shih Tzu

Osteolytic

Neoplastic

SEX

Spurious

Spayed Female

PTH tumor: Elevated total and ionized Ca, low PTHrP, and normal/high PTH. Keeshonds, German Shepherds, and Golden Retrievers are all predisposed.

AGE

9 Years

Addison's disease: Elevated total and normal ionized Ca, elevated BUN, hypoalbuminemia and hyperkalemia.

WEIGHT

16.8 Pounds

Renal failure: Elevated to normal total Ca, low ionized Ca, low PTHrP, elevated PTH, azotemia, and low urine specific gravity.

Vitamin D toxicity: Elevated total and ionized Ca, low PTHrP, and normal/low PTH.

INTERPRETED BY

Eric Lindquist, DMV
DABVP, Cert. IVUSS

Hypercalcemia of malignancy (HBM): Elevated total and ionized Ca, high PTHrP, and low PTH.

Granulomatous disease: Elevated total and ionized Ca, low PTHrP, and low PTH.

Renal failure: Elevated to normal total Ca, low ionized Ca, low PTHrP, elevated PTH, azotemia, and low urine specific gravity.

IMAGING PERFORMED BY

Kelly Vazquez

Treatment: Therapies for hypercalcemia are aimed at correcting the underlying etiology; however, because prolonged hypercalcemia can result in kidney damage, the use of fluid therapy, furosemide, and possibly prednisone is indicated in all cases to reduce serum calcium levels. Suggested dosages include saline (0.9% 120-180 ml/kg day IV), furosemide (1-4 mg/kg PO TID), and prednisone (0.25 mg/kg PO Q24hr).

HOSPITAL NAME

Animal Paradise
Hospital

REFERRING VET

Dr. Hellwarth

References:

INVOICE

16717

Chew DJ, Schenck PA, Jaeger JQ. Clinical disorders of hypercalcemia and hypocalcemia in dogs and cats. Proceedings from the American College of Veterinary Internal Medicine, Charlotte, NC, June 4-7, 2003.

Feldman EC. Disorders of the parathyroid glands. In: Ettinger SJ, Feldman EC, ed. *Textbook of Veterinary Internal Medicine, 7th ed.* St. Louis, MO: Saunders Elsevier; 2010:1722-50.

DATE

8/6/22



PATIENT

Cutie Rivera

Peterson ME. Hypercalcemia in dogs & cats: differential diagnosis & treatment. Proceedings from the Western Veterinary Conference, Las Vegas, NV, February 19-23, 2012.

SPECIES

Canine

BREED

Shih Tzu

SEX

Spayed Female

AGE

9 Years

WEIGHT

16.8 Pounds

INTERPRETED BY

Eric Lindquist, DMV
DABVP, Cert. IVUSS

**IMAGING
PERFORMED BY**

Kelly Vazquez

HOSPITAL NAME

Animal Paradise
Hospital

REFERRING VET

Dr. Hellwarth

INVOICE

16717

DATE

8/6/22