



PATIENT PRESENTING CLINICAL SIGNS

Trigger Ables

4 day history of V/D/anorexia yesterday, febrile per client (105.6), sent home with Sucralfate and Cerenia yesterday. Presented recumbent and non-ambulatory today. Is up to date on lepto vaccines. Reported multiple episodes of vomiting and black tarry feces.

SPECIES

Canine

Abnormal PE/Chem/CBC/UA Results: Mildly febrile yesterday (102.7), no fever today (100.8 F). PE-NAF. CBC: WBC= 37.3 (4.9-17.6), Neut= 34 K (3-13), Mono= 1.5 (0.13-1.15), otherwise WNL (stress leukogram) Chem: SDMA= 38 (0-14), Creat= 4.2 (0.5-1.5), BUN= 63 (9-31), pHOS= 7.0 (2.5-6.1), Albumin= 2.0 (2.7-3.9), Glob= 4.5 (2.4-4.0), A:G ratio= 0.4 (0.7-1.5), AST= 113 (16-55), ALP= 199 (5-160), tBili= 0.4 (0-0.3), unconjBili= 0.3 (0-0.2), Chol= 498 (131-345), CK= 505 (10-200), otherwise WNL.

BREED

Labrador Retriever

T4=<0.4 U/A: U.S.G.= 1.027 , pH= 5.5, Protein= 2+, Blood 2+, Bili= 1+, WBC= 2-5/hpf, RBC= 20-30/hpf, no bacteria/crystals, occasional fine granular casts HW/L/E/A- All negative snap spec cPL= negative Lepto PCR in process

SEX

Neutered Male

AGE

9 Years

WEIGHT

85 Pounds

ULTRASONOGRAPHIC EXAMINATION OF THE ABDOMEN

Urinary System

The **urinary bladder**, trigone, and pelvic urethra presented normal thicknesses and normal tone. The ureters were not visible which is normal. No uroliths or sediment were visualized and anechoic urine was present. No evidence of inflammatory or neoplastic changes were noted. Ureteral papillae were normal.

INTERPRETED BY

The residual prostate measured 5.0 mm.

Eric Lindquist, DMV

The **kidneys** revealed largely normal size and structure, corticomedullary definition and ratio (cortex 1/3 of medulla) were essentially maintained with some age-related loss of curvilinear patterns regarding the capsule and C/M junction. The cortices presented largely uniform texture with some increased echogenicity expected for his age patient. Medullary structure differed distinctly from that of the cortex and no evidence of pelvic dilation was present. The left kidney measured 7.95 cm. The right kidney measured 8.04 cm.

DABVP, Cert. IVUSS

IMAGING PERFORMED BY

Desen Ertunc

Adrenal Glands

HOSPITAL NAME

Humboldt VMG

Both **adrenal glands** were visualized and recognized as having normal shape, size, position and echogenicity for this breed. The phrenic vasculature, glandular echogenicity and detail were unremarkable. Capsule, cortex, and medullary definition were normal for this age patient. The left adrenal gland measured 1.72 cm x 0.47 cm. The right adrenal gland measured 1.0 cm at the cranial pole and 0.74 cm at the caudal pole.

REFERRING VET

Dr. Jennifer Renner

Spleen

INVOICE

44466

The **spleen** presented a smooth homogeneous parenchyma hyperechoic to liver and renal cortical parenchyma. The capsule was smooth without noticeable expansion or deviation from within the spleen or adjacent pathology. The splenic vasculature demonstrated normal volume without signs of congestion or thrombosis. No sonographic evidence of acute or chronic inflammatory, neoplastic, or infarctual changes were noted.

DATE

8/4/23



PATIENT *Liver*

Trigger Ables The **liver** revealed coarse architecture and increased portal markings. Mild amount of remodeling, consistent with inflammatory hepatopathy. Increased gallbladder echogenicity noted.

SPECIES *Gastrointestinal*

Canine

Examination of the **gastrointestinal tract** revealed a stomach and intestine free of stasis, of normal wall thickness, acceptable curvilinear mural detail, and peristaltic activity. Small and large intestine demonstrated normal luminal chyme and stool consistency respectively. No obstructive or overt infiltrative disease was noted. No associated abnormal lymphatic activity was noted.

BREED

Labrador Retriever

SEX

Neutered Male

Pancreas

The base and limbs of the **pancreas** were observed to be largely isoechoic to surrounding omental fat. Pancreatic duct and capsular contour were acceptably normal and parenchyma respected normal curvilinear patterns. No overt evidence of active inflammatory or neoplastic disease was noted.

AGE

9 Years

ULTRASONOGRAPHIC FINDINGS

WEIGHT

85 Pounds

- Structurally unremarkable kidneys, acute insult suspected such as Leptospirosis, lyme disease or similar.
- Cholangitis liver pattern

INTERPRETATION OF THE FINDINGS & FURTHER RECOMMENDATIONS

Renal biopsy would be ideal. Empirical treatment for Leptospirosis with IV Ampicillin, IV fluid support, blood pressures and urine culture all indicated.

INTERPRETED BY

Eric Lindquist, DMV

DABVP, Cert. IVUSS

IMAGING PERFORMED BY

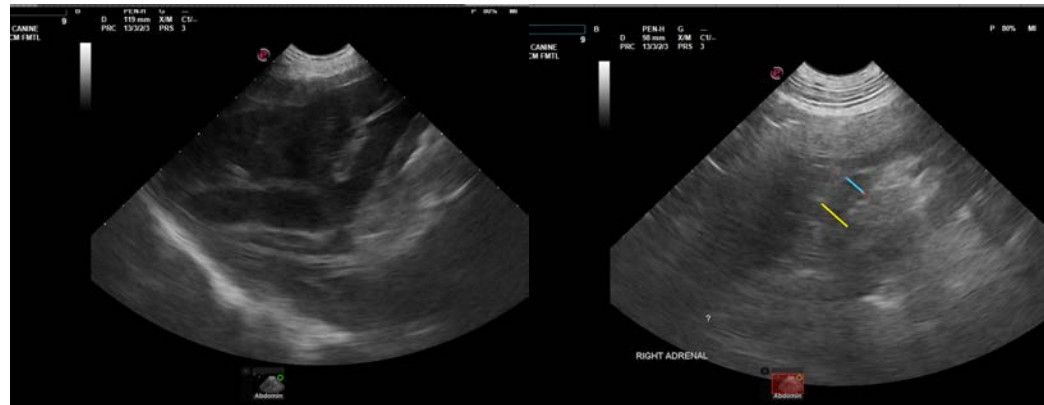Desen Ertunc

HOSPITAL NAME

Humboldt VMG

REFERRING VET

Dr. Jennifer Renner



INVOICE

44466

DATE

8/4/23



PATIENT

Trigger Ables

SPECIES

Canine

BREED

Labrador Retriever

SEX

Neutered Male

AGE

9 Years

WEIGHT

85 Pounds

INTERPRETED BY

Eric Lindquist, DMV

DABVP, Cert. IVUSS

IMAGING PERFORMED BY

Desen Ertunc

HOSPITAL NAME

Humboldt VMG

REFERRING VET

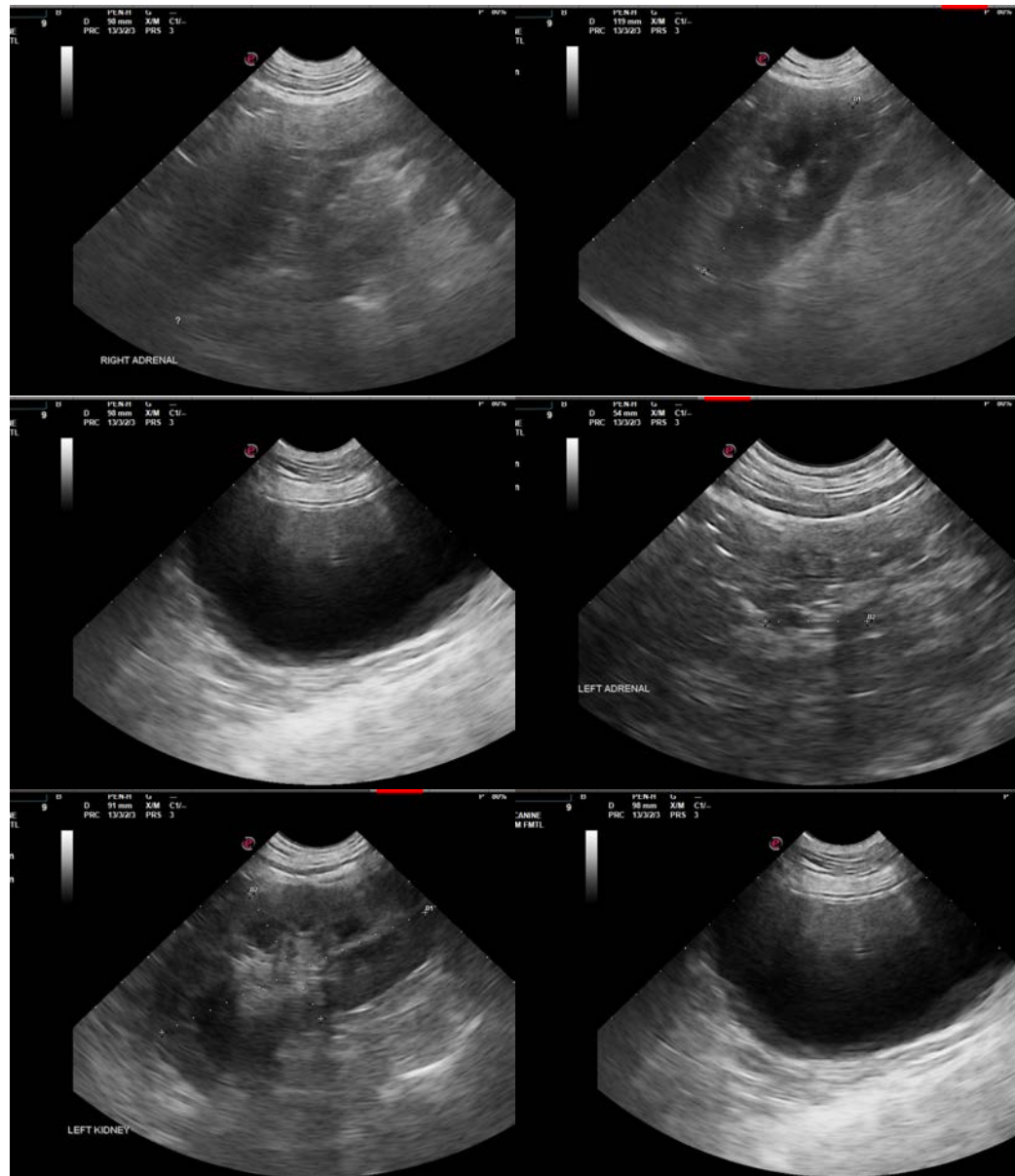
Dr. Jennifer Renner

INVOICE

44466

DATE

8/4/23



The information and recommendations provided are based on the images presented by the referring veterinarian/sonographer. No evaluation can be communicated regarding pathology that was not visible in the image/video clips provided.

Thank you for this referral. If the clinical or image interpretation does not parallel your findings or if I can be of any further assistance please contact me.

Eric Lindquist, DMV, DABVP, Cert. IVUSS, CEO of SonoPath.com

info@SonoPath.com



PATIENT

Trigger Ables

SPECIES

Canine

BREED

Labrador Retriever

SEX

Neutered Male

AGE

9 Years

WEIGHT

85 Pounds

INTERPRETED BY

Eric Lindquist, DMV

DABVP, Cert. IVUSS

IMAGING PERFORMED BY

Desen Ertunc

HOSPITAL NAME

Humboldt VMG

REFERRING VET


Dr. Jennifer Renner

INVOICE

44466

DATE

8/4/23



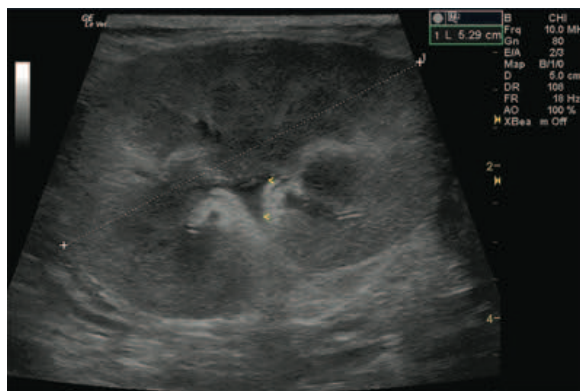The following is an applicable excerpt from the *Curbside Guide to Diagnosis & Treatment of Sonographic Disease* offered by [SonoPath.com](http://sonopath.com) Lindquist, Frank, Lobetti, and Modler.

An essential quick guide for every general practitioner and sonographer.

<https://sonopath.com/products/curbside-guide-editing-due-release-12012015>

Acute Renal Failure

<http://www.sonopath.com/ARF>



Long axis of the kidney in a cat with a renal transplant and acute renal failure. Note the generalized swelling of the kidney with loss of corticomedullary definition. The renal pelvis shows mild dilation with anechoic content (arrow heads). The renal crest and sinus are hyperechoic.

Description: Acute renal failure (ARF)—also referred to as acute kidney injury—is defined as a rapid deterioration in renal function that results in the accumulation of metabolic waste in the body. It is characterized by an impaired regulation of water and solute balances, and may be due to prerenal, postrenal, and/or primary renal causes. Prerenal azotemia reflects a reduced glomerular filtration rate (GFR), which is a consequence of renal hypoperfusion; it is not the result of structural renal damage. Immediate restoration of renal blood flow will reverse the azotemia over a period of time; however, if the hypoperfusion is severe or prolonged, or if there is prior renal dysfunction, acute primary renal failure due to ischemic acute tubular necrosis will be induced. Postrenal azotemia occurs when urine flow is obstructed or the excretory pathway is ruptured and there is subsequent urine resorption. Persistent urinary obstruction may cause irreversible renal damage. Early detection of postrenal azotemia will result in complete restoration of renal function. Acute tubular necrosis accounts for the majority of acute primary renal failure cases and is characterized by an abrupt and sustained reduction in GFR due to an ischemic or toxic renal insult. The conditions that incite ischemia are the same as those for prerenal azotemia; however, the duration of the ischemia is important. Nephrotoxins are a frequent cause of tubular necrosis. The high rates of blood flow and metabolic activity



PATIENT

in the kidneys as well as their excretory function predispose dogs and cats to the toxic effects of drugs as well as endogenous or exogenous toxins.

Trigger Ables

SPECIES

Canine

BREED

Labrador Retriever

SEX

Neutered Male

AGE

9 Years

WEIGHT

85 Pounds

INTERPRETED BY

Eric Lindquist, DMV

DABVP, Cert. IVUSS

IMAGING PERFORMED BY

Desen Ertunc

HOSPITAL NAME

Humboldt VMG

REFERRING VET

Dr. Jennifer Renner

INVOICE

44466

DATE

8/4/23

Clinical Signs: The clinical course in acute tubular necrosis can be divided into three phases: an initiating phase, a maintenance phase, and a recovery phase. The initiating phase, which is marked by the onset of renal injury, is the period in which there is the greatest potential for preventing or reversing tubular damage and the progression to overt renal failure because it is during this period that renal cell damage develops. The challenge, however, is that the initiating phase may only become evident in retrospect as it generally lacks characteristic signs. The maintenance phase is characterized by the onset of oliguria (i.e., urine production is less than 1ml/kg/hour). The onset of this phase typically occurs during the first 24 hours, but may be delayed for up to 1 week. The duration of this phase is highly variable, but usually persists for up to 2 weeks. It is characterized by: fluid and electrolyte imbalances, including an alteration in hydration; hyponatremia; hyperkalemia; high anion gap metabolic acidosis; hypocalcemia; hyperphosphatemia; and azotemia. Clinical signs include gastrointestinal, hematological, and neurological manifestations of renal failure. The recovery phase commences when the GFR increases, which consequently slows down and reverses the azotemia. There is a progressive increase in urine volume, and although the tubular function begins to improve, it nevertheless remains impaired. Diuresis persists because of the diminished ability of the tubules to reabsorb sodium and respond to vasopressin. Clinical manifestations observed in the maintenance phase persist into the recovery phase. In some patients, infections and/or gastrointestinal bleeding may occur. Sites of infection include the respiratory tract, operative sites, and the urinary tract. Septicemia may also occur and is sometimes the result of intravenous and urinary indwelling catheters.

Diagnostics: Extraordinary disorders that produce prerenal azotemia are associated with concentrated, hypersthenuric urine, which contains a relatively low concentration of sodium and high concentration of creatinine. ARF is typically characterized by enlarged or swollen kidneys, elevated hematocrit, and azotemia. Urine is isosthenuric or minimally concentrated, and contains high concentrations of creatinine. Proteinuria or glycosuria may also accompany this condition. The sediment will show casts and RTE cells. Complete anuria is usually associated with postrenal azotemia. Features that are typical for acute tubular necrosis include: anuria in the absence of a urinary tract obstruction or rupture; severe proteinuria; significant hematuria with red cell casts; and prolonged oliguria. In these cases, a diagnostic renal biopsy is indicated.

Treatment: Most patients with ARF are volume depleted. Fluid therapy is indicated to correct dehydration, which will restore adequate renal perfusion and may prevent further renal damage. If the etiology was prerenal in origin, then urine volume will increase. In the maintenance phase, fluid therapy should be directed toward maintaining fluid balance and preventing both overhydration and dehydration. In cases of renal disease it is important that only maintenance needs and ongoing losses are attended to as overhydration can develop if there is reduced renal function. Insensible losses are calculated at 20 ml/kg/day. Aggressive fluid therapy during the recovery phase may perpetuate polyuria. As the urine volume stabilizes, the volume of fluid administered should be reduced correspondingly. Because dehydration may occur during this phase, one should monitor body weight and clinically assess the hydration status as fluid therapy is being reduced. Oliguric patients who are unresponsive to fluid volume replacement can be treated with mannitol, furosemide, and/or dopamine in an attempt to increase GFR and



PATIENT

Trigger Ables

SPECIES

Canine

BREED

Labrador Retriever

SEX

Neutered Male

AGE

9 Years

WEIGHT

85 Pounds

INTERPRETED BY

Eric Lindquist, DMV

DABVP, Cert. IVUSS

IMAGING PERFORMED BY

Desen Ertunc

HOSPITAL NAME

Humboldt VMG

REFERRING VET

Dr. Jennifer Renner

INVOICE

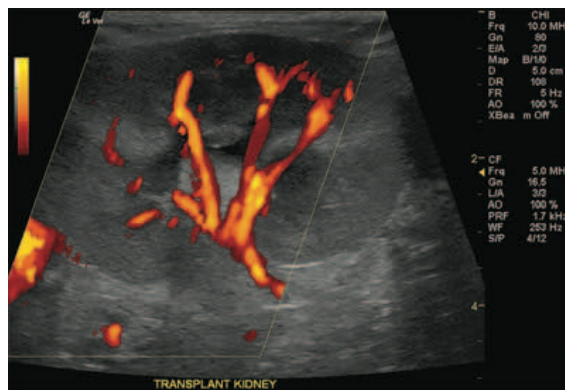44466

DATE

8/4/23

urine volume. Hyperkalemia is commonly associated with the maintenance phase of ARF. Concentrations greater than 6 mmol/l may require treatment with sodium bicarbonate, dextrose, insulin and/or calcium gluconate. Hemodialysis should be considered in patients with severe, persistent uremia, acidosis, or hyperkalemia. It may also be used to treat overhydration and hasten the elimination of nephrotoxins.

Conclusion: Because ARF is frequently iatrogenic and associated with nephrotoxic drugs or inadequate fluid therapy, prevention is the best therapy.



Long axis of the kidney of the same cat as in the previous title image. Note the non-uniform power Doppler signal distribution with significant hypovascularity of the cranial pole compatible with regional infarction and transplant failure.

References:

Acierno MJ, Maeckelbergh V. Continuous renal replacement therapy. *Compend Contin Educ Vet* 2008;30:264-72.

Grauer GF. Early detection of renal damage and disease in dogs and cats. *Vet Clin North Am Small Anim Pract* 2005;35:581-96.

Labato MA. Strategies for management of acute renal failure. *Vet Clin North Am Small Anim Pract* 2001;31:1265-87.

Ross L. Acute kidney injury in dogs and cats. *Vet Clin North Am Small Anim Pract* 2011;41:1-14.