



PATIENT

PRESENTING CLINICAL SIGNS

Sam Davis

History: Vomiting, Diarrhea, tense distended stomach
Abnormal PE/Chem/CBC/UA Results: CBC and Biochemistry unremarkable

SPECIES

Canine

ULTRASONOGRAPHIC EXAMINATION OF THE ABDOMEN

Urinary System

BREED

German Shepherd

The **urinary bladder**, trigone, and pelvic urethra presented normal thicknesses and normal tone. The ureters were not visible which is normal. No uroliths or sediment were visualized and anechoic urine was present. No evidence of inflammatory or neoplastic changes was noted. Ureteral papillae were normal.

SEX

Spayed female

The **kidneys** revealed normal size and structure, corticomedullary definition and ratio for this age. The cortices presented largely uniform texture with normal echogenic relationship to liver and spleen. Medullary structure differed distinctly from the cortex and no evidence of pelvic dilation was present. The capsules were acceptably uniform without significant irregularities. Slight pinpoint mineralization was noted. The left kidney measured 6.6 cm and the right kidney measured 6.6 cm.

AGE

7 years

WEIGHT

36 kg

Adrenal Glands

Both **adrenal glands** were visualized and recognized as having normal shape, size, position and echogenicity for this breed. The phrenic vasculature, glandular echogenicity and detail were unremarkable. Capsule, cortex, and medullary definition were normal for this age patient. The right adrenal gland measured 0.67 cm at the cranial pole and 0.6 cm at the caudal pole. The left adrenal gland measured 0.42 cm at the cranial pole and 0.4 cm at the caudal pole.

INTERPRETED BY

Eric Lindquist, DMV
DABVP, Cert. IVUSS

IMAGING PERFORMED BY

Dr. Gira

Spleen

The **spleen** was enlarged and uniform. This is consistent with breed variant.

HOSPITAL NAME

Sabadilla AC

Liver

The **liver** images submitted revealed subjectively normal liver size, contour, and structure. Parenchymal echogenicity was naturally coarse and hypoechoic to the spleen. Vascular and biliary tracts were of normal volume with no evidence of congestion. The gallbladder presented acceptably thin walls with primarily anechoic content. The cystic and common bile ducts were normal. No pathological hepatic lymphadenopathy was evident. No overt structural evidence of inflammatory, infiltrative or regenerative pathology was evident.

REFERRING VET

Dr. Pak

INVOICE

46453

Gastrointestinal

Examination of the **gastrointestinal tract** revealed a stomach and intestine free of stasis, of normal wall thickness, acceptable curvilinear mural detail, and peristaltic activity. Small and large intestine

DATE

8/4/23



PATIENT

demonstrated normal luminal chyme and stool consistency respectively. Superimposition of the small intestine upon the liver was noted.

Sam Davis

SPECIES

Pancreas

Canine

The base and limbs of the **pancreas** were observed to be largely isoechoic to surrounding omental fat. Pancreatic duct and capsular contour were acceptably normal and parenchyma respected normal curvilinear patterns. No overt evidence of active inflammatory or neoplastic disease was noted.

BREED

German Shepherd

ULTRASONOGRAPHIC FINDINGS

SEX

Structurally unremarkable abdomen with German Shepherd hypersplenism, likely benign.

Spayed female

INTERPRETATION OF THE FINDINGS & FURTHER RECOMMENDATIONS

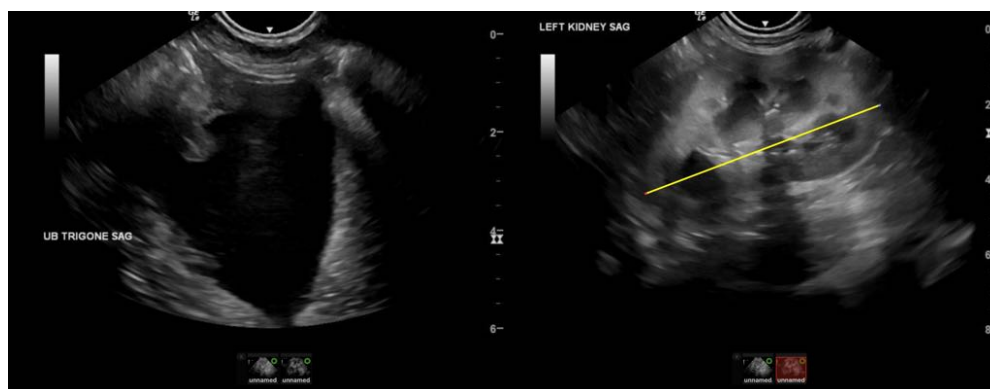
AGE

Supportive care should prove effective. Dietary indiscretion, food intolerance, structurally significant inflammatory bowel or occult parasitism and occult Addison's are all potentials.

7 years

WEIGHT

36 kg

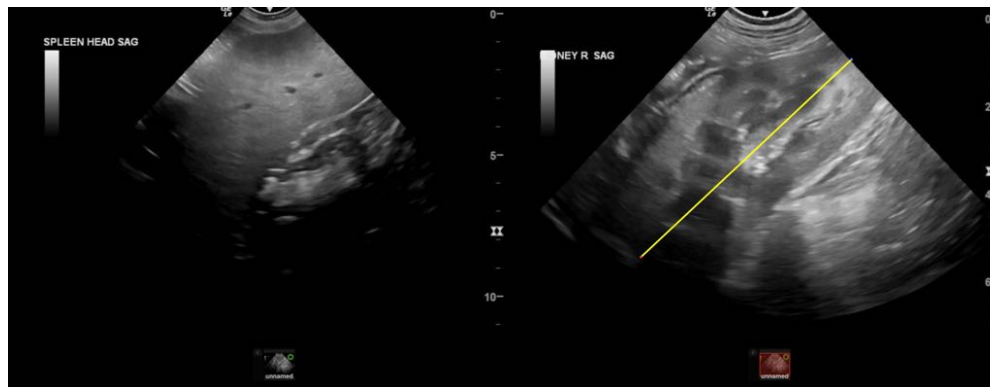


INTERPRETED BY

Eric Lindquist, DMV
DABVP, Cert. IVUSS

IMAGING PERFORMED BY

Dr. Gira



HOSPITAL NAME

Sabadilla AC

REFERRING VET

Dr. Pak

INVOICE

46453

DATE

8/4/23



PATIENT

Sam Davis

SPECIES

Canine

BREED

German Shepherd

SEX

Spayed female

AGE

7 years

WEIGHT

36 kg

INTERPRETED BY

Eric Lindquist, DMV
DABVP, Cert. IVUSS

IMAGING PERFORMED BY

Dr. Gira

HOSPITAL NAME

Sabadilla AC

REFERRING VET

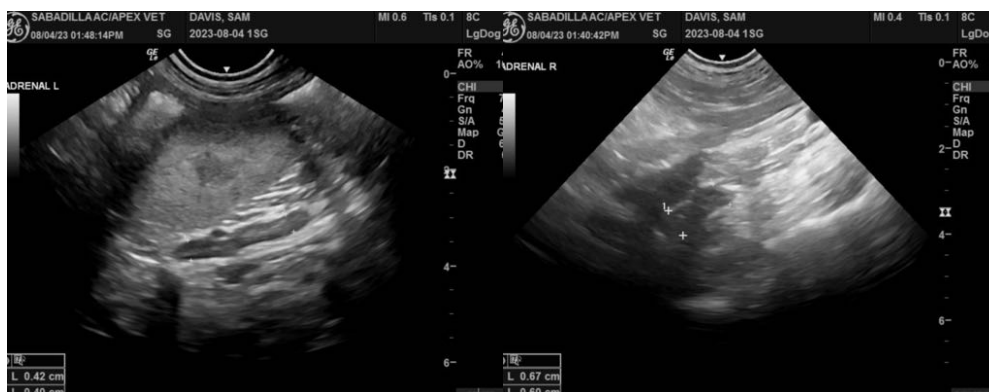
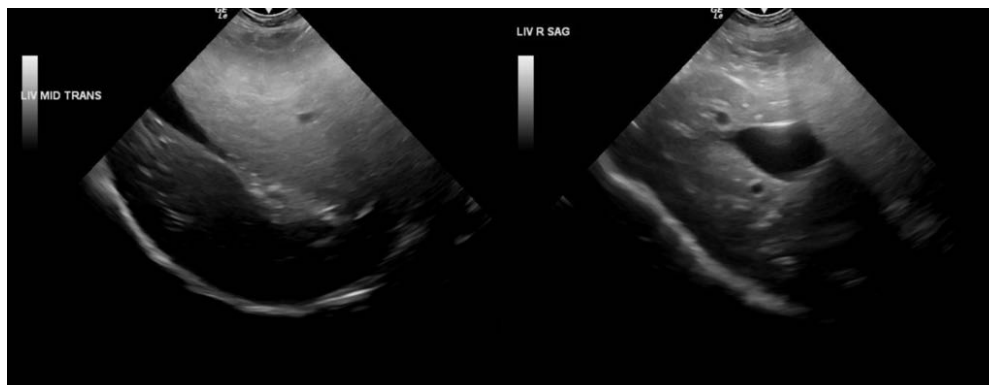
Dr. Pak

INVOICE

46453

DATE

8/4/23



The information and recommendations provided are based on the images presented by the referring veterinarian/sonographer. No evaluation can be communicated regarding pathology that was not visible in the image/video clips provided.

Thank you for this referral. If the clinical or image interpretation does not parallel your findings or if I can be of any further assistance please contact me.

Eric Lindquist, DMV, DABVP, Cert. IVUSS, CEO of SonoPath.com
info@SonoPath.com