



PATIENT

Luna Suarez

SPECIES

Canine

BREED

German Shepherd

SEX

Spayed female

AGE

3 years

WEIGHT

77.5 lbs

INTERPRETED BY

Eric Lindquist, DMV
DABVP, Cert. IVUSS

IMAGING PERFORMED BY

Heather

HOSPITAL NAME

Animal Care Center of
Flanders

REFERRING VET

Dr. Casulli

INVOICE

32151

DATE

8/4/22

PRESENTING CLINICAL SIGNS

History: over the past year has had Urinary incontinence . UTI's were frequent due to recessed vulva but has since stopped since o started wiping her after she urinates. r/o structural abnormality / bladder storage disorder / Urethral Disorder had proin and trazadone this am had series of hip and knee radiology today due to back leg tremors so was sedated with 0.7mL Torb and 0.3mL Dexdomitor IV
Abnormal PE/Chem/CBC/UA Results: 7/24/22 Re

ULTRASONOGRAPHIC EXAMINATION OF THE ABDOMEN

Urinary System

The **urinary bladder** revealed a minor amount of gas reverberation. This is suggestive for emphysematous cystitis.

The **kidneys** revealed normal size and structure, corticomedullary definition and ratio for this age. The cortices presented largely uniform texture with normal echogenic relationship to liver and spleen. Medullary structure differed distinctly from the cortex and no evidence of pelvic dilation was present. The capsules were acceptably uniform without significant irregularities. The left kidney measured 6.2 cm. The right kidney measured 6.0 cm.

Adrenal Glands

The left **adrenal gland** was visualized and recognized as having normal shape, size, position and echogenicity for this breed. The phrenic vasculature, glandular echogenicity and detail were unremarkable. Capsule, cortex, and medullary definition were normal for this age patient. The left adrenal gland measured 0.5 cm. The right adrenal gland was not visualized.

Spleen

The **spleen** presented a smooth homogeneous parenchyma hyperechoic to liver and renal cortical parenchyma. The capsule was smooth without noticeable expansion or deviation from within the spleen or adjacent pathology. The splenic vasculature demonstrated normal volume without signs of congestion or thrombosis. No sonographic evidence of acute or chronic inflammatory, neoplastic, or infarctual changes was noted.

Liver

The **liver** images submitted revealed subjectively normal liver size, contour, and structure. Parenchymal echogenicity was naturally coarse and hypoechoic to the spleen. Vascular and biliary tracts were of normal volume with no evidence of congestion. The gallbladder presented acceptably thin walls with primarily anechoic content. The cystic and common bile ducts were normal. No pathological hepatic lymphadenopathy was evident. No overt structural evidence of inflammatory, infiltrative or regenerative pathology was evident.



PATIENT

Gastrointestinal

Luna Suarez

Examination of the **gastrointestinal tract** revealed a stomach and intestine free of stasis, of normal wall thickness, acceptable curvilinear mural detail, and peristaltic activity. Small and large intestine demonstrated normal luminal chyme and stool consistency respectively. No obstructive or overt infiltrative disease was noted. No associated abnormal lymphatic activity was noted.

SPECIES

Canine

BREED

German Shepherd

Pancreas

The base and limbs of the **pancreas** were observed to be largely isoechoic to surrounding omental fat. Pancreatic duct and capsular contour were acceptably normal and parenchyma respected normal curvilinear patterns. No overt evidence of active inflammatory or neoplastic disease was noted.

SEX

Spayed female

ULTRASONOGRAPHIC FINDINGS

Structurally unremarkable abdomen with gas reverberation within the bladder. Concern for underlying anaerobic infection.

AGE

3 years

INTERPRETATION OF THE FINDINGS & FURTHER RECOMMENDATIONS

WEIGHT

77.5 lbs

Aerobic and anaerobic culture is warranted. There was no evidence of ectopic ureters. Examination of the vaginal vestibule for predisposing issues is also indicated.

INTERPRETED BY

Eric Lindquist, DMV
DABVP, Cert. IVUSS

Canine Chronic UTI Protocol

I recommend **Enrofloxacin** (5-10 mg/kg SID PO) (In patients > 1 year of age) in late pm after urination to maximize urinary concentrations overnight. This assumes that culture supports this use. Repeat **culture** at 3-4 weeks and continue treatment at least 7-10 days post negative urinary sediment and negative culture. *Note: Negative culture does not necessarily mean lack of UTI.* Other favorite antibiotics for chronic UTI include third generation Cefa (Ceftiafur or similar s.i.d. injectable) or Clavamox. If suspicion of occult urinary incontinence is present then **phenylpropanolamine (PPA)** (1-2 mg/kg BID) can be employed long term to enhance urethral tone.

IMAGING PERFORMED BY

Heather

HOSPITAL NAME

Animal Care Center of
Flanders

REFERRING VET

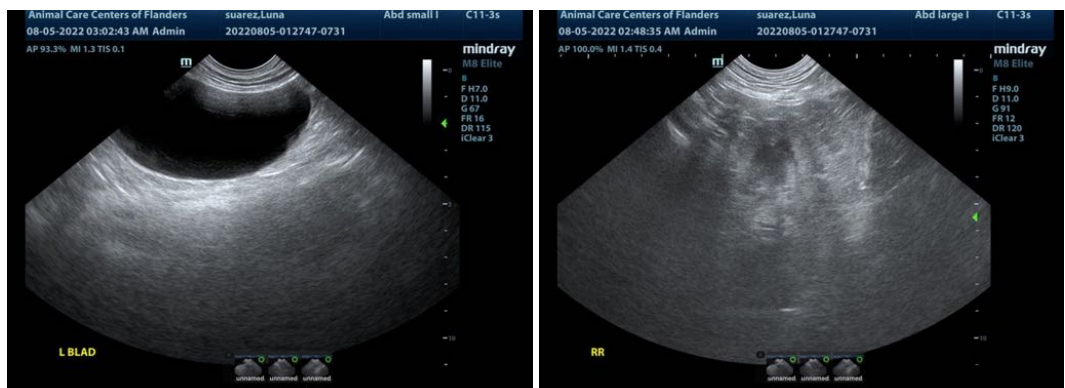
Dr. Casulli

INVOICE

32151

DATE

8/4/22





PATIENT

Luna Suarez

SPECIES

Canine

BREED

German Shepherd

SEX

Spayed female

AGE

3 years

WEIGHT

77.5 lbs

INTERPRETED BY

Eric Lindquist, DMV
DABVP, Cert. IVUSS

IMAGING PERFORMED BY

Heather

HOSPITAL NAME

Animal Care Center of
Flanders

REFERRING VET

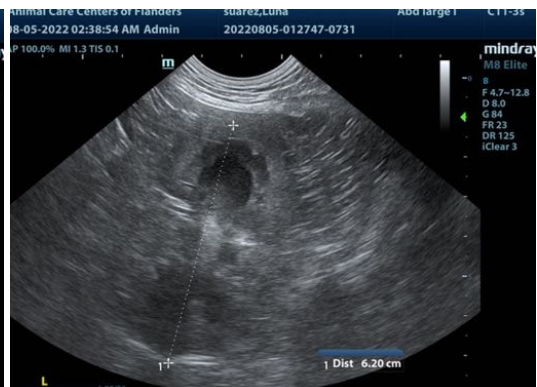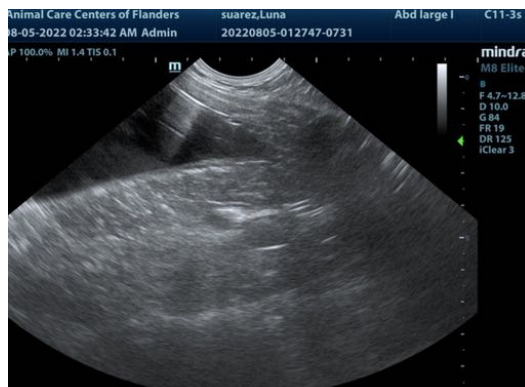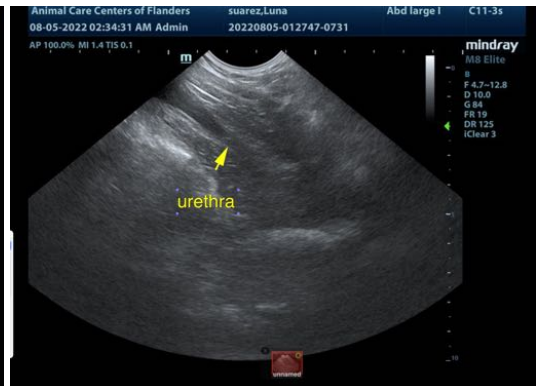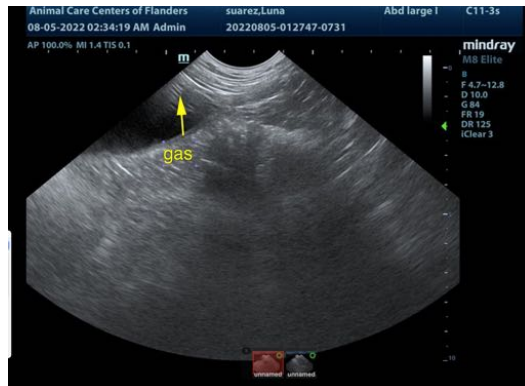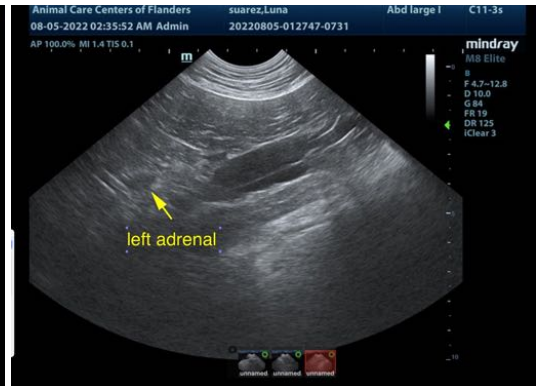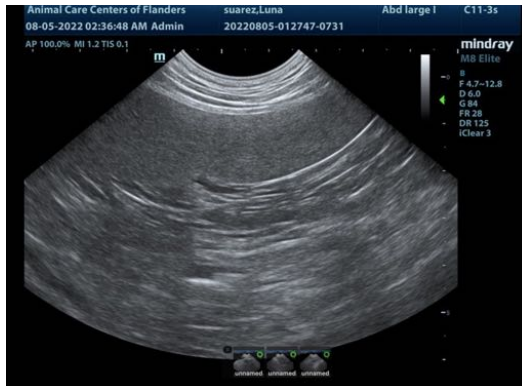Dr. Casulli

INVOICE

32151

DATE

8/4/22



The information and recommendations provided are based on the images presented by the referring veterinarian/sonographer. No evaluation can be communicated regarding pathology that was not visible in the image/video clips provided.

Thank you for this referral. If the clinical or image interpretation does not parallel your findings or if I can be of any further assistance please contact me.

Eric Lindquist, DMV, DABVP, Cert. IVUSS, CEO of SonoPath.com
info@SonoPath.com