

**PATIENT**

Josie Alderete

**SPECIES**

Canine

**BREED**

French Bulldog

**SEX**

Spayed female

**AGE**

2 years

**WEIGHT**

22 lbs

**INTERPRETED BY**Eric Lindquist, DMV  
DABVP, Cert. IVUSS**IMAGING  
PERFORMED BY**

Amy Mayhew LVT

**HOSPITAL NAME**

SVS Imaging Michigan

**REFERRING VET**

Union Lake VH

**INVOICE**

32161

**DATE**

8/4/22

**PRESENTING CLINICAL SIGNS**

History: episodic seizure activity and confusion

Abnormal PE/Chem/CBC/UA Results: abnormal bile acids on blood profile ACTH stim normal but resting cortisol is low \*\*Please see attached labs

**ULTRASONOGRAPHIC EXAMINATION OF THE ABDOMEN****Urinary System**

The **urinary bladder**, trigone, and pelvic urethra presented normal thicknesses and normal tone. The ureters were not visible which is normal. No uroliths or sediment were visualized and anechoic urine was present. No evidence of inflammatory or neoplastic changes was noted. Ureteral papillae were normal.

The **kidneys** revealed normal size and structure, corticomedullary definition and ratio for this age. The cortices presented largely uniform texture with normal echogenic relationship to liver and spleen. Medullary structure differed distinctly from the cortex and no evidence of pelvic dilation was present. The capsules were acceptably uniform without significant irregularities. The right kidney measured 4.63 cm. The left kidney measured 4.25 cm.

**Adrenal Glands**

Both **adrenal glands** were visualized and recognized as having normal shape, size, position and echogenicity for this breed. The phrenic vasculature, glandular echogenicity and detail were unremarkable. Capsule, cortex, and medullary definition were normal for this age patient. The left adrenal gland measured 0.43 cm at the cranial pole and 0.56 cm at the caudal pole. The right adrenal gland measured 0.47 cm at the caudal pole and 0.59 cm at the cranial pole.

**Spleen**

The **spleen** presented a smooth homogeneous parenchyma hyperechoic to liver and renal cortical parenchyma. The capsule was smooth without noticeable expansion or deviation from within the spleen or adjacent pathology. The splenic vasculature demonstrated normal volume without signs of congestion or thrombosis. No sonographic evidence of acute or chronic inflammatory, neoplastic, or infarctual changes was noted.

**Liver**

The **liver** images submitted revealed subjectively normal liver size, contour, and structure. Parenchymal echogenicity was naturally coarse and hypoechoic to the spleen. The portal vein and vena cava ratio was 1:1 at 0.67 cm each with normal branching of the portal vein noted. There was no evidence of extrahepatic or intrahepatic shunting. The gallbladder presented acceptably thin walls with primarily anechoic content. The cystic and common bile ducts were normal. No pathological hepatic lymphadenopathy was evident. No overt structural evidence of inflammatory, infiltrative or regenerative pathology was evident.

IMAGING PERFORMED BY

SVS Mobile Imaging MI 734-637-7711  
svsimagingmi@gmail.com



**PATIENT**

Josie Alderete

**SPECIES**

Canine

**BREED**

French Bulldog

**SEX**

Spayed female

**AGE**

2 years

**WEIGHT**

22 lbs

**INTERPRETED BY**

Eric Lindquist, DMV  
DABVP, Cert. IVUSS

**IMAGING PERFORMED BY**

Amy Mayhew LVT

**HOSPITAL NAME**

SVS Imaging Michigan

**REFERRING VET**

Union Lake VH

**INVOICE**

32161

**DATE**

8/4/22

**Gastrointestinal**

Examination of the **gastrointestinal tract** revealed a stomach and intestine free of stasis, of normal wall thickness, acceptable curvilinear mural detail, and peristaltic activity. Small and large intestine demonstrated normal luminal chyme and stool consistency respectively. No obstructive or overt infiltrative disease was noted. No associated abnormal lymphatic activity was noted.

**Pancreas**

The base and limbs of the **pancreas** were observed to be largely isoechoic to surrounding omental fat. Pancreatic duct and capsular contour were acceptably normal and parenchyma respected normal curvilinear patterns. No overt evidence of active inflammatory or neoplastic disease was noted.

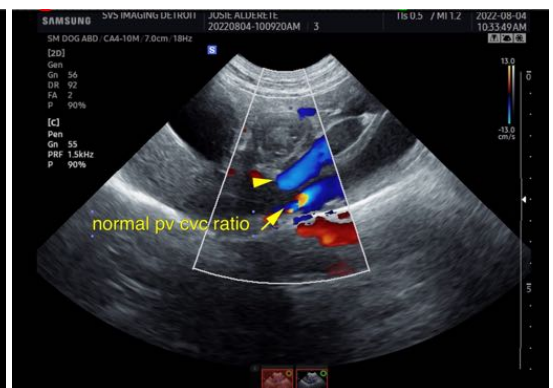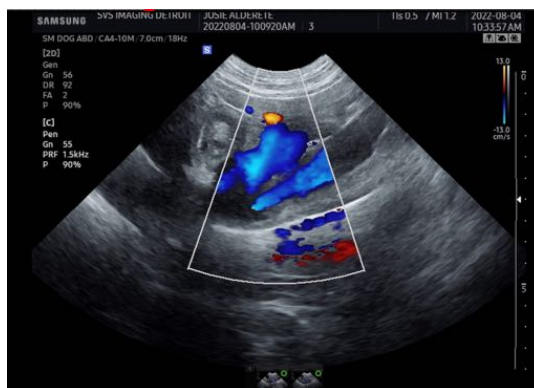
**ULTRASONOGRAPHIC FINDINGS**

Normal liver, no evidence of shunting.

**INTERPRETATION OF THE FINDINGS & FURTHER RECOMMENDATIONS**

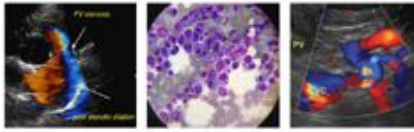
There was spurious elevation of bile acids. Idiopathic causes or spontaneous gallbladder contraction or possible portal hypoplasia are all potentials in this patient. The following protocol could be considered; however, CT of the skull with contrast or MRI would be appropriate.

**Royal Canin Hepatic Support diet or Hills L/D, Metronidazole (7.5 mg/kg PO bid)** over the next 14 days, **Lactulose (Oral: 3.1-3.7 g/5 ml lactulose in a syrup base)** long term to target 2-3 soft stools/day, with a **high-quality protein supplement** of minor amount of **yogurt or cheddar cheese**. Monitor bile acids, with attention paid to dropping albumin, BUN or cholesterol. SAME and nutraceuticals as needed. **Ursodiol (10-15 mg/kg p.o. q24h)** can be considered as hepatoprotectant and to enhance bile flow. **Zinc** serum level keep between 200–500 ug/dl. If deficient then Tx zinc acetate 1-3 mg/kg/day. Gastrointestinal protectants are recommended if the patient is anorexic.



**IMAGING PERFORMED BY**

SVS Mobile Imaging MI 734-637-7711  
svsimagingmi@gmail.com



**PATIENT**

Josie Alderete

**SPECIES**

Canine

**BREED**

French Bulldog

**SEX**

Spayed female

**AGE**

2 years

**WEIGHT**

22 lbs

**INTERPRETED BY**

Eric Lindquist, DMV  
DABVP, Cert. IVUSS

**IMAGING PERFORMED BY**

Amy Mayhew LVT

**HOSPITAL NAME**

SVS Imaging Michigan

**REFERRING VET**

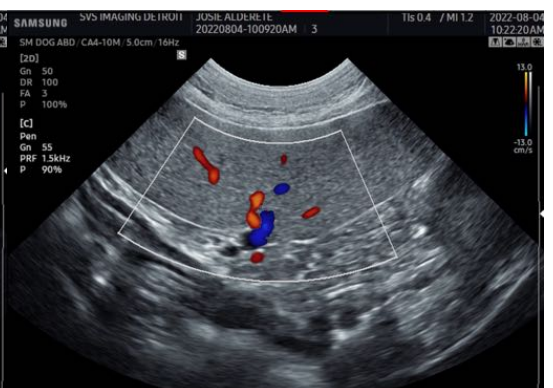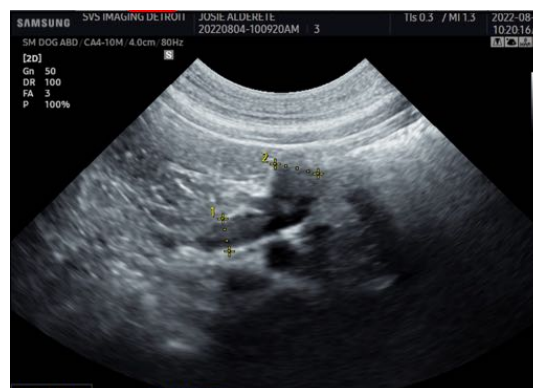
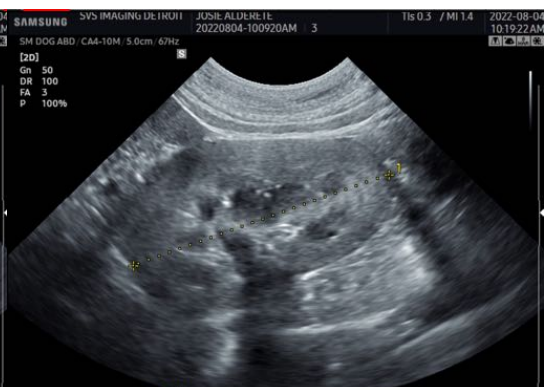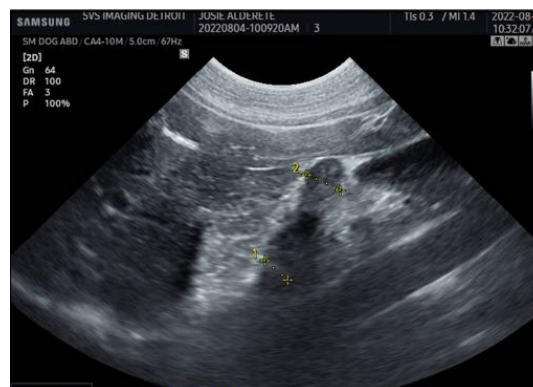
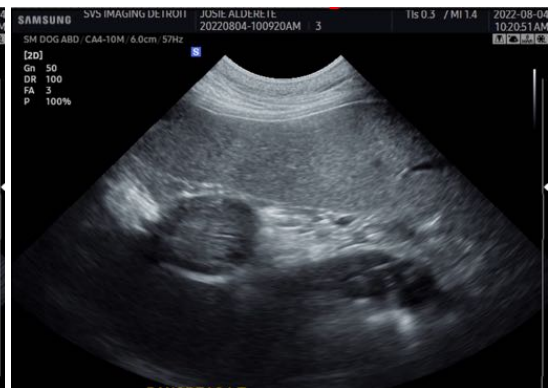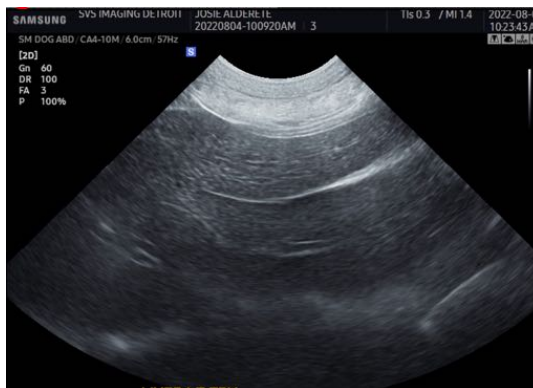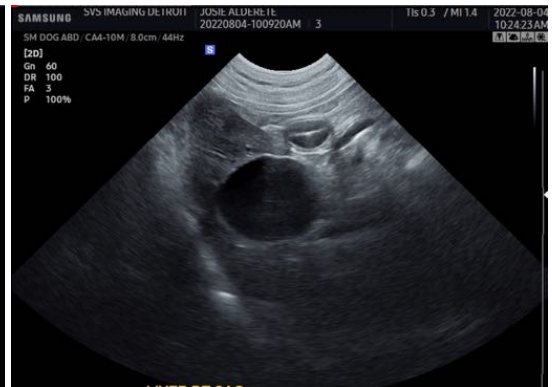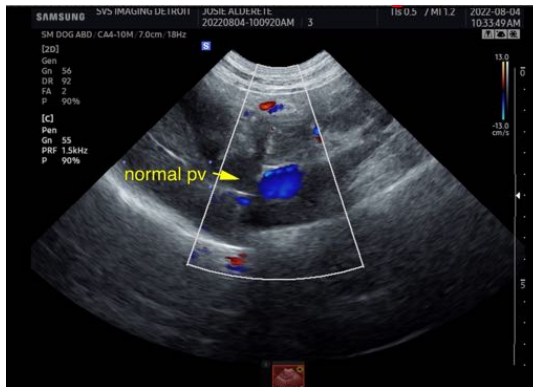
Union Lake VH

**INVOICE**

32161

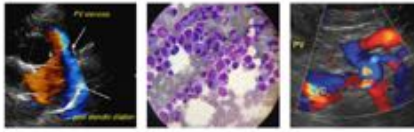
**DATE**

8/4/22



**IMAGING PERFORMED BY**

SVS Mobile Imaging MI 734-637-7711  
svsimagingmi@gmail.com



**PATIENT**

Josie Alderete

**SPECIES**

Canine

**BREED**

French Bulldog

**SEX**

Spayed female

**AGE**

2 years

**WEIGHT**

22 lbs

**INTERPRETED BY**

Eric Lindquist, DMV  
DABVP, Cert. IVUSS

**IMAGING PERFORMED BY**

Amy Mayhew LVT

**HOSPITAL NAME**

SVS Imaging Michigan

**REFERRING VET**

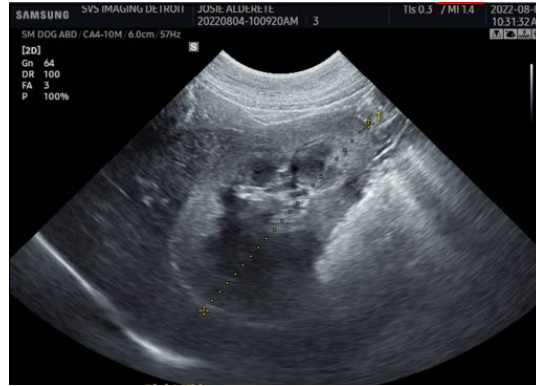Union Lake VH

**INVOICE**

32161

**DATE**

8/4/22



The information and recommendations provided are based on the images presented by the referring veterinarian/sonographer. No evaluation can be communicated regarding pathology that was not visible in the image/video clips provided.

Thank you for this referral. If the clinical or image interpretation does not parallel your findings or if I can be of any further assistance please contact me.

**Eric Lindquist**, DMV, DABVP, Cert. IVUSS, CEO of SonoPath.com  
Eric.Lindquist@SonoPath.com