



**PATIENT**

Rocko Musser

**SPECIES**

Canine

**BREED**

Labrador Retriever

**SEX**

Male

**AGE**

10 Years

**WEIGHT**

32.4 kg

**INTERPRETED BY**

Eric Lindquist, DMV

DABVP, Cert. IVUSS

**IMAGING PERFORMED BY**

Dr. Laura de Cordon

**HOSPITAL NAME**

Mason Dixon Animal  
Emergency Hospital

**REFERRING VET**

Dr. Laura de Cordon

**INVOICE**

40899

**DATE**

8/31/22

**PRESENTING CLINICAL SIGNS**

4-5 day history of lethargy and anorexia. Seen at RDVM yesterday, found febrile on PE. Treated symptomatically with SQF and GI protectants. Today persistent pyrexia and lethargy. Not eating

Abnormal PE/Chem/CBC/UA Results: GI Abnormal - organomegally Hydration - <5% dehydrated  
CBC: 26.000 low CHEM: increased ALP, globulins and total protein

**ULTRASONOGRAPHIC EXAMINATION OF THE ABDOMEN**

**Urinary System**

The **urinary bladder**, trigone, and pelvic urethra presented normal thicknesses and normal tone. The ureters were not visible which is normal. No uroliths or sediment were visualized, and anechoic urine was present. No evidence of inflammatory or neoplastic changes were noted. Ureteral papillae were normal.

The **kidneys** revealed normal size and structure, corticomedullary definition and ratio for this age. The cortices presented largely uniform texture with normal echogenic relationship to liver and spleen. Medullary structure differed distinctly from the cortex and no evidence of pelvic dilation was present. The capsules were acceptably uniform without significant irregularities. The left kidney measured 6.34 cm. The right kidney measured 6.47 cm.

**Adrenal Glands**

The regions of the **adrenal glands** were unremarkable.

**Spleen**

The **spleen** presented subtle micronodular changes. The spleen was folded upon itself cranially, superimposing upon the enlarged liver.

**Liver**

The **liver** was mildly enlarged, yet uniform. Minor gallbladder debris noted.

**Gastrointestinal**

Examination of the **gastrointestinal tract** revealed a stomach and intestine free of stasis, of normal wall thickness, acceptable curvilinear mural detail, and peristaltic activity. Small and large intestine demonstrated normal luminal chyme and stool consistency respectively. No obstructive or overt infiltrative disease was noted. Mesenteric lymph nodes were mildly enlarged, hypoechoic and irregular, measuring up to 1.0 cm. Pericapsular inflammation noted around the lymph nodes.

**Pancreas**

The base and limbs of the **pancreas** were observed to be largely isoechoic to surrounding omental fat. Pancreatic duct and capsular contour were acceptably normal and parenchyma respected normal curvilinear patterns. No overt evidence of active inflammatory or neoplastic disease was noted.

**ULTRASONOGRAPHIC FINDINGS**

- Splenic enlargement with minor micronodular changes
- Enlarged liver and minor gallbladder debris



**PATIENT**

Rocko Musser

**INTERPRETATION OF THE FINDINGS & FURTHER RECOMMENDATIONS**

Recommend ultrasound guided FNA of the spleen and liver to assess for splenitis, reactive spleen, or round cell neoplasia.

**SPECIES**

Canine

**BREED**

Labrador Retriever

**SEX**

Male

**AGE**

10 Years

**WEIGHT**

32.4 kg

**INTERPRETED BY**

Eric Lindquist, DMV

DABVP, Cert. IVUSS

**IMAGING PERFORMED BY**

Dr. Laura de Cordon

**HOSPITAL NAME**

Mason Dixon Animal  
Emergency Hospital

**REFERRING VET**

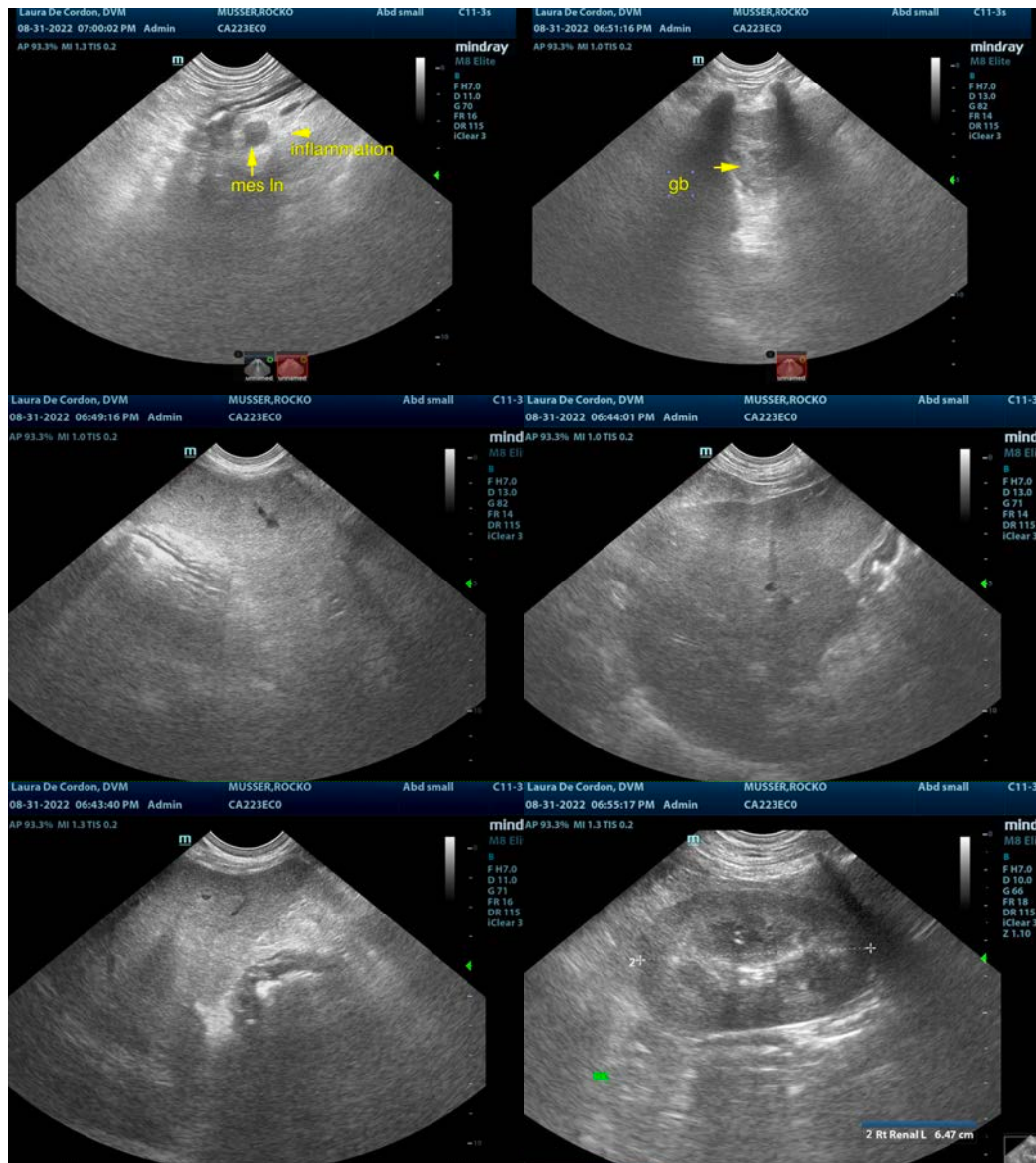
Dr. Laura de Cordon

**INVOICE**

40899

**DATE**

8/31/22





**PATIENT**

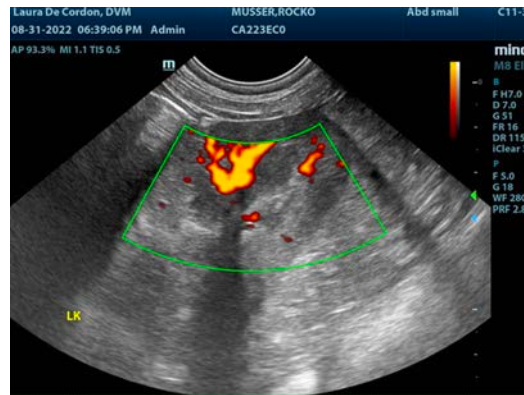
Rocko Musser

**SPECIES**

Canine

**BREED**

Labrador Retriever



**SEX**

Male

The information and recommendations provided are based on the images presented by the referring veterinarian/sonographer. No evaluation can be communicated regarding pathology that was not visible in the image/video clips provided.

**AGE**

10 Years

Thank you for this referral. If the clinical or image interpretation does not parallel your findings or if I can be of any further assistance please contact me.

**Eric Lindquist**, DMV, DABVP, Cert. IVUSS, CEO of SonoPath.com

[info@SonoPath.com](mailto:info@SonoPath.com)

**WEIGHT**

32.4 kg

**INTERPRETED BY**

Eric Lindquist, DMV

DABVP, Cert. IVUSS

**IMAGING PERFORMED BY**

Dr. Laura de Cordon

**HOSPITAL NAME**

Mason Dixon Animal  
Emergency Hospital

**REFERRING VET**

Dr. Laura de Cordon

**INVOICE**

40899

**DATE**

8/31/22