



PATIENT PRESENTING CLINICAL SIGNS

Chicco Fried
 History: Coughing,
 Abnormal PE/Chem/CBC/UA Results: BP 135/115(119), 141/78(123),101/78(88)

SPECIES

Canine

BREED

Chihuahua

SEX

Neutered male

AGE

11 years

WEIGHT

4.7 lbs

INTERPRETED BY

Eric Lindquist, DMV
 DABVP, Cert. IVUSS

IMAGING PERFORMED BY

JK

HOSPITAL NAME

Hamburg VC

REFERRING VET

Dr. Martens

ULTRASONOGRAPHIC EXAMINATION OF THE HEART

The **echocardiogram** presented a prominent **right heart** with mild **right ventricular** hypertrophy, without significant **tricuspid** regurgitation, and normal **right atrial** size. No evidence of neoplasia was noted in the right auricle, or elsewhere in the heart. The **pulmonary artery** was uniformly prominent with mildly depressed pulmonic velocity measured on PW Doppler. No overt heartworms were noted in the main or visible deep pulmonary arteries. Yet, theoretically heartworms could be present in the deep pulmonary vasculature out of visible sonographic range. More likely, however, this prominent right heart is due to excessive intra-thoracic pressures caused by chronic respiratory disease or potentially excessive intra-thoracic fat (Pickwickian syndrome). The **left heart** demonstrated a linear **ventricular septum**. Contractility was functionally adequate demonstrated by the FS% measurement. The **mitral valve** revealed insufficiency with no significant **left atrial** dilation. The **left ventricular outflow** demonstrated normal flow patterns and velocities through the aortic valve. No evidence of tumor, pericardial or pleural effusion was noted. The visible **extra-cardiac** tissues were uniformly linear without evidence of masses, infiltrative or inflammatory mediastinal tissue. No evident arrhythmic activity was noted during the exam.

CANINE CARDIAC PARAMETERS	MR VMAX (m/s)	TR VMAX (m/s)	LA/AO (Boon method)	LA/AO (Heart Base; Swe)	FS (%)	EF (%)	EPSS (cm)
NORMAL PARAMETER	4.5-5.5	<2.7	1.3	<1.6	28-40	40-100	<0.6
PATIENT			1.3	1.4	47	82	0.2
CANINE CARDIAC PARAMETERS	HR (BPM)	AV VMAX (m/s)	PV MAX (m/s)	BODY WEIGHT	LA (2D short axis Base view) (cm)	LVIDd (Avg; 2D and m-mode short axis) (cm)	LVIDs (Avg; 2D and m-mode short axis) (cm)
NORMAL PARAMETER	50-100	0.7-1.7	0.7-1.6	BELOW	BELOW	BELOW	BELOW
PATIENT	106	1.1		4.7 lbs		1.28	

ULTRASONOGRAPHIC FINDINGS

Cor pulmonale with minor mitral insufficiency.

INVOICE

32679

INTERPRETATION OF THE FINDINGS & FURTHER RECOMMENDATIONS

DATE

8/31/22

The cough is non-cardiogenic in this patient. Primary respiratory protocol is warranted based on radiographs and clinical signs.



PATIENT

Chicco Fried

SPECIES

Canine

BREED

Chihuahua

SEX

Neutered male

AGE

11 years

WEIGHT

4.7 lbs

INTERPRETED BY

Eric Lindquist, DMV
DABVP, Cert. IVUSS

IMAGING PERFORMED BY

JK

HOSPITAL NAME

Hamburg VC

REFERRING VET

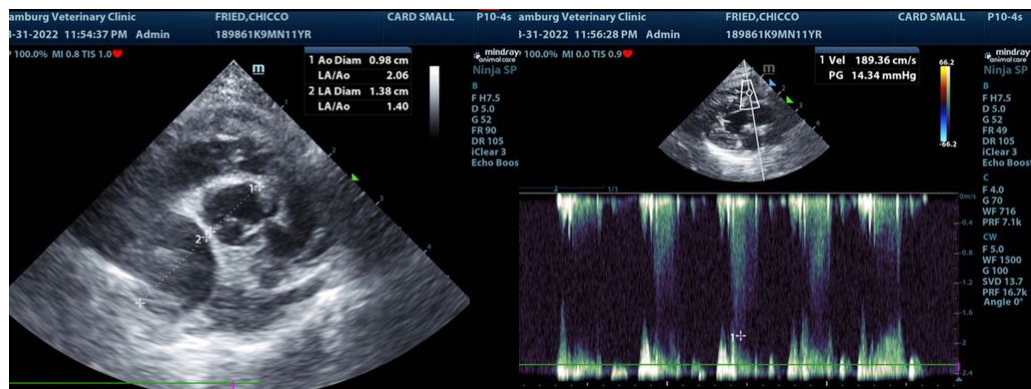
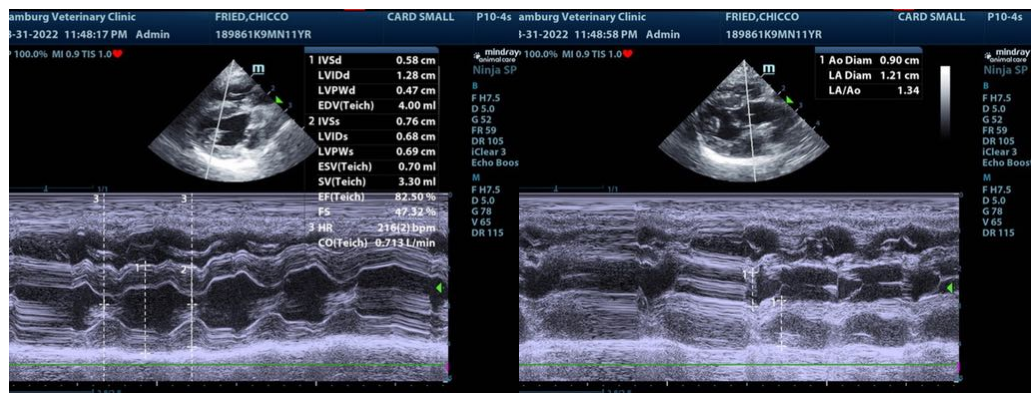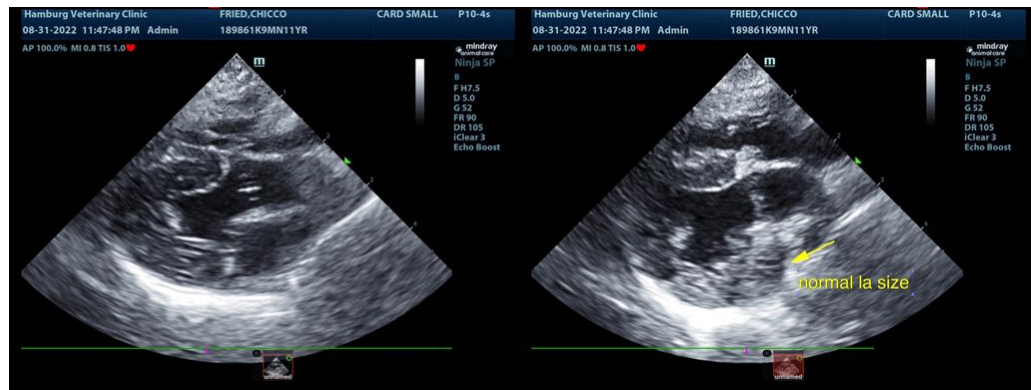
Dr. Martens

INVOICE

32679

DATE

8/31/22



The information and recommendations provided are based on the images presented by the referring veterinarian/sonographer. No evaluation can be communicated regarding pathology that was not visible in the image/video clips provided.

Thank you for this referral. If the clinical or image interpretation does not parallel your findings or if it can be of any further assistance please contact me.

Eric Lindquist, DMV, DABVP, Cert. IVUSS, CEO of SonoPath.com
info@SonoPath.com