



PATIENT

Giacamo Scuteri

SPECIES

Canine

BREED

Brussels Griffon

SEX

Neutered Male

AGE

2008

WEIGHT

10.5 lbs

INTERPRETED BY

Eric Lindquist, DMV
DABVP, Cert IVUSS

IMAGING PERFORMED BY

Denise Bruno, LVT,
RDMS

HOSPITAL NAME

Brooklyn Heights VH

REFERRING VET

Dr. Thomson

INVOICE

91608

DATE

08/31/21

PRESENTING CLINICAL SIGNS

History: Mass – caudal abdomen

Anemia

Evaluate for neoplasia

Labs + Radiographs attached

ULTRASONOGRAPHIC EXAMINATION OF THE ABDOMEN

Urinary System

The **urinary bladder**, trigone, and pelvic urethra presented normal thicknesses and normal tone. The ureters were not visible which is normal. No uroliths or sediment were visualized and anechoic urine was present. No evidence of inflammatory or neoplastic changes was noted. Ureteral papillae were normal.

The residual prostate was uniform and measured 0.49 cm.

The right **kidney** measured 4.23 cm with minor heterogenous cortical changes and capsular expansion at the caudal pole. The left kidney revealed an expansive, mixed hypoechoic mass that was deriving from the caudal pole with regional inflammation.

Adrenal Glands

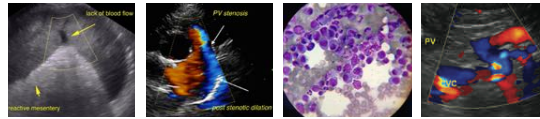
Both **adrenal glands** were visualized and recognized as having normal shape, size, position and echogenicity for this breed. The phrenic vasculature, glandular echogenicity and detail were unremarkable. Capsule, cortex, and medullary definition were normal for this age patient. The right adrenal gland measured 1.9 x 0.38 cm at the caudal pole and 0.47 cm at the cranial pole. The left adrenal gland measured 1.31 x 0.38 cm at the caudal pole and 0.42 cm at the cranial pole.

Spleen

The **spleen** presented a smooth homogeneous parenchyma hyperechoic to liver and renal cortical parenchyma. The capsule was smooth without noticeable expansion or deviation from within the spleen or adjacent pathology. The splenic vasculature demonstrated normal volume without signs of congestion or thrombosis. No sonographic evidence of acute or chronic inflammatory, neoplastic, or infarctual changes was noted.

Liver

Exam of the cranial abdomen demonstrated excessive **liver** size and swollen contour. Mild, coarse architecture was noted with increased portal markings and minor parenchymal remodeling is suggestive of an inflammatory component. Minor, hypoechoic nodular changes were noted and an overt, mixed, hypoechoic undifferentiated 4.0 cm mass with cystic components deviating the gallbladder laterally. Minor excessive GB debris was noted with the presence gall bladder dilation and precipitate without the overt formation of mucocele but this may be an issue in the future. This type of liver presentation typically is associated with slow and gradual SAP elevations with low-grade ALT rise. USG-FNA sampling is encouraged if more aggressive LE profiles are present such as ALT > 200 or rapid rise in SAP.



PATIENT

Giacamo Scuteri

These presentations are usually reactive hepatopathies owing to other disease processes either endocrine (Diabetes, Hypothyroidism, Cushing's disease), "antigen surveillance" from the gut/pancreas, or idiopathic breed predisposed progressions.

SPECIES

Canine

Gastrointestinal

Examination of the **gastrointestinal tract** revealed a stomach and intestine free of stasis, of normal wall thickness, acceptable curvilinear mural detail, and peristaltic activity. Small and large intestine demonstrated normal luminal chyme and stool consistency respectively. A mesenteric lymph node mass was noted and measured 6.0 cm.

BREED

Brussels Griffon

SEX

Neutered Male

Pancreas

The base and limbs of the **pancreas** were observed to be largely isoechoic to surrounding omental fat. Pancreatic duct and capsular contour were acceptably normal and parenchyma respected normal curvilinear patterns. No overt evidence of active inflammatory or neoplastic disease was noted.

AGE

2008

ULTRASONOGRAPHIC FINDINGS

WEIGHT

10.5 lbs

Mesenteric lymph node mass with metastatic pattern to the kidneys and liver. Multi-focal sarcoma is suspected.

INTERPRETED BY

Eric Lindquist, DMV
DABVP, Cert IVUSS

INTERPRETATION OF THE FINDINGS & FURTHER RECOMMENDATIONS

FNA of any of the lesions should be prove diagnostic.

IMAGING PERFORMED BY

Denise Bruno, LVT,
RDMS

HOSPITAL NAME

Brooklyn Heights VH

REFERRING VET

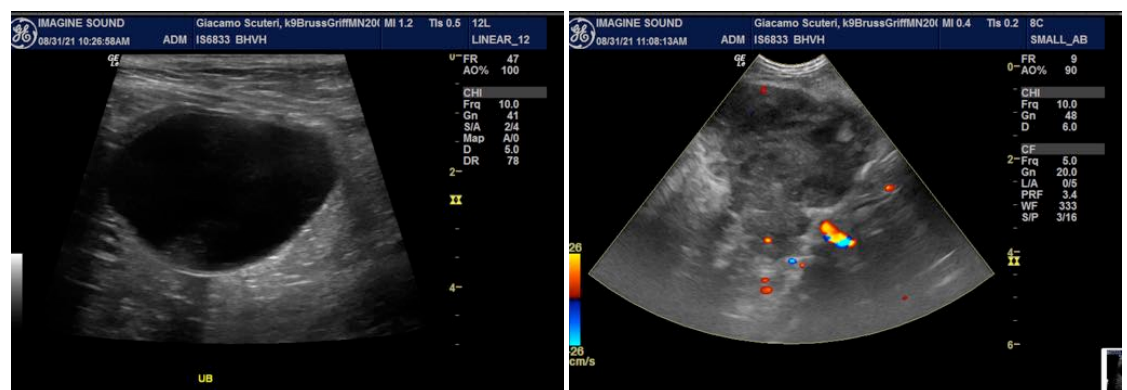
Dr. Thomson

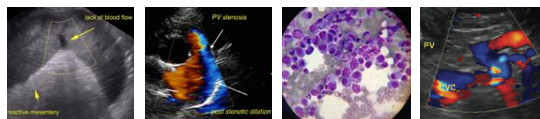
INVOICE

91608

DATE

08/31/21





PATIENT

Giacamo Scuteri

SPECIES

Canine

BREED

Brussels Griffon

SEX

Neutered Male

AGE

2008

WEIGHT

10.5 lbs

INTERPRETED BY

Eric Lindquist, DMV
DABVP, Cert IVUSS

IMAGING PERFORMED BY

Denise Bruno, LVT,
RDMS

HOSPITAL NAME

Brooklyn Heights VH

REFERRING VET

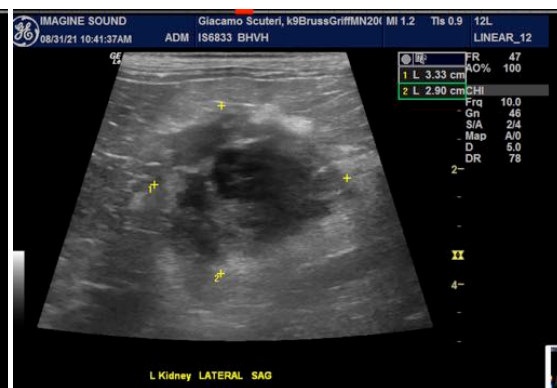
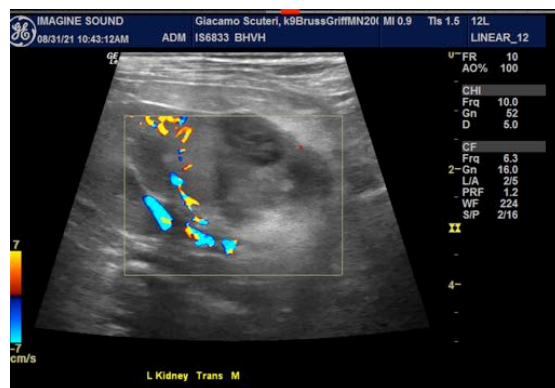
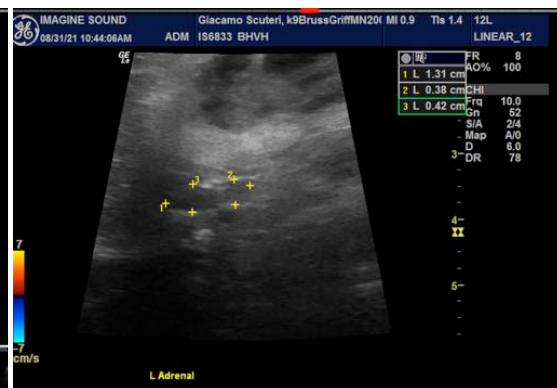
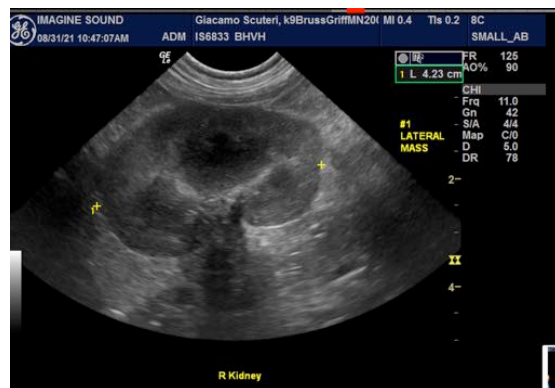
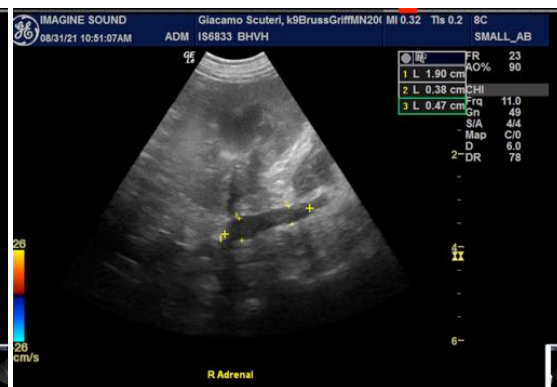
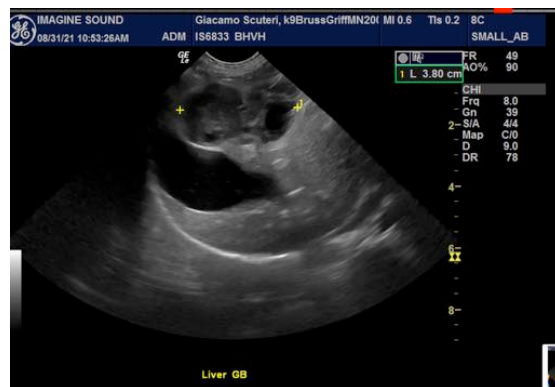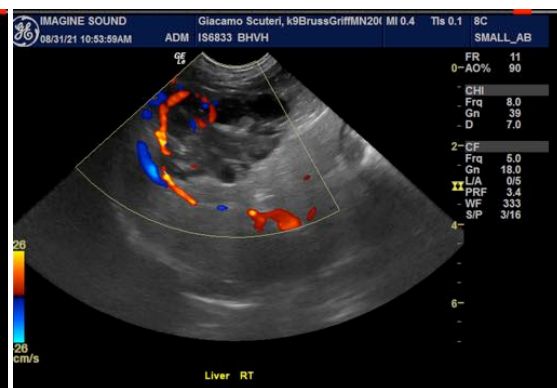
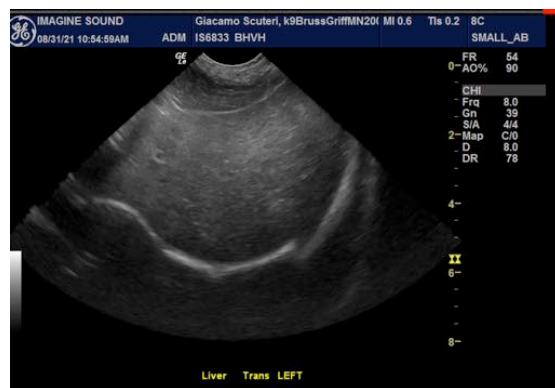
Dr. Thomson

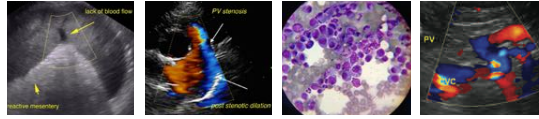
INVOICE

91608

DATE

08/31/21





PATIENT

Giacamo Scuteri

SPECIES

Canine

BREED

Brussels Griffon

SEX

Neutered Male

AGE

2008

WEIGHT

10.5 lbs

INTERPRETED BY

Eric Lindquist, DMV
DABVP, Cert IVUSS

**IMAGING
PERFORMED BY**

Denise Bruno, LVT,
RDMS

HOSPITAL NAME

Brooklyn Heights VH

REFERRING VET

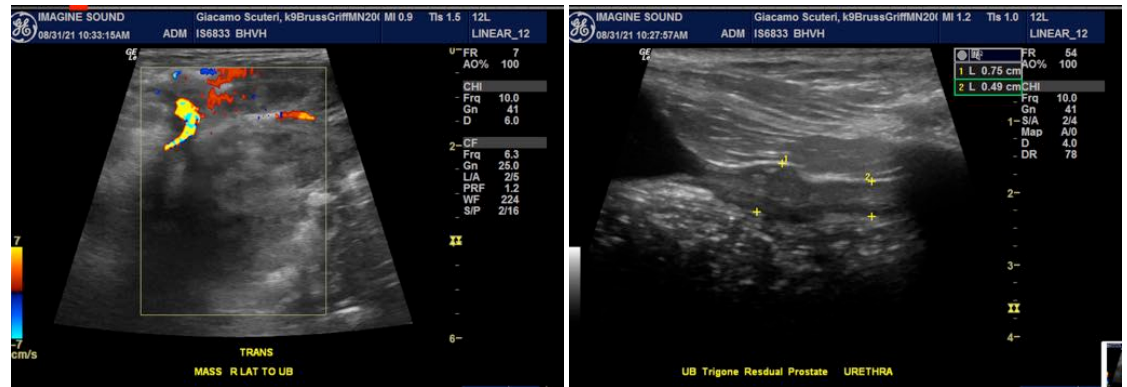
Dr. Thomson

INVOICE

91608

DATE

08/31/21



The information and recommendations provided are based on the images presented by the referring veterinarian. No evaluation can be communicated regarding pathology that was not visible in the image/video clips provided.

Thank you for this referral. If the clinical or image interpretation does not parallel your findings or if I can be of any further assistance please contact me.

Eric Lindquist, DMV, DABVP, Cert. IVUSS, CEO of SonoPath.com
Eric.Lindquist@SonoPath.com