SonoPath
Clinical Sonography & Telecytology

EDUCATIONAL TELECONSULTATION SERVICES™

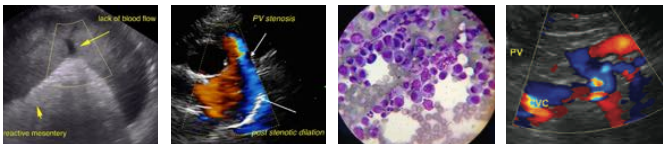

SonoPath.com™
1-800-838-4268 info@sonopath.com

PATIENT

Bambi Lamadrid

SPECIES

Canine

BREED

Yorkshire Terrier

SEX

Male

AGE

14 years

WEIGHT

12.4 lbs

INTERPRETED BY

Eric Lindquist, DMV
DABVP, Cert. IVUSS

IMAGING PERFORMED BY

Dr. Kim

HOSPITAL NAME

Ridgefield Park AH

REFERRING VET

Dr. Kim

INVOICE

91594

DATE

8/31/21

PRESENTING CLINICAL SIGNS

History: Patient presented to the hospital due to lethargy, excessive urinating and drinking water more than usual, enlarged abdomen, hair loss. Difficulty breathing at nights, with coughing and sneezing. During physical exam, patient had bilateral hair loss, one testicle enlarged and heavy brathing specially when excited.
Bun: 51 mg/dL Amylase 1500 IU/L Globulin: 4.1 g/dL UA SG 1.018 PH 7

ULTRASONOGRAPHIC EXAMINATION OF THE ABDOMEN

Urinary System

The **urinary bladder**, trigone, and pelvic urethra presented normal thicknesses and normal tone. The ureters were not visible which is normal. No uroliths or sediment were visualized and anechoic urine was present. No evidence of inflammatory or neoplastic changes was noted. Ureteral papillae were normal.

The right testicle was subnormal in size with hypoechoic, nodular changes and measured 0.84 cm in width. The left testicle revealed an undifferentiated 3.0 cm mass. The **prostate** was uniformly enlarged with lobar swelling appeared to impinge upon the urethra and mildly deviate the descending colon. The prostatic tissue was hyperechoic containing focal areas of decreased echogenicity. These changes are suggestive of either chronic inflammatory episodes, benign cystic pathology or both. Underlying neoplasia cannot be completely ruled-out but is lower on the differential list. This presentation is most consistent with benign prostatic hyperplasia with possible active prostatitis. Neutering or off-label Finasteride (Propecia) (0.1-0.5 mg/kg Sid) treatment is indicated +/- FNA or prostatic wash cytology and culture. The prostate measured 2.06 cm.

The **kidneys** revealed largely normal size and structure, corticomedullary definition and ratio (cortex 1/3 of medulla) were essentially maintained with some age-related loss of curvilinear patterns regarding the capsule and C/M junction. The cortices presented largely uniform texture with some increased echogenicity expected for this age patient. Medullary structure differed distinctly from that of the cortex and no evidence of pelvic dilation was present.

Adrenal Glands

The right **adrenal gland** was uniform and measured 0.42 cm. The left adrenal gland was mildly heterogenous and mildly swollen, yet relatively normal in size at 0.45 cm.

Spleen

The **spleen** presented a smooth homogeneous parenchyma hyperechoic to liver and renal cortical parenchyma. The capsule was smooth without noticeable expansion or deviation from within the spleen or adjacent pathology. The splenic vasculature demonstrated normal volume without signs of congestion or thrombosis. No sonographic evidence of acute or chronic inflammatory, neoplastic, or infarctual changes was noted.

SonoPath

Clinical Sonography & Telecytology

EDUCATIONAL TELECONSULTATION SERVICES™

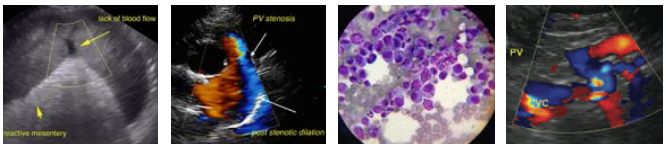

SonoPath.com™
1-800-838-4268 info@sonopath.com

PATIENT

Bambi Lamadrid

SPECIES

Canine

BREED

Yorkshire Terrier

SEX

Male

AGE

14 years

WEIGHT

12.4 lbs

INTERPRETED BY

Eric Lindquist, DMV
DABVP, Cert. IVUSS

IMAGING PERFORMED BY

Dr. Kim

HOSPITAL NAME

Ridgefield Park AH

REFERRING VET

Dr. Kim

INVOICE

91594

DATE

8/31/21

Liver

The **liver** revealed increased portal markings and coarse architecture. There was a mild amount of remodeling. The gallbladder presented acceptably thin walls with primarily anechoic content. The cystic and common bile ducts were normal. No pathological hepatic lymphadenopathy was evident. No overt structural evidence of inflammatory, infiltrative or regenerative pathology was evident.

Gastrointestinal

Examination of the **gastrointestinal tract** revealed a stomach and intestine free of stasis, of normal wall thickness, acceptable curvilinear mural detail, and peristaltic activity. Small and large intestine demonstrated normal luminal chyme and stool consistency respectively. No obstructive or overt infiltrative disease was noted. No associated abnormal lymphatic activity was noted.

Pancreas

Diffuse hyperechoic changes were present in the area of the **pancreas**. The pancreatic remodeling was evident with multifocal to diffuse hyperechoic changes. These changes are consistent with fibrosis, amyloid, saponification of fat and may contain areas of low-grade chronic active inflammation especially if pain on imaging (+ Murphy sign) was present +/- focal subxiphoid palpation reveals pain response. No overt masses were noted.

ULTRASONOGRAPHIC FINDINGS

Left testicular mass with right testicular atrophy and nodular changes.

BPH prostate. Paraprostatic cysts were also noted and measured 1.0 cm.

Minor, irregular left adrenal gland.

Minor hepatic remodeling.

Pancreatic fibrosis.

INTERPRETATION OF THE FINDINGS & FURTHER RECOMMENDATIONS

I recommend neutering in this patent with a recheck ultrasound of the prostate 3 weeks after neuter. The clinical signs are likely related to the left testicular mass. Sertoli cell tumor is suspected.

SonoPath

Clinical Sonography & Telecytology

EDUCATIONAL TELECONSULTATION SERVICES™

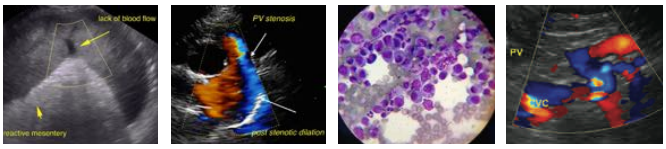

SonoPath.com™
1-800-838-4268 info@sonopath.com

PATIENT

Bambi Lamadrid

SPECIES

Canine

BREED

Yorkshire Terrier

SEX

Male

AGE

14 years

WEIGHT

12.4 lbs

INTERPRETED BY

Eric Lindquist, DMV
DABVP, Cert. IVUSS

IMAGING PERFORMED BY

Dr. Kim

HOSPITAL NAME

Ridgefield Park AH

REFERRING VET

Dr. Kim

INVOICE

91594

DATE

8/31/21

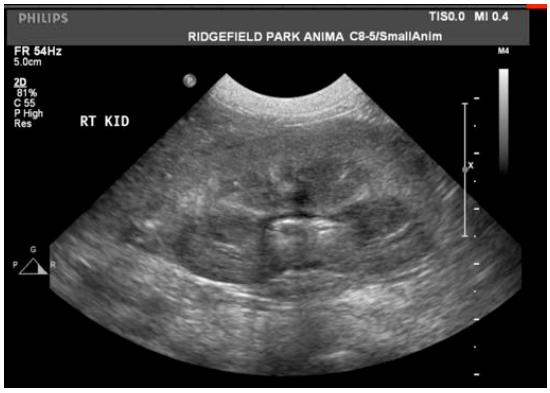

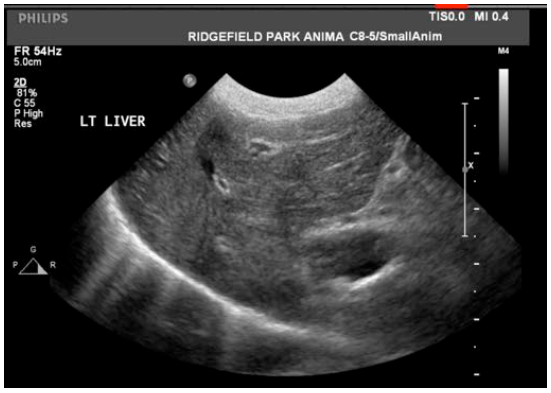

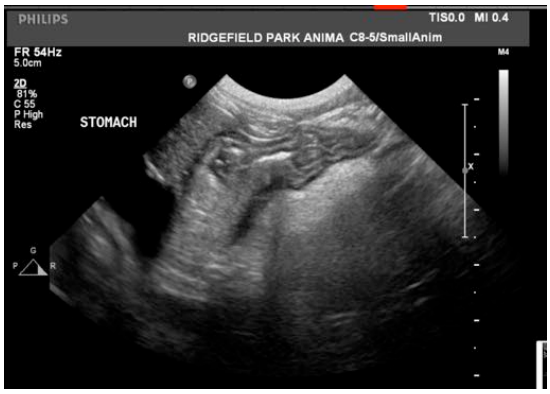

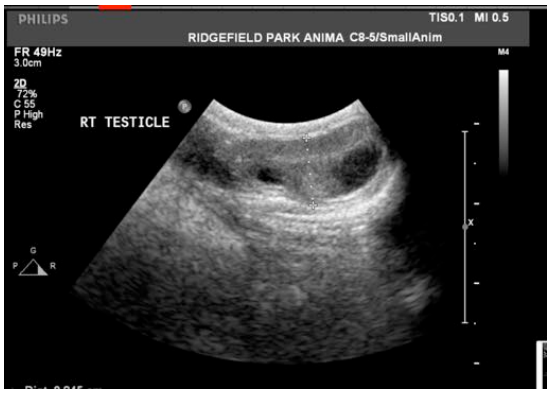

SonoPath

Clinical Sonography & Telecytology

EDUCATIONAL TELECONSULTATION SERVICES™

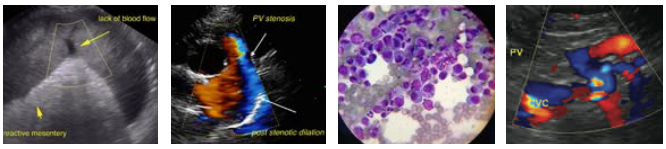

SonoPath.com™
1-800-838-4268 info@sonopath.com

PATIENT

Bambi Lamadrid

SPECIES

Canine

BREED

Yorkshire Terrier

SEX

Male

AGE

14 years

WEIGHT

12.4 lbs

INTERPRETED BY

Eric Lindquist, DMV
DABVP, Cert. IVUSS

IMAGING PERFORMED BY

Dr. Kim

HOSPITAL NAME

Ridgefield Park AH

REFERRING VET

Dr. Kim

INVOICE

91594

DATE

8/31/21

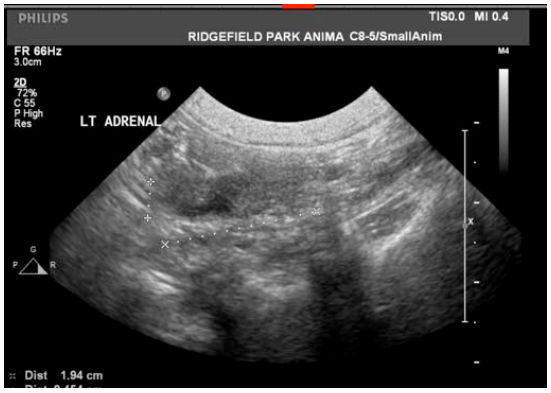

The information and recommendations provided are based on the images presented by the referring veterinarian. No evaluation can be communicated regarding pathology that was not visible in the image/video clips provided.

Thank you for this referral. If the clinical or image interpretation does not parallel your findings or if I can be of any further assistance please contact me.

Eric Lindquist, DMV, DABVP, Cert. IVUSS, CEO of SonoPath.com
info@SonoPath.com