

PATIENT

Baker Redmond

SPECIES

Canine

BREED

Labradoodle

SEX

Neutered Male

AGE

2017

WEIGHT

50.5 lbs

INTERPRETED BY

Eric Lindquist, DMV
DABVP, Cert IVUSS

**IMAGING
PERFORMED BY**

Denise Bruno, LVT,
RDMS

HOSPITAL NAME

Brooklyn Heights VH

REFERRING VET

Dr. Thomson

INVOICE

91601

DATE

08/31/21

PRESENTING CLINICAL SIGNS

History: Panting excess

Decreased appetite, lethargy, bloated abdomen

Hx pancreatitis

Evaluate for pancreatitis, pain (IVDD), respiratory, occult mass

Labs attached

ULTRASONOGRAPHIC EXAMINATION OF THE ABDOMEN

Urinary System

The **urinary bladder**, trigone, and pelvic urethra presented normal thicknesses and normal tone. The ureters were not visible which is normal. No uroliths or sediment were visualized and anechoic urine was present. No evidence of inflammatory or neoplastic changes was noted. Ureteral papillae were normal.

The residual prostate was uniform and measured 1.0 cm. The pre and post prostatic urethra was unremarkable.

The **kidneys** revealed normal size and structure, corticomedullary definition and ratio for this age. The cortices presented largely uniform texture with normal echogenic relationship to liver and spleen. Medullary structure differed distinctly from the cortex and no evidence of pelvic dilation was present. The capsules were acceptably uniform without significant irregularities. The right kidney measured 6.0 cm. The left kidney measured 5.82 cm.

Adrenal Glands

Both **adrenal glands** were visualized and recognized as having normal shape, size, position and echogenicity for this breed. The phrenic vasculature, glandular echogenicity and detail were unremarkable. Capsule, cortex, and medullary definition were normal for this age patient. The right adrenal gland measured 2.52 x 0.62 cm at the caudal pole and 0.52 cm at the cranial pole. The left adrenal gland measured 2.04 x 0.5 cm at the caudal pole and 0.53 cm at the cranial pole.

Spleen

The **spleen** presented a smooth homogeneous parenchyma hyperechoic to liver and renal cortical parenchyma. The capsule was smooth without noticeable expansion or deviation from within the spleen or adjacent pathology. The splenic vasculature demonstrated normal volume without signs of congestion or thrombosis. No sonographic evidence of acute or chronic inflammatory, neoplastic, or infarctual changes was noted.

Liver

The **liver** images submitted revealed subjectively normal liver size, contour, and structure. Parenchymal echogenicity was naturally coarse and hypoechoic to the spleen. Vascular and biliary tracts were of normal volume with no evidence of congestion. The gallbladder presented acceptably thin walls with



PATIENT

Baker Redmond

primarily anechoic content. The cystic and common bile ducts were normal. No pathological hepatic lymphadenopathy was evident. No overt structural evidence of inflammatory, infiltrative or regenerative pathology was evident.

SPECIES

Canine

Gastrointestinal

Examination of the **gastrointestinal tract** revealed a stomach and intestine free of stasis, of normal wall thickness, acceptable curvilinear mural detail, and peristaltic activity. There was some retention of ingesta was noted in the stomach. Small and large intestine demonstrated normal luminal chyme and stool consistency respectively. No obstructive or overt infiltrative disease was noted. No associated abnormal lymphatic activity was noted.

BREED

Labradoodle

SEX

Neutered Male

Pancreas

The base and limbs of the **pancreas** were observed to be largely isoechoic to surrounding omental fat. Pancreatic duct and capsular contour were acceptably normal and parenchyma respected normal curvilinear patterns. No overt evidence of active inflammatory or neoplastic disease was noted.

AGE

2017

ULTRASONOGRAPHIC FINDINGS

WEIGHT

50.5 lbs

Minor retention of ingesta.

Otherwise, unremarkable abdomen.

INTERPRETED BY

Eric Lindquist, DMV
DABVP, Cert IVUSS

INTERPRETATION OF THE FINDINGS & FURTHER RECOMMENDATIONS

Despite the amylase and lipase being significantly elevated, there are no significant changes noted in the area of the pancreas. Acute inflammation is possible without sonographic appearance. However, structurally the pancreas and other organs appear unremarkable other than minor retention of ingesta in the stomach.

IMAGING PERFORMED BY

Denise Bruno, LVT,
RDMS

HOSPITAL NAME

Brooklyn Heights VH

REFERRING VET

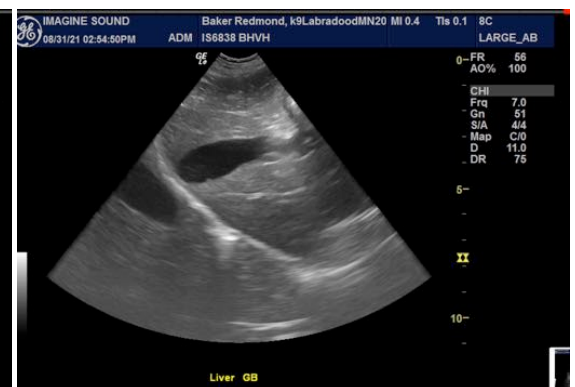
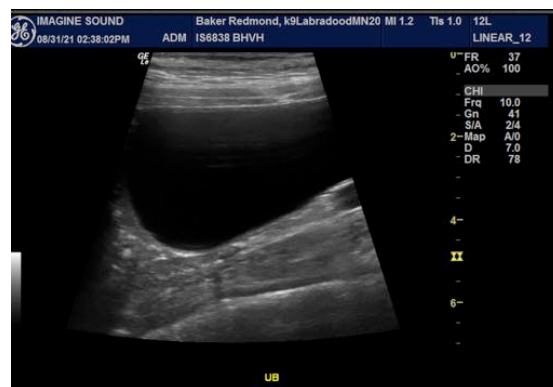
Dr. Thomson

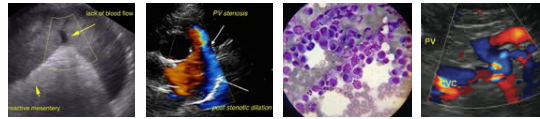
INVOICE

91601

DATE

08/31/21





PATIENT

Baker Redmond

SPECIES

Canine

BREED

Labradoodle

SEX

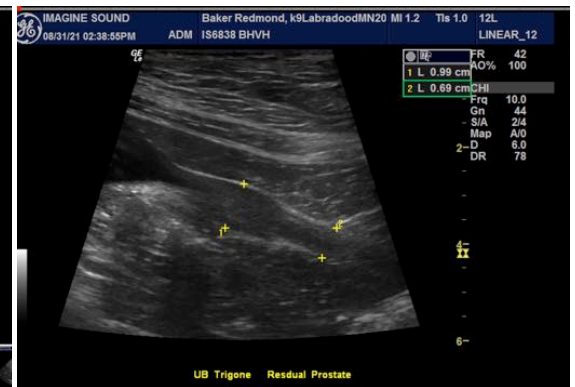
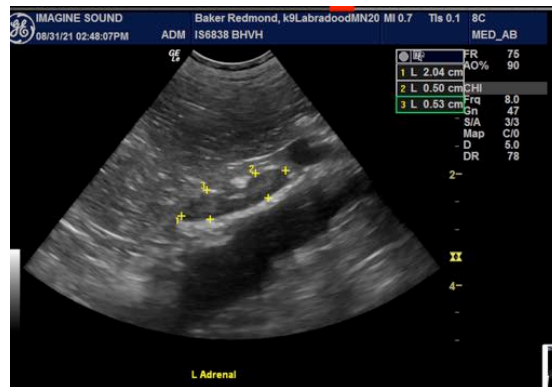
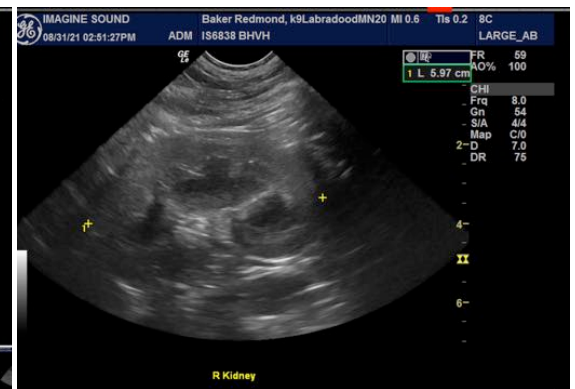
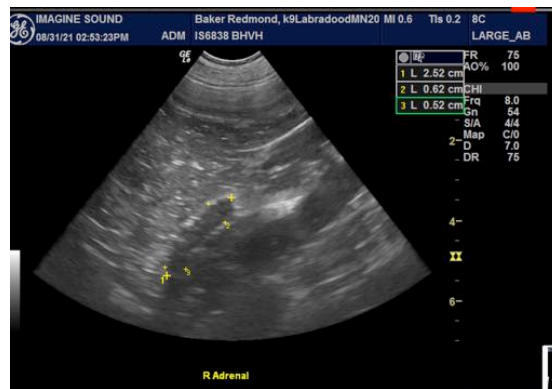
Neutered Male

AGE

2017

WEIGHT

50.5 lbs



INTERPRETED BY

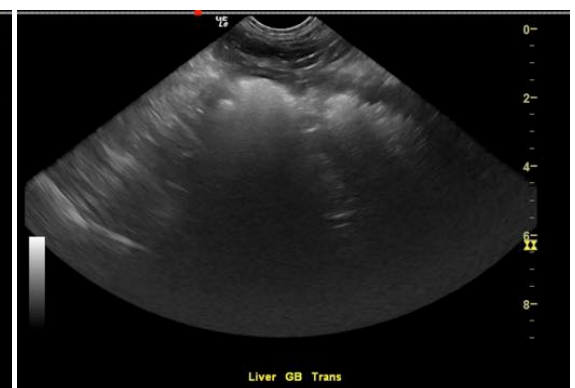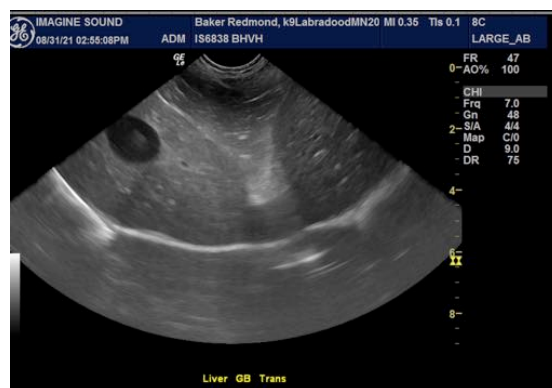
Eric Lindquist, DMV
DABVP, Cert IVUSS

IMAGING PERFORMED BY

Denise Bruno, LVT,
RDMS

HOSPITAL NAME

Brooklyn Heights VH



REFERRING VET

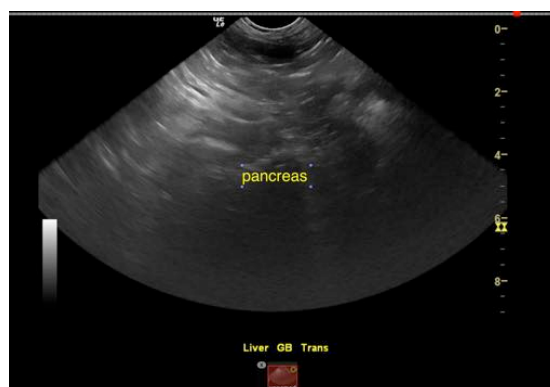
Dr. Thomson

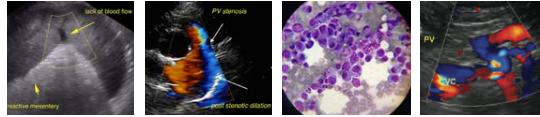
INVOICE

91601

DATE

08/31/21





PATIENT

Baker Redmond

The information and recommendations provided are based on the images presented by the referring veterinarian. No evaluation can be communicated regarding pathology that was not visible in the image/video clips provided.

SPECIES

Canine

Thank you for this referral. If the clinical or image interpretation does not parallel your findings or if I can be of any further assistance please contact me.

BREED

Labradoodle

Eric Lindquist, DMV, DABVP, Cert. IVUSS, CEO of SonoPath.com
Eric.Lindquist@SonoPath.com

SEX

Neutered Male

AGE

2017

WEIGHT

50.5 lbs

INTERPRETED BY

Eric Lindquist, DMV
DABVP, Cert IVUSS

**IMAGING
PERFORMED BY**

Denise Bruno, LVT,
RDMS

HOSPITAL NAME

Brooklyn Heights VH

REFERRING VET

Dr. Thomson

INVOICE

91601

DATE

08/31/21