



PATIENT

Ashley Devines

PRESENTING CLINICAL SIGNS

Increased liver enzymes.

AST 315, ALT 373

SPECIES

Canine

ULTRASONOGRAPHIC EXAMINATION OF THE ABDOMEN

BREED

Labrador

Urinary System

The **urinary bladder**, trigone, and pelvic urethra presented normal thicknesses and normal tone. The pelvic urethra was imaged 3.0 cm beyond the cystourethral junction. The ureters were not visible which is normal. No uroliths or sediment were visualized and anechoic urine was present. No evidence of inflammatory or neoplastic changes was noted. Ureteral papillae were normal.

SEX

Spayed Female

AGE

8 years

The **kidneys** revealed normal size and structure, corticomedullary definition and ratio for this age. The cortices presented largely uniform texture with normal echogenic relationship to liver and spleen. Medullary structure differed distinctly from the cortex and no evidence of pelvic dilation was present. The capsules were acceptably uniform without significant irregularities. The left kidney measured 6.7 cm. The right kidney measured 6.04 cm.

INTERPRETED BY

Eric Lindquist, DMV
DABVP, Cert. IVUSS

Adrenal Glands

Both **adrenal glands** were visualized and recognized as having normal shape, size, position and echogenicity for this breed. The phrenic vasculature, glandular echogenicity and detail were unremarkable. Capsule, cortex, and medullary definition were normal for this age patient. The left adrenal gland measured 2.0 x 0.4 cm. The right adrenal gland measured 2.5 x 0.8 cm at the cranial pole and 0.4 cm at the caudal pole.

IMAGING PERFORMED BY

Eric Lindquist, DMV
DABVP, Cert. IVUSS

HOSPITAL NAME

Andover AH

Spleen

The **spleen** presented a smooth homogeneous parenchyma hyperechoic to liver and renal cortical parenchyma. The capsule was smooth without noticeable expansion or deviation from within the spleen or adjacent pathology. The splenic vasculature demonstrated normal volume without signs of congestion or thrombosis. No sonographic evidence of acute or chronic inflammatory, neoplastic, or infarctual changes was noted.

REFERRING VET

Dr. Hummel

INVOICE

91566

Liver

The **liver** images submitted revealed subjectively normal liver size, contour, and structure. Parenchymal echogenicity was naturally coarse and hypoechoic to the spleen. Vascular and biliary tracts were of normal volume with no evidence of congestion. The gallbladder presented acceptably thin walls with primarily anechoic content. The cystic and common bile ducts were normal. No pathological hepatic lymphadenopathy was evident. No overt structural evidence of inflammatory, infiltrative or regenerative pathology was evident.

DATE

8/31/21



PATIENT

Gastrointestinal

Ashley Devines

Examination of the **gastrointestinal tract** revealed a stomach and intestine free of stasis, of normal wall thickness, acceptable curvilinear mural detail, and peristaltic activity. Small and large intestine demonstrated normal luminal chyme and stool consistency respectively. No obstructive or overt infiltrative disease was noted. No associated abnormal lymphatic activity was noted.

SPECIES

Canine

BREED

Labrador

Pancreas

The base and limbs of the **pancreas** were observed to be largely isoechoic to surrounding omental fat. Pancreatic duct and capsular contour were acceptably normal and parenchyma respected normal curvilinear patterns. No overt evidence of active inflammatory or neoplastic disease was noted.

SEX

Spayed Female

ULTRASONOGRAPHIC FINDINGS

Normal abdomen.

AGE

8 years

Structurally normal liver. Likely reactive hepatopathy.

INTERPRETED BY

Eric Lindquist, DMV
DABVP, Cert. IVUSS

INTERPRETATION OF THE FINDINGS & FURTHER RECOMMENDATIONS

Diet change to a hydrolyzed diet, assessment for recent dietary indiscretion and a clinical trial of Amoxicillin over a 10 days period is recommended followed by reassessment of the liver values. If the liver values remain elevated then ultrasound-guided FNA is warranted for further definition of inflammatory cell type. However, structurally the liver appears normal.

IMAGING PERFORMED BY

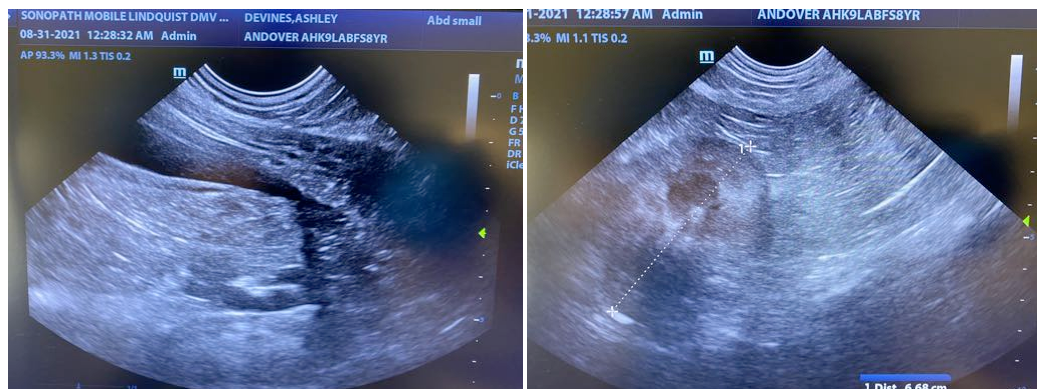
Eric Lindquist, DMV
DABVP, Cert. IVUSS

HOSPITAL NAME

Andover AH

REFERRING VET

Dr. Hummel



INVOICE

91566

DATE

8/31/21



PATIENT

Ashley Devines

SPECIES

Canine

BREED

Labrador

SEX

Spayed Female

AGE

8 years

INTERPRETED BY

Eric Lindquist, DMV
DABVP, Cert. IVUSS

IMAGING PERFORMED BY

Eric Lindquist, DMV
DABVP, Cert. IVUSS

HOSPITAL NAME

Andover AH

REFERRING VET

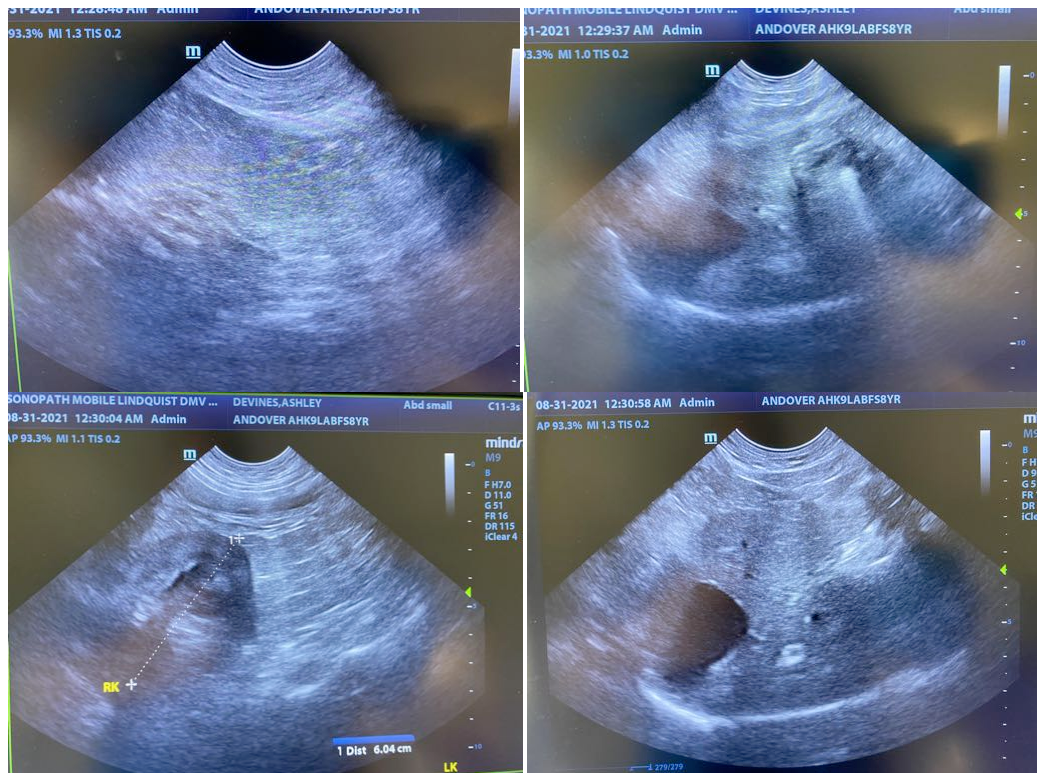
Dr. Hummel

INVOICE

91566

DATE

8/31/21



The information and recommendations provided are based on the images presented by the referring veterinarian. No evaluation can be communicated regarding pathology that was not visible in the image/video clips provided.

Thank you for this referral. If the clinical or image interpretation does not parallel your findings or if I can be of any further assistance please contact me.

Eric Lindquist, DMV, DABVP, Cert. IVUSS, CEO of SonoPath.com
Info@SonoPath.com