



PATIENT

Swazey Smith

SPECIES

Canine

BREED

Maltese Mix

SEX

Neutered male

AGE

11 years

WEIGHT

16 lbs

INTERPRETED BY

Eric Lindquist, DMV
DABVP, Cert. IVUSS

IMAGING PERFORMED BY

Nicole Gotfredson

HOSPITAL NAME

Buffalo VC

REFERRING VET

Dr. Gotfredson

PRESENTING CLINICAL SIGNS

History: referral case, dog stopped eating about 1 month ago, fever with high WBC, has been on 3 rounds of antibiotics. Lethargic, no vomiting, no coughing. weight loss from 22 to 16lbs.

Abnormal PE/Chem/CBC/UA Results: chem wnl,

ULTRASONOGRAPHIC EXAMINATION OF THE HEART

The echocardiogram in this patient demonstrated normal **left atrial** size based on 3 separate methods of LA evaluation. The **mitral** valve was slightly thickened and vegetative. Trivial mitral insufficiency was noted on color flow assessment. The **left ventricle** presented thicknesses with linear contour and was not dilated nor restricted. The **myocardium** presented normal echogenicity without subjective evidence of significant fibrotic or ischemic disease. **Contractility** of the ventricular walls was adequate and in normal range for this patient evidenced by the fractional shortening measurement and subjective evaluation of the different regions of the myocardium. The **left ventricular outflow** tract demonstrated normal laminar flow and subjective structural integrity. The **right atrium** and auricle revealed normal size, structure and content. No evidence of masses was noted. Trivial **tricuspid** insufficiency was noted. The **right ventricle** was of normal size (1/3 diameter of LV), chordae structure, myocardial echogenicity and thickness. **Pulmonary outflow** tract assessment revealed normal valve structure, laminar flow, and diameter (approx.1:1 pa/ao ratio). No visible **pericardial** or free pleura fluid was noted. The cranial **mediastinum and pericardial and extra-cardiac regions** were free of masses in the visible window.

CANINE CARDIAC PARAMETERS	MR VMAX (m/s)	TR VMAX (m/s)	LA/AO (Boon method)	LA/AO (Heart Base; Swe)	FS (%)	EF (%)	EPSS (cm)
NORMAL PARAMETER	4.5-5.5	<2.7	1.3	<1.6	28-40	40-100	<0.6
PATIENT			1.1	1.5	35		NM
CANINE CARDIAC PARAMETERS	HR (BPM)	AV VMAX (m/s)	PV MAX (m/s)	BODY WEIGHT	LA (2D short axis Base view) (cm)	LVIDd (Avg; 2D and m-mode short axis) (cm)	LVIDs (Avg; 2D and m-mode short axis) (cm)
NORMAL PARAMETER	50-100	0.7-1.7	0.7-1.6	BELOW	BELOW	BELOW	BELOW
PATIENT		1.6	0.6	16 lbs		3.0	

INVOICE

32655

DATE

8/30/22



PATIENT **ULTRASONOGRAPHIC EXAMINATION OF THE ABDOMEN**

Swazey Smith

Urinary System

SPECIES

Canine

The **urinary bladder**, trigone, and pelvic urethra presented normal thicknesses and normal tone. The ureters were not visible which is normal. No uroliths or sediment were visualized and anechoic urine was present. No evidence of inflammatory or neoplastic changes was noted. Ureteral papillae were normal.

BREED

Maltese Mix

The residual prostate measured 0.4 cm.

SEX

Neutered male

The **kidneys** revealed largely normal size and structure, corticomedullary definition and ratio (cortex 1/3 of medulla) were essentially maintained with some age-related loss of curvilinear patterns regarding the capsule and C/M junction. The cortices presented largely uniform texture with some increased echogenicity expected for his age patient. Medullary structure differed distinctly from that of the cortex and no evidence of pelvic dilation was present. The right kidney measured 5.0 cm.

AGE

11 years

Adrenal Glands

The **adrenal glands** were not visualized.

WEIGHT

16 lbs

Spleen

The **spleen** revealed a complex, mixed, hypoechoic parenchymal mass that measured 6.0 cm with areas of mineralization. Regional inflammation was noted without free fluid or rupture.

INTERPRETED BY

Eric Lindquist, DMV
DABVP, Cert. IVUSS

Liver

The **liver** images from right and left intercostal as well as subcostal views revealed subjectively normal liver size, contour, and structure. Some age-related parenchymal remodeling was noted but likely not clinically significant at this time. Vascular and biliary tracts were of normal volume and no evidence of congestion was noted. The gallbladder presented some dependent debris with essentially normal contour. The cystic and common bile ducts were normal. No overt evidence of active inflammatory, infiltrative or regenerative pathology was noted but should be paired with current or past LE elevations regarding any clinical significance to this presentation. The hepatic lymph nodes were unremarkable.

IMAGING PERFORMED BY

Nicole Gotfredson

HOSPITAL NAME

Buffalo VC

Gastrointestinal

REFERRING VET

Dr. Gotfredson

Examination of the **gastrointestinal tract** revealed a stomach and intestine free of stasis, of normal wall thickness, acceptable curvilinear mural detail, and peristaltic activity. Small and large intestine demonstrated normal luminal chyme and stool consistency respectively. No obstructive or overt infiltrative disease was noted. No associated abnormal lymphatic activity was noted.

INVOICE

32655

Pancreas

DATE

8/30/22

The base and limbs of the **pancreas** were observed to be largely isoechoic to surrounding omental fat. Pancreatic duct and capsular contour were acceptably normal and parenchyma respected normal curvilinear patterns. No overt evidence of active inflammatory or neoplastic disease was noted.



PATIENT

Swazey Smith

ULTRASONOGRAPHIC FINDINGS

Splenic mass, likely sarcoma. Regional inflammation.

Trivial mitral insufficiency, early stage B1 valvular disease.

SPECIES

Canine

INTERPRETATION OF THE FINDINGS & FURTHER RECOMMENDATIONS

I recommend chest radiographs if not already performed followed by exploratory laparotomy/splenectomy. Liver biopsy is warranted to rule out underlying occult metastasis, yet no gross metastatic changes were noted.

BREED

Maltese Mix

SEX

Neutered male

AGE

11 years

WEIGHT

16 lbs

INTERPRETED BY

Eric Lindquist, DMV
DABVP, Cert. IVUS

IMAGING PERFORMED BY

Nicole Gotfredson

HOSPITAL NAME

Buffalo VC

REFERRING VET

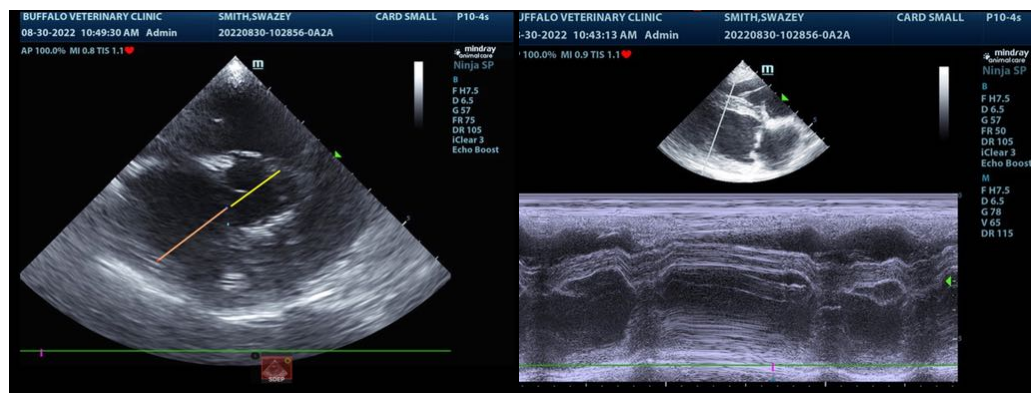
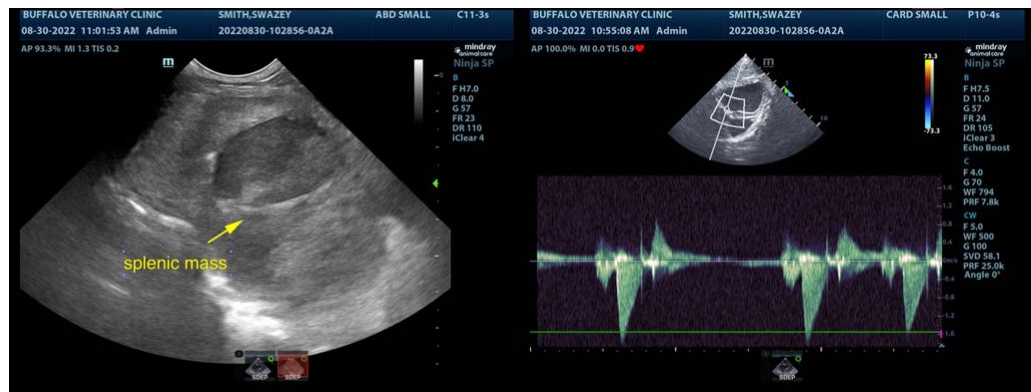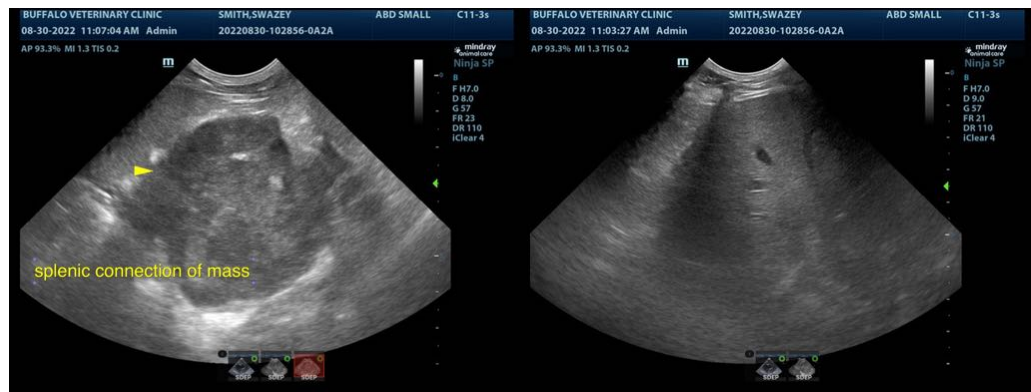Dr. Gotfredson

INVOICE

32655

DATE

8/30/22





PATIENT

Swazey Smith

SPECIES

Canine

BREED

Maltese Mix

SEX

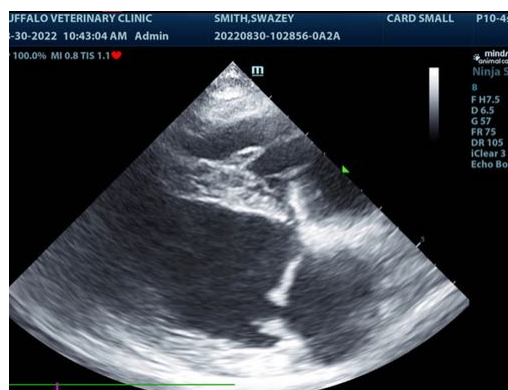
Neutered male

AGE

11 years

WEIGHT

16 lbs



The information and recommendations provided are based on the images presented by the referring veterinarian/sonographer. No evaluation can be communicated regarding pathology that was not visible in the image/video clips provided.

Thank you for this referral. If the clinical or image interpretation does not parallel your findings or if I can be of any further assistance please contact me.

Eric Lindquist, DMV, DABVP, Cert. IVUSS, CEO of SonoPath.com
info@SonoPath.com

INTERPRETED BY

Eric Lindquist, DMV
DABVP, Cert. IVUSS

IMAGING PERFORMED BY

Nicole Gotfredson

HOSPITAL NAME

Buffalo VC

REFERRING VET

Dr. Gotfredson

INVOICE

32655

DATE

8/30/22