



PATIENT

Buster Green

SPECIES

Canine

BREED

Boxer

SEX

Neutered Male

AGE

9 Years 9 Months

WEIGHT

80.9 Pounds

INTERPRETED BY

Eric Lindquist, DMV

DABVP, Cert. IVUSS

IMAGING PERFORMED BY

Dr. Jonathan Moss

HOSPITAL NAME

Harvest Hills VH

REFERRING VET

Dr. Jonathan Moss

INVOICE

40887

DATE

8/30/22

PRESENTING CLINICAL SIGNS

Pt presented for leaking urine while sleeping. Pt has normal urine stream. Pt was seen for frank blood in urine 1 year ago but had normal UA 1 month prior to.

Abnormal PE/Chem/CBC/UA Results: Urine was brought in free catch from O. UA showed blood, trace protein and USG of 1.038. Sediment exam showed few RBCs and few abnormal round cells. Pt has normal chemistry last month for long term NSAIDs for arthritis.

ULTRASONOGRAPHIC EXAMINATION OF THE ABDOMEN

Urinary System

The **urinary bladder**, trigone, and pelvic urethra presented normal thicknesses and normal tone. The ureters were not visible which is normal. No uroliths or sediment were visualized and anechoic urine was present. No evidence of inflammatory or neoplastic changes were noted. Ureteral papillae were normal. The pelvic urethra was imaged 1.0 cm beyond the cystourethral junction.

The iliac trifurcation was unremarkable.

The **kidneys** revealed normal size and structure, corticomedullary definition and ratio for this age. The cortices presented largely uniform texture with normal echogenic relationship to liver and spleen. Medullary structure differed distinctly from the cortex and no evidence of pelvic dilation was present. The capsules were acceptably uniform without significant irregularities. The left kidney measured 7.0 cm. The right kidney measured 7.0 cm.

Adrenal Glands

Both **adrenal glands** were visualized and recognized as having normal shape, size, position and echogenicity for this breed. The phrenic vasculature, glandular echogenicity and detail were unremarkable. Capsule, cortex, and medullary definition were normal for this age patient. The left adrenal gland measured 0.50 cm. The right adrenal gland measured 0.50 cm.

Spleen

The **spleen** presented a smooth homogeneous parenchyma hyperechoic to liver and renal cortical parenchyma. The capsule was smooth without noticeable expansion or deviation from within the spleen or adjacent pathology. The splenic vasculature demonstrated normal volume without signs of congestion or thrombosis. No sonographic evidence of acute or chronic inflammatory, neoplastic, or infarctual changes were noted.

Liver

The **liver** images submitted revealed subjectively normal liver size, contour, and structure. Parenchymal echogenicity was naturally coarse and hypoechoic to the spleen. Vascular and biliary tracts were of normal volume with no evidence of congestion. The gallbladder presented acceptably thin walls with primarily anechoic content. The cystic and common bile ducts were normal. No pathological hepatic lymphadenopathy was evident. No overt structural evidence of inflammatory, infiltrative or regenerative pathology was evident.

Gastrointestinal

A minor amount of non-shadowing, non-obstructive ingesta was noted in the **stomach**. Transit of chyme into the small intestine was normal. Curvilinear patterns were maintained throughout the GI tract. No evidence of pathology. No obstructive or overt infiltrative disease was noted. No associated abnormal lymphatic activity was noted. Soft stool noted in the colon.



PATIENT

Pancreas

Buster Green

The base and limbs of the **pancreas** were observed to be largely isoechoic to surrounding omental fat. Pancreatic duct and capsular contour were acceptably normal and parenchyma respected normal curvilinear patterns. No overt evidence of active inflammatory or neoplastic disease was noted.

SPECIES

Canine

ULTRASONOGRAPHIC FINDINGS

- Soft stool in the colon, unremarkable abdomen otherwise

BREED

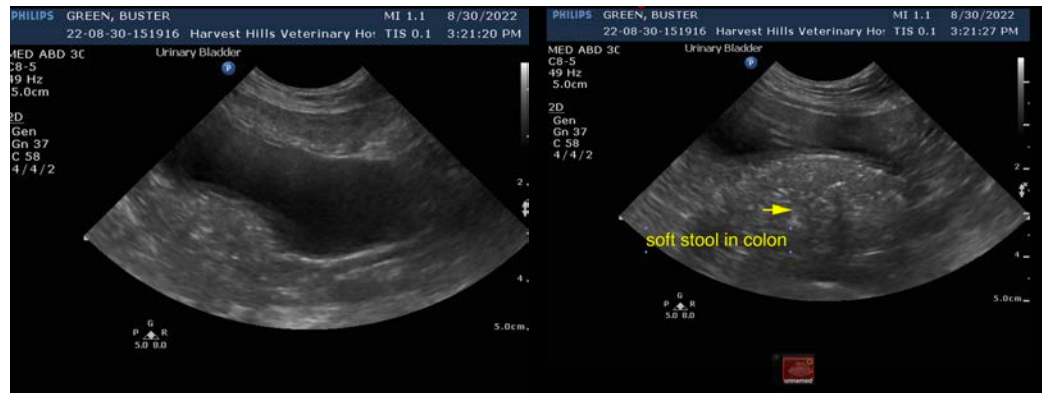Boxer

INTERPRETATION OF THE FINDINGS & FURTHER RECOMMENDATIONS

No evidence of lower urinary tract disease contributing to the clinical signs. Primary incontinence, occult UTI possible.

SEX

Neutered Male



AGE

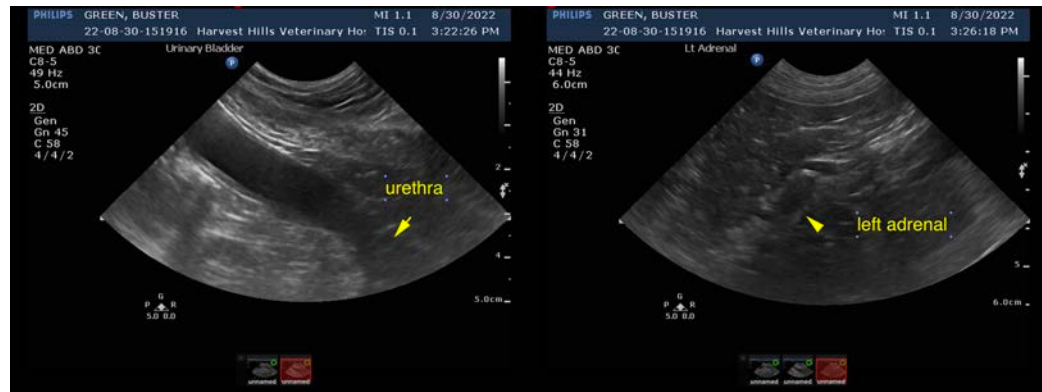
9 Years 9 Months

WEIGHT

80.9 Pounds

INTERPRETED BY

Eric Lindquist, DMV
DABVP, Cert. IVUSS



IMAGING PERFORMED BY

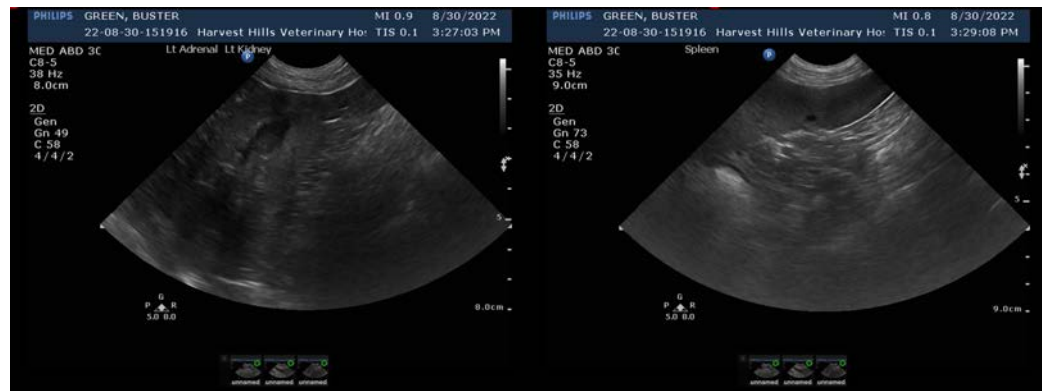
Dr. Jonathan Moss

HOSPITAL NAME

Harvest Hills VH

REFERRING VET

Dr. Jonathan Moss



INVOICE

40887

DATE

8/30/22



PATIENT

Buster Green

SPECIES

Canine

BREED

Boxer

SEX

Neutered Male

AGE

9 Years 9 Months

WEIGHT

80.9 Pounds

INTERPRETED BY

Eric Lindquist, DMV

DABVP, Cert. IVUSS

IMAGING PERFORMED BY

Dr. Jonathan Moss

HOSPITAL NAME

Harvest Hills VH

REFERRING VET

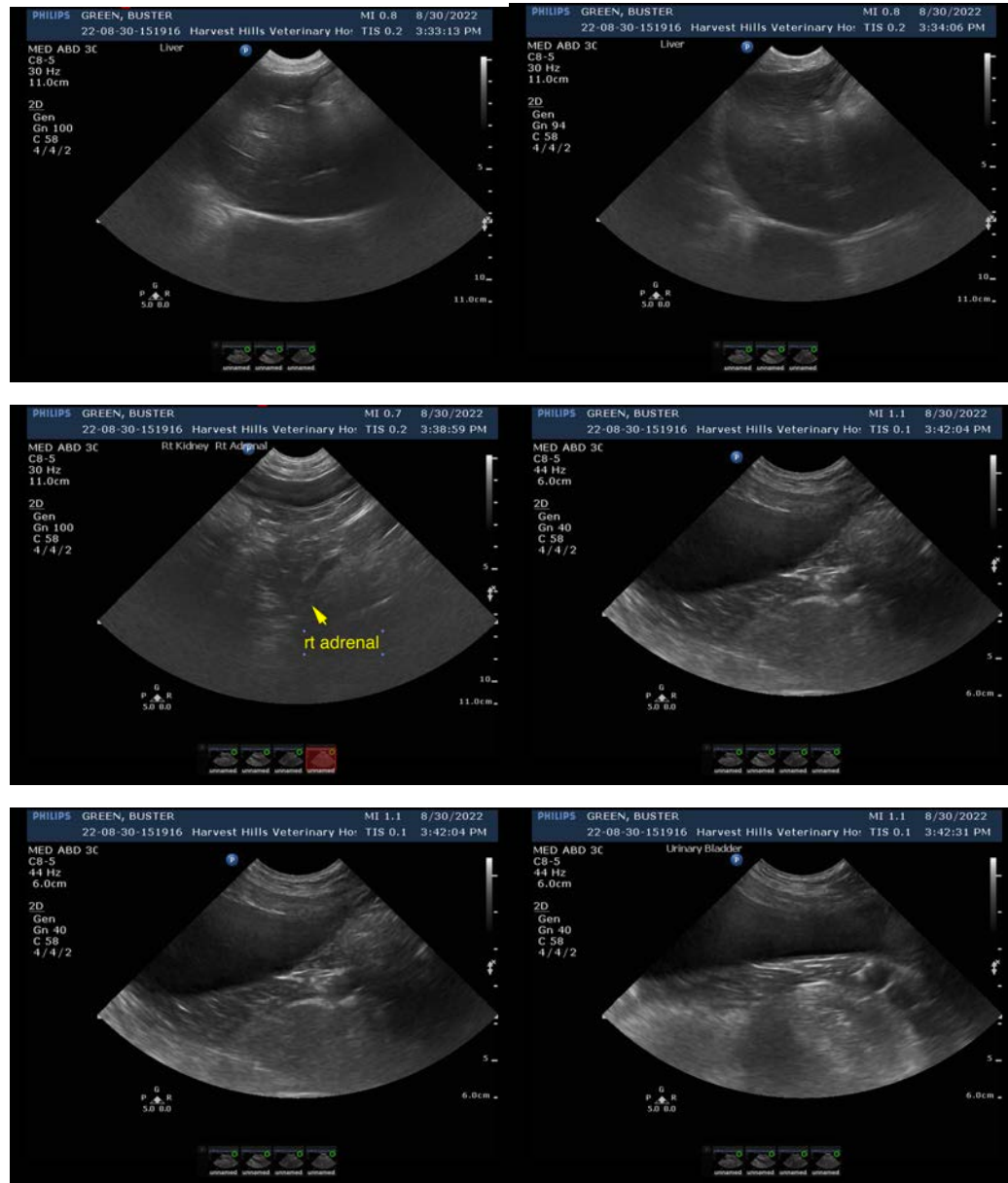
Dr. Jonathan Moss

INVOICE

40887

DATE

8/30/22



The information and recommendations provided are based on the images presented by the referring veterinarian/sonographer. No evaluation can be communicated regarding pathology that was not visible in the image/video clips provided.

Thank you for this referral. If the clinical or image interpretation does not parallel your findings or if I can be of any further assistance please contact me.

Eric Lindquist, DMV, DABVP, Cert. IVUSS, CEO of SonoPath.com

info@SonoPath.com