



**PATIENT**

Benny Ioannidis

**SPECIES**

Feline

**BREED**

Russian Blue

**SEX**

Neutered Male

**AGE**

2009

**WEIGHT**

7.15 Pounds

**INTERPRETED BY**

Eric Lindquist, DMV  
DABVP, Cert IVUSS

**IMAGING PERFORMED BY**

Denise Bruno, LVT,  
RDMS

**HOSPITAL NAME**

Kenilworth AH

**REFERRING VET**

Dr. Mansour

**INVOICE**

40886

**DATE**

8/30/22

**PRESENTING CLINICAL SIGNS**

Evaluate for neoplasia. Abnormal labs - attached.

**ULTRASONOGRAPHIC EXAMINATION OF THE ABDOMEN**

**Urinary System**

The **urinary bladder** was largely normal with a mural cyst at the apex. Apical ventral wall measured 1.24 cm x 0.43 cm.

The **kidneys** revealed infarcts and cortical collapse with areas of mineralization. The right kidney was slightly subnormal in size at 3.1 cm. The left kidney measured 3.83 cm with thickened, irregular cortices and loss of corticomedullary definition.

**Adrenal Glands**

The regions of the **adrenal glands** were unremarkable.

**Spleen**

The **spleen** was mildly enlarged with uniform, but subtly micronodular parenchyma, and undulating capsular contour. This is consistent with reactive spleen owing to immune stimulus or early infiltrative disease such as mast cell disease or lymphoma. 25-gauge FNA would be ideal if weight loss is an issue to differentiate early round cell neoplasia versus splenitis or reactive spleen all of which can present in this manner.

**Liver**

The **liver** was mildly swollen and presented increased portal markings. Trace amounts of free fluid noted between the liver lobes. The gallbladder was unremarkable.

**Gastrointestinal**

The **stomach** itself was unremarkable. The colon revealed an infiltrative pattern, creating a mass measuring 4.7 cm x 1.5 cm. Minor variable intestinal thickening elsewhere. Minor amount of stasis noted in the colon prior to the mass. Mesenteric lymph node were enlarged, rounded and hypoechoic, measuring up to 1.0 cm.

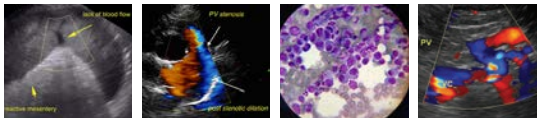
**Pancreas**

The **pancreas** presented undulating contour and dilated duct of 0.22 cm. The left limb measured 0.91 cm.

**ULTRASONOGRAPHIC FINDINGS**

- Colonic mass
- Dystrophic kidneys with calculi and infarcts
- Swollen irregular liver with slight free fluid – strong concern for multicentric round cell neoplasia.
- Urinary bladder cyst
- Enlarged, micronodular spleen
- Dilated pancreatic duct

**INTERPRETATION OF THE FINDINGS & FURTHER RECOMMENDATIONS**



**PATIENT**

Benny Ioannidis

Colonic, lymph node, splenic, and hepatic FNAs all indicated. Prognosis is guarded to poor. Carcinoma with reactive spleen and lymph nodes possible, yet less likely.

**SPECIES**

Feline

**BREED**

Russian Blue

**SEX**

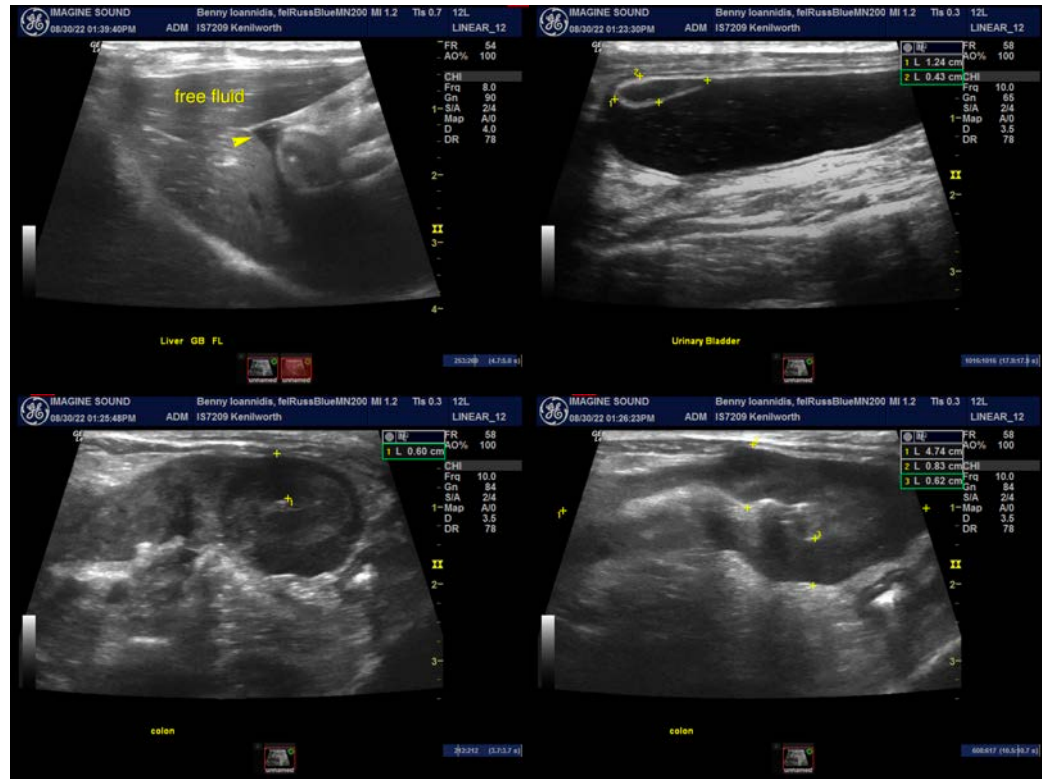
Neutered Male

**AGE**

2009

**WEIGHT**

7.15 Pounds



**INTERPRETED BY**

Eric Lindquist, DMV  
DABVP, Cert IVUS

**IMAGING PERFORMED BY**

Denise Bruno, LVT,  
RDMS

**HOSPITAL NAME**

Kenilworth AH

**REFERRING VET**

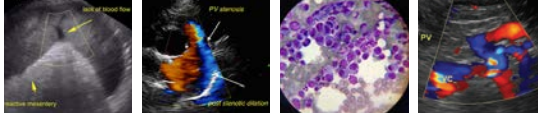
Dr. Mansour

**INVOICE**

40886

**DATE**

8/30/22



**PATIENT**

Benny Ioannidis

**SPECIES**

Feline

**BREED**

Russian Blue

**SEX**

Neutered Male

**AGE**

2009

**WEIGHT**

7.15 Pounds

**INTERPRETED BY**

Eric Lindquist, DMV  
DABVP, Cert IVUSS

**IMAGING  
PERFORMED BY**

Denise Bruno, LVT,  
RDMS

**HOSPITAL NAME**

Kenilworth AH

**REFERRING VET**

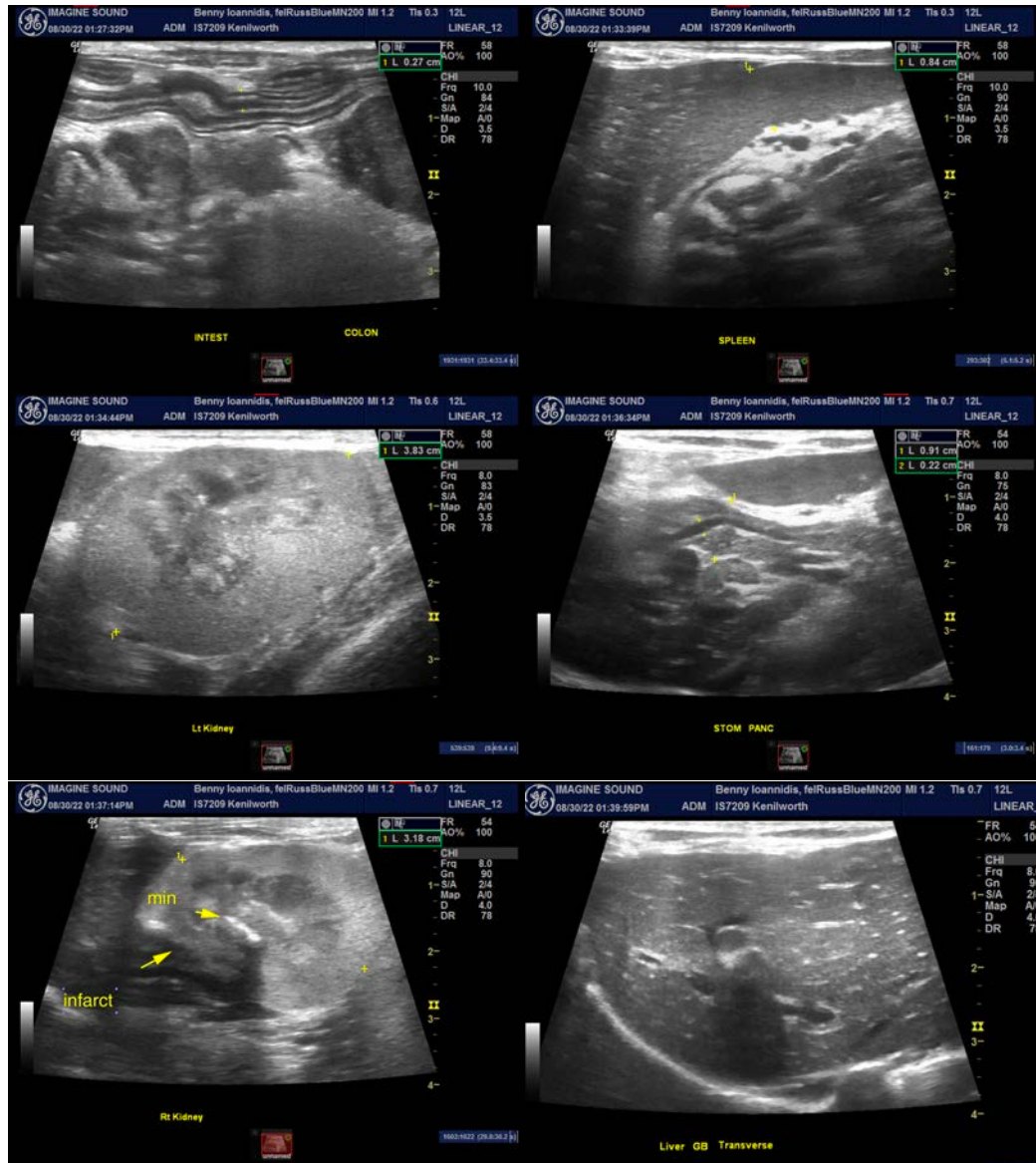
Dr. Mansour

**INVOICE**

40886

**DATE**

8/30/22



The information and recommendations provided are based on the images presented by the referring veterinarian/sonographer. No evaluation can be communicated regarding pathology that was not visible in the image/video clips provided.

Thank you for this referral. If the clinical or image interpretation does not parallel your findings or if I can be of any further assistance please contact me.

**Eric Lindquist, DMV, DABVP, Cert. IVUSS, CEO of SonoPath.com**

[info@SonoPath.com](mailto:info@SonoPath.com)