

**PATIENT PRESENTING CLINICAL SIGNS**

Senna Verbunt

History: Sudden onset of lethargy and fever and anorexia. Obvious swelling in neck palpable. High WBCs on bloodwork. Has free reign of large property and does get into stuff. Started Clavaseptin, Famotidine and Metacam and still has mild fever today.

**SPECIES**

Canine

Abnormal PE/Chem/CBC/UA Results: please see attached radiograph

**BREED**

Airedale Terrier

**LIMITED ULTRASONOGRAPHIC EXAMINATION**

The left cervical region in this patient was imaged. The salivary glands and subcutaneous tissue were unremarkable, however, a 2.5 cm – 2.0 cm mixed hypoechoic abscess was noted with surrounding cellulitis and edema. Linear foci were present within the abscess suggestive for penetrating foreign body. The abscess appeared to involve the esophagus, likely its derivation such as an ingested foreign body. Left retropharyngeal lymph node was enlarged with a reactive pattern, likely separative and hypoechoic, measured 2.0 cm x 1.0 cm. The trachea and carotid arteries were not involved; however, the abscess does impinge upon the left branch of the carotid artery.

**SEX**

Intact Female

**AGE**

1 years

**ULTRASONOGRAPHIC FINDINGS**

- Left retropharyngeal abscess with regional lymphadenopathy and cellulitis, likely involving the esophagus

**WEIGHT**

24 kg

**INTERPRETATION OF THE FINDINGS & FURTHER RECOMMENDATIONS**

Surgical intervention recommended. CT evaluation with contrast would be ideal prior to surgery, however, the linear focus would suggest a penetrating foreign body, possible bone or similar, likely deriving from the esophagus.

**INTERPRETED BY**

Eric Lindquist, DMV  
DABVP, Cert. IVUSS

**IMAGING PERFORMED BY**

Crystal Hill

**HOSPITAL NAME**

Grand River VH

**REFERRING VET**

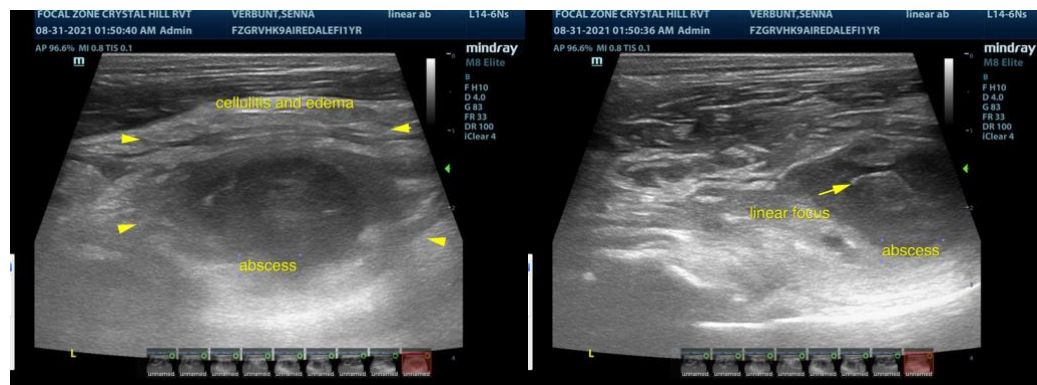
Robinson

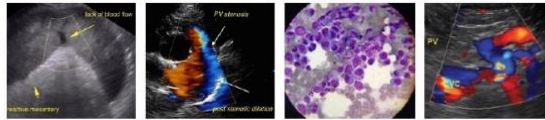
**INVOICE**

12879

**DATE**

8/30/21





**PATIENT**

Senna Verbunt

**SPECIES**

Canine

**BREED**

Airedale Terrier

**SEX**

Intact Female

**AGE**

1 years

**WEIGHT**

24 kg

**INTERPRETED BY**

Eric Lindquist, DMV  
DABVP, Cert. IVUSS

**IMAGING  
PERFORMED BY**

Crystal Hill

**HOSPITAL NAME**

Grand River VH

**REFERRING VET**

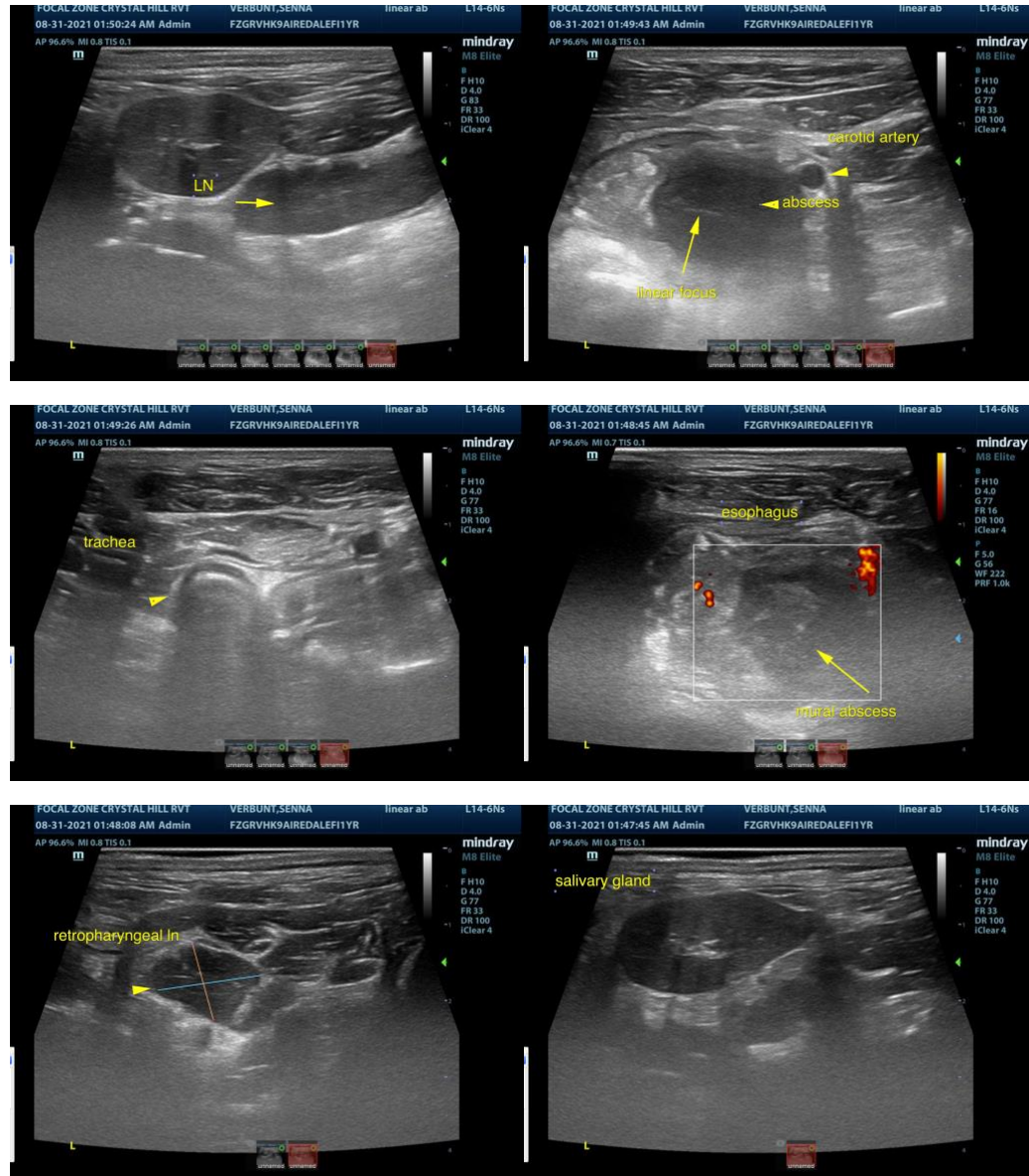
Robinson

**INVOICE**

12879

**DATE**

8/30/21



The information and recommendations provided are based on the images presented by the referring veterinarian. No evaluation can be communicated regarding pathology that was not visible in the image/video clips provided.

Thank you for this referral. If the clinical or image interpretation does not parallel your findings or if I can be of any further assistance please contact me.

**Eric Lindquist**, DMV, DABVP, Cert. IVUSS, CEO of SonoPath.com  
Eric.Lindquist@SonoPath.com