



PATIENT PRESENTING CLINICAL SIGNS

Buddy Ghiardi

History: Very short history known from other vet clinic--sounds like collapsing/syncopal episodes being seen

SPECIES

Canine

ULTRASONOGRAPHIC EXAMINATION OF THE HEART

BREED

Shih Tzu

SEX

Neutered male

AGE

12 years

The echocardiogram in this patient demonstrated normal **left atrial** size based on 3 separate methods of LA evaluation. **Mitral** valve insufficiency was noted with moderate filling of the left atrium. However, there was no volume overload present. There is no evidence of prolapse. The **left ventricle** presented thicknesses with linear contour and was not dilated nor restricted. The **myocardium** presented normal echogenicity without subjective evidence of significant fibrotic or ischemic disease. **Contractility** of the ventricular walls was adequate and in normal range for this patient evidenced by the fractional shortening measurement and subjective evaluation of the different regions of the myocardium. The **left ventricular outflow** tract demonstrated normal laminar flow and subjective structural integrity. The **right atrium** and auricle revealed normal size, structure and content. No evidence of masses was noted. **Tricuspid** insufficiency is noted as well. The **right ventricle** was of normal size (1/3 diameter of LV), chordae structure, myocardial echogenicity and thickness. **Pulmonary outflow** tract assessment revealed normal valve structure, laminar flow, and diameter (approx. 1:1 pa/ao ratio). No visible **pericardial** or free pleura fluid was noted. The cranial **mediastinum and pericardial and extra-cardiac** regions were free of masses in the visible window. No hepatic vein dilation was noted.

WEIGHT

13 lbs

INTERPRETED BY

Eric Lindquist, DMV
DABVP, Cert. IVUSS

IMAGING PERFORMED BY

Dr. Nyberg

HOSPITAL NAME

Stuga North VC

REFERRING VET

Dr. Nuberg

CANINE CARDIAC PARAMETERS	MR VMAX (m/s)	TR VMAX (m/s)	LA/AO (Boon method)	LA/AO (Heart Base; Swe)	FS (%)	EF (%)	EPSS (cm)
NORMAL PARAMETER	4.5-5.5	<2.7	1.3	<1.6	28-40	40-100	<0.6
PATIENT	5.0		1.15	1.4	35	80	0.1
CANINE CARDIAC PARAMETERS	HR (BPM)	AV VMAX (m/s)	PV MAX (m/s)	BODY WEIGHT	LA (2D short axis Base view) (cm)	LVIDd (Avg; 2D and m-mode short axis) (cm)	LVIDs (Avg; 2D and m-mode short axis) (cm)
NORMAL PARAMETER	50-100	0.7-1.7	0.7-1.6				
PATIENT		NM	NM	13 lbs	2.1	2.4	

ULTRASONOGRAPHIC FINDINGS

Mitral and tricuspid insufficiency, compensated at this time.

No volume overload.

INVOICE

91554

DATE

8/30/21



PATIENT

Buddy Ghiardi

SPECIES

Canine

BREED

Shih Tzu

SEX

Neutered male

AGE

12 years

WEIGHT

13 lbs

INTERPRETED BY

Eric Lindquist, DMV
DABVP, Cert. IVUSS

IMAGING PERFORMED BY

Dr. Nyberg

HOSPITAL NAME

Stuga North VC

REFERRING VET

Dr. Nuberg

INVOICE

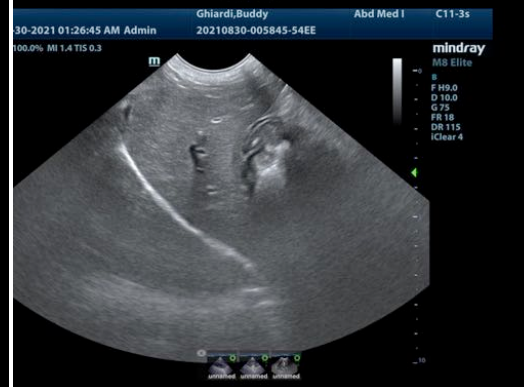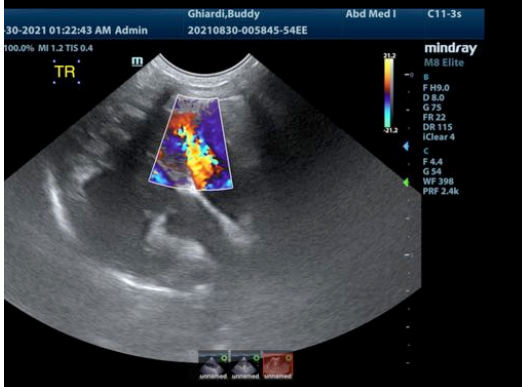
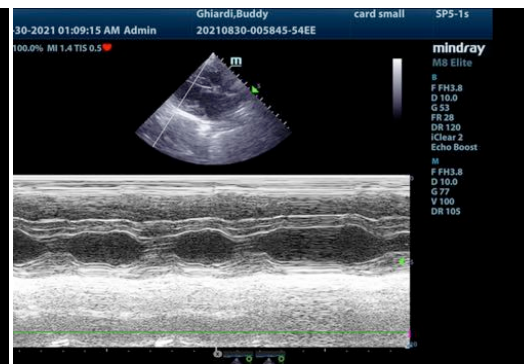
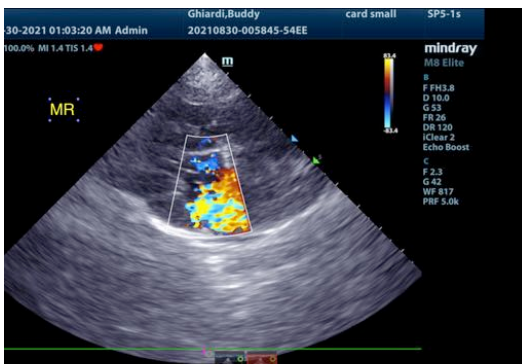
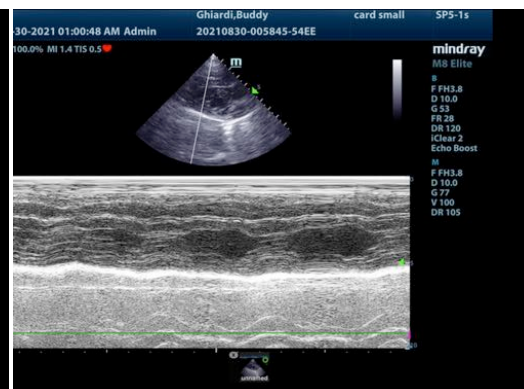
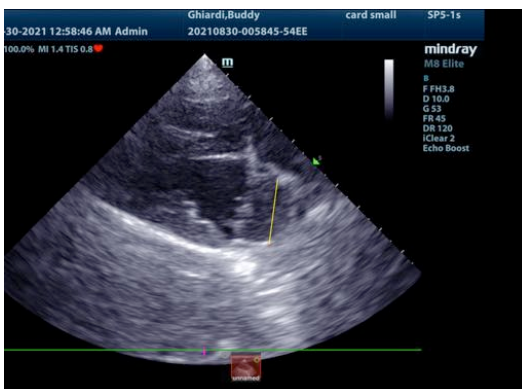
91554

DATE

8/30/21

INTERPRETATION OF THE FINDINGS & FURTHER RECOMMENDATIONS

Syncope may still be an issue in this patient, but would be owing to paroxysmal arrhythmia. There is no volume overload or cardiac dysfunction at this point despite mitral and tricuspid insufficiency. This is consistent with stage B1 valvular disease. I recommend a Holter monitor in this patient. Blood pressure measurements are warranted to assess for any systemic hypertension, which may be playing a role. Holter monitor may be obtained from our office with cardiologist review. Full CNS examination and orthopedic examination is warranted to assess if associated disease is playing a role. No cardiac medication is recommended at this time.



The information and recommendations provided are based on the images presented by the referring veterinarian. No evaluation can be communicated regarding pathology that was not visible in the



PATIENT

image/video clips provided.

Buddy Ghiardi

Thank you for this referral. If the clinical or image interpretation does not parallel your findings or if I can be of any further assistance please contact me.

SPECIES

Canine

Eric Lindquist, DMV, DABVP, Cert. IVUSS, CEO of SonoPath.com
info@SonoPath.com

BREED

Shih Tzu

SEX

Neutered male

AGE

12 years

WEIGHT

13 lbs

INTERPRETED BY

Eric Lindquist, DMV
DABVP, Cert. IVUSS

**IMAGING
PERFORMED BY**

Dr. Nyberg

HOSPITAL NAME

Stuga North VC

REFERRING VET

Dr. Nuberg

INVOICE

91554

DATE

8/30/21