



PATIENT

Wally Turner

SPECIES

Canine

BREED

Great Dane

SEX

Neutered male

AGE

7 years

WEIGHT

135.9 lbs

INTERPRETED BY

Eric Lindquist, DMV
DABVP, Cert. IVUSS

IMAGING PERFORMED BY

Dr. Green

HOSPITAL NAME

Healing Spirit AWC

REFERRING VET

Dr. Green

INVOICE

46421

DATE

8/2/23

PRESENTING CLINICAL SIGNS

History: Thoracic mass with hemorrhagic pleural effusion. Mass cytology consistent with a round cell tumor, pathology review favoring a mast cell tumor. No overtly neoplastic cells present in the effusion. CT scheduled for Friday. Abdominal ultrasound performed to evaluate for presence of intra-abdominal neoplasia

ULTRASONOGRAPHIC EXAMINATION OF THE ABDOMEN

Urinary System

The **urinary bladder**, trigone, and pelvic urethra presented normal thicknesses and normal tone. The ureters were not visible which is normal. No uroliths or sediment were visualized and anechoic urine was present. No evidence of inflammatory or neoplastic changes was noted. Ureteral papillae were normal.

The **kidneys** revealed normal size and structure, corticomedullary definition and ratio for this age. The cortices presented largely uniform texture with normal echogenic relationship to liver and spleen. Medullary structure differed distinctly from the cortex and no evidence of pelvic dilation was present. The capsules were acceptably uniform without significant irregularities. The left kidney measured 10.0 cm. The right kidney measured 8.5 cm.

Adrenal Glands

The **adrenal glands** were not visualized.

Spleen

The **spleen** presented a smooth homogeneous parenchyma hyperechoic to liver and renal cortical parenchyma. The capsule was smooth without noticeable expansion or deviation from within the spleen or adjacent pathology. The splenic vasculature demonstrated normal volume without signs of congestion or thrombosis. No sonographic evidence of acute or chronic inflammatory, neoplastic, or infarctual changes was noted.

Liver

The **liver** images from right and left intercostal as well as subcostal views revealed subjectively normal liver size, contour, and structure. Some age-related parenchymal remodeling was noted but likely not clinically significant at this time. Vascular and biliary tracts were of normal volume and no evidence of congestion was noted. The gallbladder wall was echogenic, mildly thickened and mineralized. This is consistent with porcelain gallbladder. Pleural effusion was noted through the diaphragm.

Gastrointestinal

Examination of the **gastrointestinal tract** revealed a stomach and intestine free of stasis, of normal wall thickness, acceptable curvilinear mural detail, and peristaltic activity. Small and large intestine



PATIENT

Wally Turner

demonstrated normal luminal chyme and stool consistency respectively. No obstructive or overt infiltrative disease was noted. No associated abnormal lymphatic activity was noted.

SPECIES

Canine

Pancreas

The base and limbs of the **pancreas** were observed to be largely isoechoic to surrounding omental fat. Pancreatic duct and capsular contour were acceptably normal and parenchyma respected normal curvilinear patterns. No overt evidence of active inflammatory or neoplastic disease was noted.

BREED

Great Dane

ULTRASONOGRAPHIC FINDINGS

Age related abdominal changes with porcelain gallbladder.

SEX

Neutered male

INTERPRETATION OF THE FINDINGS & FURTHER RECOMMENDATIONS

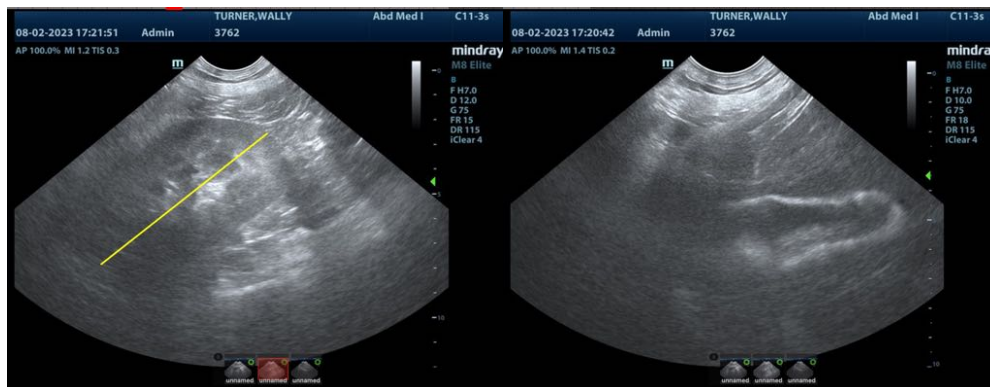AGE

7 years

There was no evidence of primary disease that would be responsible for the thoracic presentation.

WEIGHT

135.9 lbs

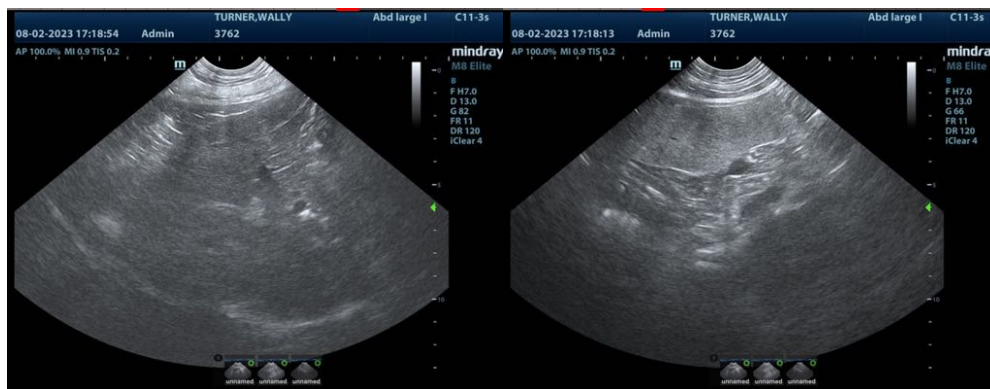

INTERPRETED BY

Eric Lindquist, DMV
DABVP, Cert. IVUS

IMAGING PERFORMED BY

Dr. Green



HOSPITAL NAME

Healing Spirit AWC

REFERRING VET

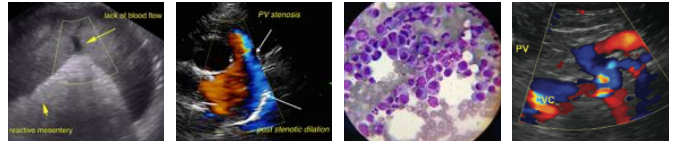
Dr. Green

INVOICE

46421

DATE

8/2/23



PATIENT

Wally Turner

SPECIES

Canine

BREED

Great Dane

SEX

Neutered male

AGE

7 years

WEIGHT

135.9 lbs

INTERPRETED BY

Eric Lindquist, DMV
DABVP, Cert. IVUSS

**IMAGING
PERFORMED BY**

Dr. Green

HOSPITAL NAME

Healing Spirit AWC

REFERRING VET

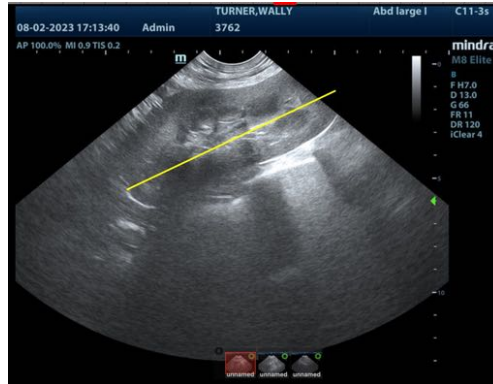Dr. Green

INVOICE

46421

DATE

8/2/23



The information and recommendations provided are based on the images presented by the referring veterinarian/sonographer. No evaluation can be communicated regarding pathology that was not visible in the image/video clips provided.

Thank you for this referral. If the clinical or image interpretation does not parallel your findings or if I can be of any further assistance please contact me.

Eric Lindquist, DMV, DABVP, Cert. IVUSS, CEO of SonoPath.com
info@SonoPath.com