SonoPath
Clinical Sonography & Telecytology

EDUCATIONAL TELECONSULTATION SERVICES™

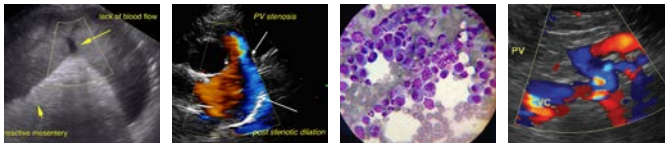

SonoPath.com™
1-800-838-4268 info@sonopath.com

PATIENT
Sissy Gaver

SPECIES
Canine

BREED
Shih Tzu

SEX
Spayed Female

AGE
11 Years

WEIGHT
10.5 Pounds

INTERPRETED BY
Eric Lindquist, DMV
DABVP, Cert. IVUSS

IMAGING PERFORMED BY
Dr. Megan Bray

HOSPITAL NAME
Taylorsville VC

REFERRING VET
Dr. Megan Bray

INVOICE
44641

DATE
8/3/23

PRESENTING CLINICAL SIGNS

P was treated for an infected AG 5/2/23 when owner noticed some soft stools and a little blood in the stool which has resolved and a UTI in Feb 2023, which also resolved at that time of treatment. Owner reports that p hasn't had a great appetite over the last few months, seems to be uncomfortable and gassy but no vomiting has been seen. Will occasionally pace at night and owner gives a small dose of Meloxicam and p settles and sleeps well.

Abnormal PE/Chem/CBC/UA Results: P has grade 3 dental disease on remaining teeth (mostly 309/409). P doesn't have upper PM/M. A small lipoma on chest and possible adenoma near right shoulder. Abdomen palpates soft and nonpainful. No heart murmur or arrhythmia detected. Lab work overall is unremarkable, we are currently waiting on UA results.

ULTRASONOGRAPHIC EXAMINATION OF THE ABDOMEN

Urinary System

The **urinary bladder** itself presented normal thicknesses and normal tone. The ureters were not visible which is normal. No uroliths or sediment were visualized and anechoic urine was present. No evidence of inflammatory or neoplastic changes were noted. Ureteral papillae were normal.

The pelvic urethra revealed mineralized thickening at a maximum width of 1.0 cm, strongly consistent with urethral carcinoma.

The **kidneys** revealed largely normal size and structure, corticomedullary definition and ratio (cortex 1/3 of medulla) were essentially maintained with some age-related loss of curvilinear patterns regarding the capsule and C/M junction. The cortices presented largely uniform texture with some increased echogenicity expected for his age patient. Medullary structure differed distinctly from that of the cortex and no evidence of pelvic dilation was present. The right kidney measured 3.7 cm. The left kidney measured 3.5 cm. Pinpoint mineralizations noted in both kidneys.

Adrenal Glands

Both **adrenal glands** were visualized and recognized as having normal shape, size, position and echogenicity for this breed. The phrenic vasculature, glandular echogenicity and detail were unremarkable. Capsule, cortex, and medullary definition were normal for this age patient. The left adrenal gland measured 0.50 cm. The right adrenal gland measured 0.50 cm.

Spleen

The **spleen** presented a smooth homogeneous parenchyma hyperechoic to liver and renal cortical parenchyma. The capsule was smooth without noticeable expansion or deviation from within the spleen or adjacent pathology. The splenic vasculature demonstrated normal volume without signs of congestion or thrombosis. No sonographic evidence of acute or chronic inflammatory, neoplastic, or infarctual changes were noted.

Liver

The **liver** images submitted revealed subjectively normal liver size, contour, and structure. Parenchymal echogenicity was naturally coarse and hypoechoic to the spleen. Vascular and biliary tracts were of normal volume with no evidence of congestion. The gallbladder presented acceptably thin walls with primarily anechoic content. The cystic and common bile ducts were normal. No pathological hepatic

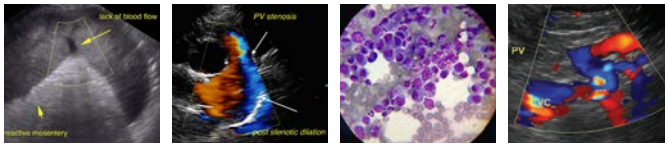

SonoPath.com™
1-800-838-4268 info@sonopath.com

PATIENT
Sissy Gaver

SPECIES
Canine

BREED
Shih Tzu

SEX
Spayed Female

AGE
11 Years

WEIGHT
10.5 Pounds

INTERPRETED BY
Eric Lindquist, DMV
DABVP, Cert. IVUSS

IMAGING PERFORMED BY
Dr. Megan Bray

HOSPITAL NAME
Taylorsville VC

REFERRING VET
Dr. Megan Bray

INVOICE
44641

DATE
8/3/23

lymphadenopathy was evident. No overt structural evidence of inflammatory, infiltrative or regenerative pathology was evident.

Gastrointestinal

Examination of the **gastrointestinal tract** revealed a stomach and intestine free of stasis, of normal wall thickness, acceptable curvilinear mural detail, and peristaltic activity. Small and large intestine demonstrated normal luminal chyme and stool consistency respectively. No obstructive or overt infiltrative disease was noted. No associated abnormal lymphatic activity was noted.

Pancreas

The base and limbs of the **pancreas** were observed to be largely isoechoic to surrounding omental fat. Pancreatic duct and capsular contour were acceptably normal and parenchyma respected normal curvilinear patterns. No overt evidence of active inflammatory or neoplastic disease was noted.

ULTRASONOGRAPHIC FINDINGS

- Mineralized urethral thickening – strong concern for carcinoma.
- Age related renal changes with slight mineralization.

INTERPRETATION OF THE FINDINGS & FURTHER RECOMMENDATIONS

Cystoscopy and urethral biopsies would be ideal. BRAF testing and cytospin of free catch urine sample could be considered, yet cystoscopy would be the best option in this patient. Referral for eventual stent placement or ultrasound guided laser ablation would be warranted if available in your region.

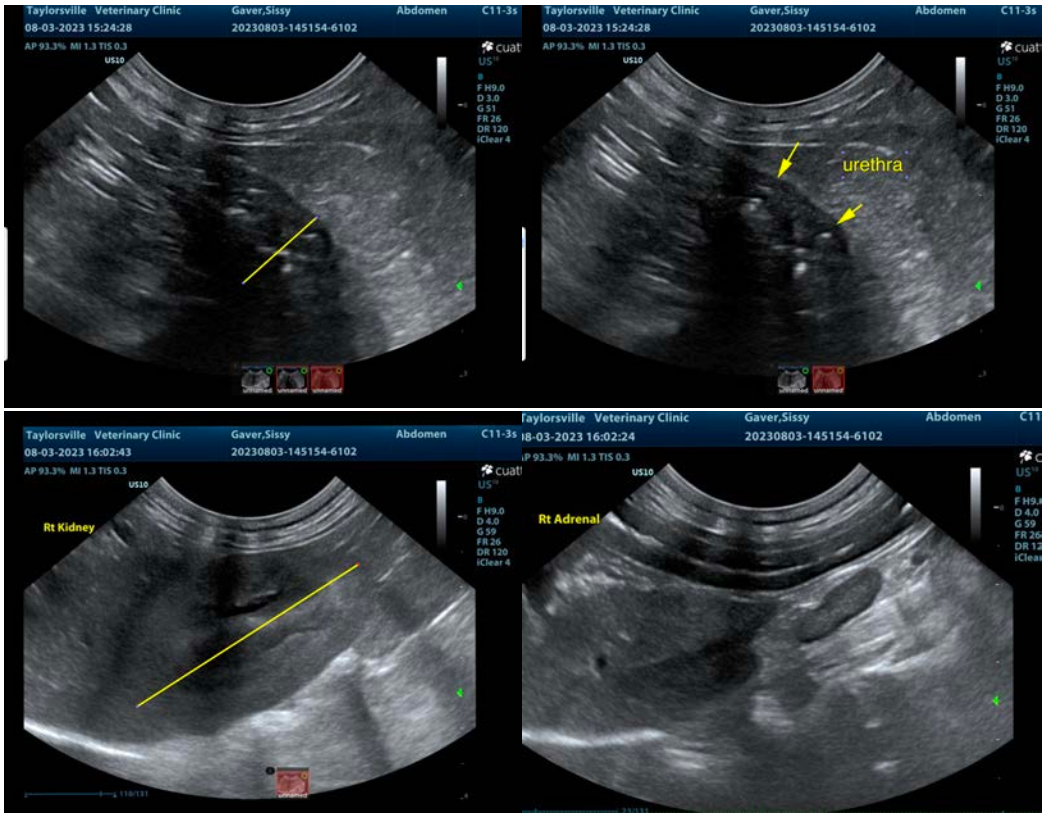

SonoPath
Clinical Sonography & Telecytology

EDUCATIONAL TELECONSULTATION SERVICES™

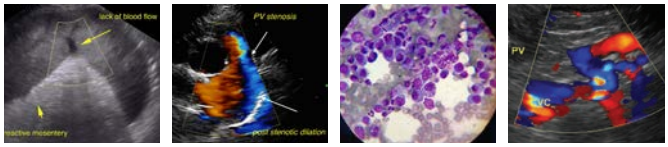

SonoPath.com™
1-800-838-4268 info@sonopath.com

PATIENT

Sissy Gaver

SPECIES

Canine

BREED

Shih Tzu

SEX

Spayed Female

AGE

11 Years

WEIGHT

10.5 Pounds

INTERPRETED BY

Eric Lindquist, DMV

DABVP, Cert. IVUSS

IMAGING PERFORMED BY

Dr. Megan Bray

HOSPITAL NAME

Taylorsville VC

REFERRING VET

Dr. Megan Bray

INVOICE

44641

DATE

8/3/23

The information and recommendations provided are based on the images presented by the referring veterinarian/sonographer. No evaluation can be communicated regarding pathology that was not visible in the image/video clips provided.

Thank you for this referral. If the clinical or image interpretation does not parallel your findings or if I can be of any further assistance please contact me.

Eric Lindquist, DMV, DABVP, Cert. IVUSS, CEO of SonoPath.com

info@SonoPath.com