



**PATIENT** **PRESENTING CLINICAL SIGNS**

Sasha Doyle

History: Patient was seen 6/7/23 for not seeming herself for a few months. UA and Senior BW was performed. Senior BW: CBC: low retic-hgb. Chem: slight hyperglycemia, slight hyperglobulinemia, increased ALP, hypercholesterolemia, low T4 (0.5). UA: USG 1.017, proteinuria hematuria (urine collected via cysto). Patient was started on thryo-tabs 0.4 mg PO BID but did discuss with owner prior to starting that we could not rule out Cushing's therefore if thyroid medication was not improving patient's presentation then it would be recommended for LDDST. Patient improved somewhat on thryo tabs but was still drinking a lot and urinating a lot, patient was brought in for LDDST. LDDST result consistent with Cushing's but could not differentiate between pituitary and adrenal dependent.

**SPECIES**

Canine

**BREED**

Puggle

**SEX**

Spayed female

**AGE**

13 years

**WEIGHT**

40.5 lbs

**ULTRASONOGRAPHIC EXAMINATION OF THE ABDOMEN**

**Urinary System**

The **urinary bladder**, trigone, and pelvic urethra presented normal thicknesses and normal tone. The ureters were not visible which is normal. No uroliths or sediment were visualized and anechoic urine was present. No evidence of inflammatory or neoplastic changes was noted. Ureteral papillae were normal.

The **kidneys** revealed normal size and structure, corticomedullary definition and ratio for this age. The cortices presented largely uniform texture with normal echogenic relationship to liver and spleen. Medullary structure differed distinctly from the cortex. The capsules were acceptably uniform without significant irregularities. Slight pyelectasia was noted. Slight mineralization was noted in both kidneys. The left kidney measured 5.0 cm. The right kidney revealed a cortical infarct at the cranial pole.

**INTERPRETED BY**

Eric Lindquist, DMV  
DABVP, Cert. IVUSS

**Adrenal Glands**

Both adrenal glands were slightly swollen although the left adrenal gland was still within normal limits. The left adrenal gland was at the upper limits of normal and measured 0.7 cm. The right adrenal gland was mildly enlarged and measured 1.06 cm.

**IMAGING PERFORMED BY**

Meghan Myers, VMD

**Spleen**

**HOSPITAL NAME**

Hershire AH

The **spleen** presented a smooth homogeneous parenchyma hyperechoic to liver and renal cortical parenchyma. The capsule was smooth without noticeable expansion or deviation from within the spleen or adjacent pathology. The splenic vasculature demonstrated normal volume without signs of congestion or thrombosis. No sonographic evidence of acute or chronic inflammatory, neoplastic, or infarctual changes was noted.

**REFERRING VET**

Dr. Gallisdorfer

**Liver**

**INVOICE**

46432

The **liver** revealed multi-focal, hypoechoic nodular changes with mild disruption of architecture. Mild hepatic swelling was noted with slightly increased portal markings. The gallbladder and common bile duct were unremarkable.

**DATE**

8/3/23



**PATIENT**

Sasha Doyle

**SPECIES**

Canine

**BREED**

Puggle

**SEX**

Spayed female

**AGE**

13 years

**WEIGHT**

40.5 lbs

**INTERPRETED BY**

Eric Lindquist, DMV  
DABVP, Cert. IVUSS

**IMAGING PERFORMED BY**

Meghan Myers, VMD

**HOSPITAL NAME**

Hershire AH

**REFERRING VET**

Dr. Gallisdorfer

**INVOICE**

46432

**DATE**

8/3/23

**Gastrointestinal**

Examination of the **gastrointestinal tract** revealed a stomach and intestine free of stasis, of normal wall thickness, acceptable curvilinear mural detail, and peristaltic activity. Small and large intestine demonstrated normal luminal chyme and stool consistency respectively. No obstructive or overt infiltrative disease was noted. No associated abnormal lymphatic activity was noted.

**Pancreas**

The base and limbs of the **pancreas** were observed to be largely isoechoic to surrounding omental fat. Pancreatic duct and capsular contour were acceptably normal and parenchyma respected normal curvilinear patterns. No overt evidence of active inflammatory or neoplastic disease was noted.

**ULTRASONOGRAPHIC FINDINGS**

Nodular hyperplasia liver pattern with mild remodeling.

Prominent adrenal glands, potential emerging PDH.

Renal mineralization and pyelectasia.

**INTERPRETATION OF THE FINDINGS & FURTHER RECOMMENDATIONS**

FNA of the liver is indicated to ensure that neoplasia is not underlying. Full CNS, thoracic and orthopedic examination is warranted if not already performed given the vague clinical signs. However, emerging PDH is a strong potential. If any low-grade neurological signs are noted on exam then skull CT with contrast would be indicated to assess for expansive, pituitary tumor. Blood pressure measurements are also indicated.

**Efficient & Accurate Cushing's Work up-Lindquist**

**Notes regarding Cushing's Clinical Presentations:**

*Nearly all Cushing's dogs have SAP elevations and true PU/PD (USG < 1.025) and most are polyphagic.*

*Cushing's dogs are > 6 years and usually > 9 years old, usually have poor skin coats, body scores > 3/5, and are usually sedentary animals.*

*Its important to remember that Cushing's dogs usually look and play the part and other diseases cause false + stress related cortisol spikes. On rare occasion a Cushing's dog will not follow the rules but this is truly an exception.*

*Potential Cushing's patient workups can be costly and frustrating if not definitive and, in my experience, the non-definitive patient usually has something else going on that may be contributing to some of the clinical signs a Cushing's dog will have, especially SAP elevations or PU/PD. Based on this prelude of information I came up with the following algorithm in the spirit of diagnostic efficiency. The following suggested protocol is based on current available literature on Cushing's disease and extensive clinical-sonographic experience evaluation + Cushing's and False + LDDST & ACTH stim. cases in order to maximize the efficiency of a Cushing's workup in practice.*

**Screen first, workup second**

1) **UA:** Repeatable (2-3 urine samples) Urine specific gravity & urine cortisol/creatinine ratio (UCCR): If **repeatable USG < 10.20 and + UCCR** move to next step 2.



## PATIENT

Sasha Doyle

## SPECIES

Canine

## BREED

Puggle

## SEX

Spayed female

## AGE

13 years

## WEIGHT

40.5 lbs

## INTERPRETED BY

Eric Lindquist, DMV  
DABVP, Cert. IVUSS

## IMAGING PERFORMED BY

Meghan Myers, VMD

## HOSPITAL NAME

Hershire AH

## REFERRING VET

Dr. Gallisdorfer

## INVOICE

46432

## DATE

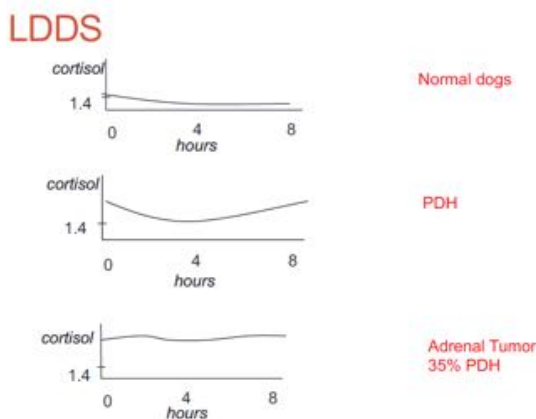
8/3/23

*Note: UA is inexpensive and easy to obtain and if UA criteria is not met for Cushing's then resources can be spent into other more pertinent diagnostics or left on hold until the UA criteria is met in emerging Cushing's cases.*

2) **Sonogram:** Does the patient **have concurrent disease** clinically or sonographically as non-Cushing's illness will influence the potential false + LDDST or even ACTH stim. The sonogram gives a global perspective of the internal health of the patient to be considered in the Cushing's workup as an assessment of concurrent disease. Is there a concurrent neoplastic process, UTI pancreatitis, mucocele....? Are the adrenals enlarged (Cushing's-PDH, stress, age related or breed variant), or atrophied (iatrogenic Cushing's or adrenal burnout), have asymmetric enlargement (Adrenal tumor, hyperplasia, adenoma, age related variant), or is there vascular invasion (Invasive pheo with false + UA criteria or adenocarcinoma or phrenic thrombosis)? The sonogram answers these questions proactively.

**Address & treat concurrent disease first before performing Cushing's testing or testing will be artificially altered increasing false negatives and positives.**

3) **LDDST** (0.01 D-Sodium phosphate mg/kg IV **with precise dosing\*\*\*\***) (Better screening test but plagued with false + but considered more specific than ACTH stim) Use if there is potential early Cushing's or if adrenal asymmetry present on sonogram suspecting tumor. Use LDDST in cats at a higher dose (0.1 mg/kg IV). **Interpretation LDDST:** Look at 8-hour post first: If > 1.4 = Cushing's. Then look at 4-hour: if > 1.4 or > 50% baseline = Cushing's. 4-hour do then 8-hour spike most consistent with PDH. Flat line high constant curve without dip more consistent with tumor but can be PDH. See attached graph.



Courtesy: Rebecca Berg DACVIM, DECVIM

4) **ACTH stim.** (Better confirming test but can have false +) Use if the patient "looks" Cushingoid or if bilateral adrenal enlargement is present, or high normal width on sonogram, or if iatrogenic Cushing's suspected (Cortisone Tx in past). ACTH stim is better for diagnosis of Addisons, Iatrogenic Cushing's, and Cushing's therapy monitoring but problematic with initial Cushing's diagnosis. First dx LDDST is suggested.

5) If **diabetic** then run both LDDST & ACTH stim but stabilize as much as possible first.

5) Run a **serial blood pressure** in a BP friendly non "white coat effect" atmosphere. Run at least 3 at different times over a few hours or when eating as the patient tends to be calm when eating or give Torbutrol when entering the facility. Cushing's hypertension is usually 150-180 systolic range while pheochromocytoma range is more often > 180 systolic.



**PATIENT**

Sasha Doyle

**SPECIES**

Canine

**BREED**

Puggle

**SEX**

Spayed female

**AGE**

13 years

**WEIGHT**

40.5 lbs

**INTERPRETED BY**

Eric Lindquist, DMV  
DABVP, Cert. IVUSS

**IMAGING PERFORMED BY**

Meghan Myers, VMD

**HOSPITAL NAME**

Hershire AH

**REFERRING VET**

Dr. Gallisdorfer

**INVOICE**

46432

**DATE**

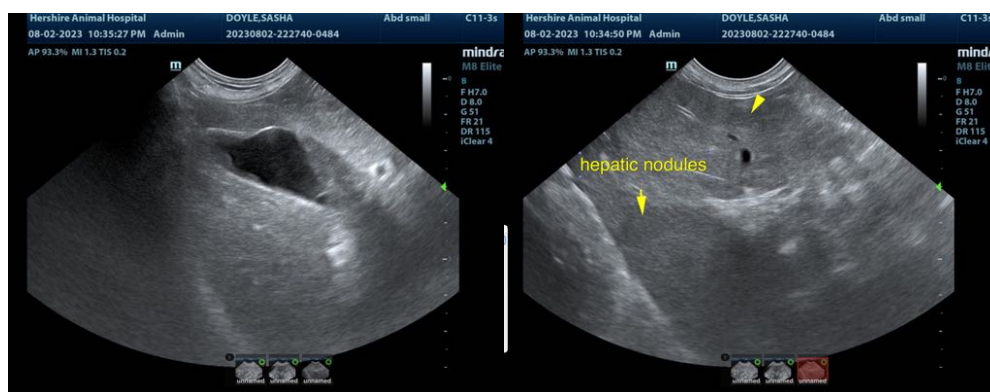
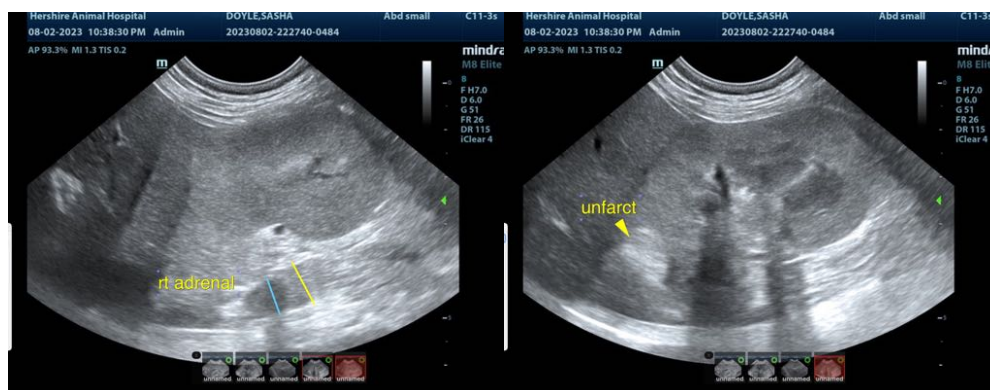
8/3/23

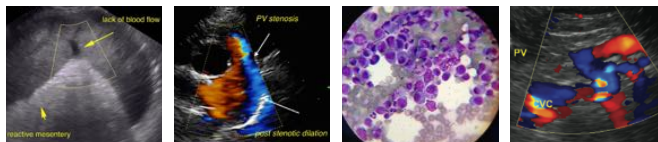
6) **Perform CT** of the pituitary to identify macro adenoma expansion if any lethargy or dullness or other central clinical CNS signs are minimally present. CT for adrenal may be more thorough for adrenalectomy surgical planning if ultrasound views of the CVC were problematic.

7) **Adrenectomy** for adrenal mass is prescribed then it is essential to stabilize the patient first regarding secondary disease such as organ dysfunction, hypertension, diabetes mellitus, hypernatremia, thromboembolic risk urinary and other infection in order to minimize potential for operative and postoperative complications as they are common in adrenalectomy. Trilostane stabilization therapy for Cushing's would be the first approach then address surgery and hypertension should be managed ideally < 160 systolic with ace inhibitors, phenoxybenzamine, or amlodipine.

Suggested reading:

Behrend EN, Kooistra HS, Nelson R, et al. Diagnosis of Spontaneous Canine Hyperadrenocorticism: 2012 ACVIM Consensus Statement (Small Animal). J Vet Intern Med 2013;27:1292-1304 .





**PATIENT**

Sasha Doyle

**SPECIES**

Canine

**BREED**

Puggle

**SEX**

Spayed female

**AGE**

13 years

**WEIGHT**

40.5 lbs

**INTERPRETED BY**

Eric Lindquist, DMV  
DABVP, Cert. IVUSS

**IMAGING PERFORMED BY**

Meghan Myers, VMD

**HOSPITAL NAME**

Hershire AH

**REFERRING VET**

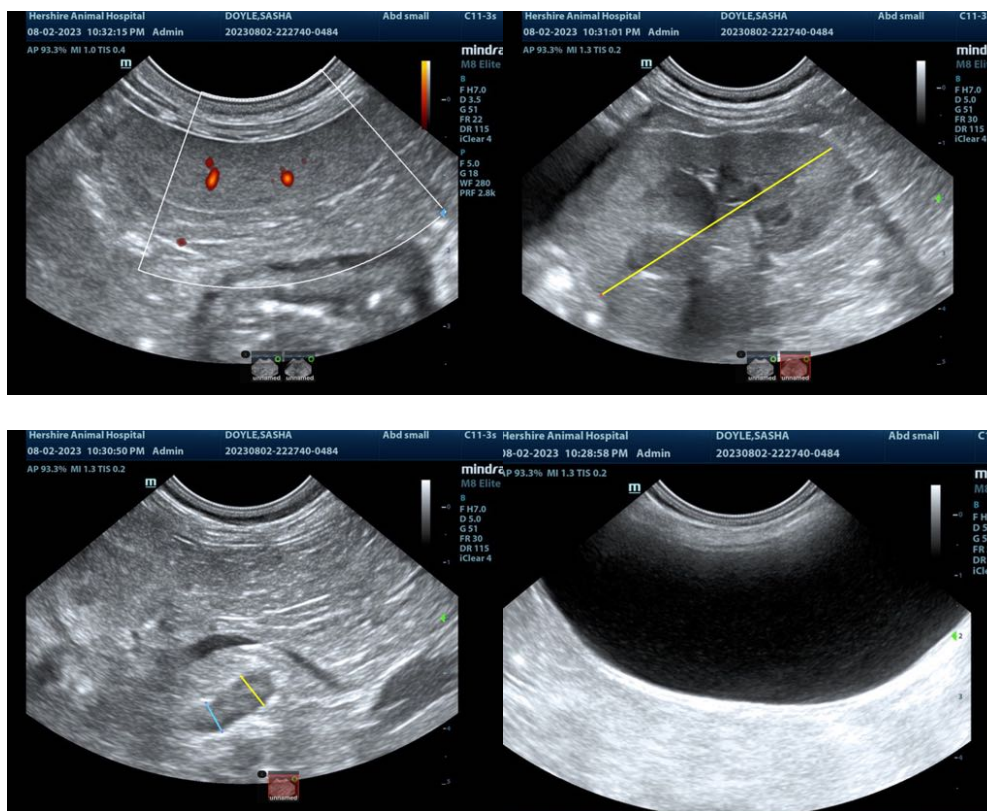
Dr. Gallisdorfer

**INVOICE**

46432

**DATE**

8/3/23



The information and recommendations provided are based on the images presented by the referring veterinarian/sonographer. No evaluation can be communicated regarding pathology that was not visible in the image/video clips provided.

Thank you for this referral. If the clinical or image interpretation does not parallel your findings or if I can be of any further assistance please contact me.

**Eric Lindquist**, DMV, DABVP, Cert. IVUSS, CEO of SonoPath.com  
info@SonoPath.com