



PATIENT

Mickey Mills

PRESENTING CLINICAL SIGNS

History: Chronic, intermittent vomiting with slightly elevated GGT.
Abnormal PE/Chem/CBC/UA Results: GGT = 13

SPECIES

Canine

ULTRASONOGRAPHIC EXAMINATION OF THE ABDOMEN

Urinary System

BREED

Chinese Crested

The **urinary bladder**, trigone, and pelvic urethra presented normal thicknesses and normal tone. The ureters were not visible which is normal. No uroliths or sediment were visualized and anechoic urine was present. No evidence of inflammatory or neoplastic changes was noted. Ureteral papillae were normal.

SEX

Neutered male

The residual prostate measured 0.5 cm.

AGE

5 years

The **kidneys** revealed normal size and structure, corticomedullary definition and ratio for this age. The cortices presented largely uniform texture with normal echogenic relationship to liver and spleen. Medullary structure differed distinctly from the cortex and no evidence of pelvic dilation was present. The capsules were acceptably uniform without significant irregularities.

WEIGHT

12.6 lbs

Adrenal Glands

The left adrenal gland was subnormal in size and measured 0.44 cm. The right adrenal gland was flattened, isoechoic and similar to the left adrenal gland. The right adrenal gland measured 0.6 cm at the cranial pole and 0.3 cm at the caudal pole.

INTERPRETED BY

Eric Lindquist, DMV
DABVP, Cert. IVUSS

Spleen

The **spleen** presented a smooth homogeneous parenchyma hyperechoic to liver and renal cortical parenchyma. The capsule was smooth without noticeable expansion or deviation from within the spleen or adjacent pathology. The splenic vasculature demonstrated normal volume without signs of congestion or thrombosis. No sonographic evidence of acute or chronic inflammatory, neoplastic, or infarctual changes was noted.

IMAGING PERFORMED BY

Brandon Holmes

HOSPITAL NAME

West Newton AC

Liver

The **liver** images submitted revealed subjectively normal liver size, contour, and structure. Parenchymal echogenicity was naturally coarse and hypoechoic to the spleen. Vascular and biliary tracts were of normal volume with no evidence of congestion. The gallbladder presented acceptably thin walls with primarily anechoic content. The cystic and common bile ducts were normal. No pathological hepatic lymphadenopathy was evident. No overt structural evidence of inflammatory, infiltrative or regenerative pathology was evident.

REFERRING VET

Dr. Holmes

INVOICE

46444

Gastrointestinal

Examination of the **gastrointestinal tract** revealed a stomach and intestine free of stasis, of normal wall thickness, acceptable curvilinear mural detail, and peristaltic activity. Small and large intestine

DATE

8/3/23



PATIENT

Mickey Mills

demonstrated normal luminal chyme and stool consistency respectively. No obstructive or overt infiltrative disease was noted. No associated abnormal lymphatic activity was noted.

SPECIES

Canine

Pancreas

The base and limbs of the **pancreas** were observed to be largely isoechoic to surrounding omental fat. Pancreatic duct and capsular contour were acceptably normal and parenchyma respected normal curvilinear patterns. No overt evidence of active inflammatory or neoplastic disease was noted.

BREED

Chinese Crested

ULTRASONOGRAPHIC FINDINGS

Flattened adrenal glands.

SEX

Neutered male

INTERPRETATION OF THE FINDINGS & FURTHER RECOMMENDATIONS

AGE

5 years

Screening for Addison's is warranted given the vague clinical signs and age. Baseline cortisol or ACTH stimulation is recommended. There was no evidence of visceral disease other than flattened, isoechoic adrenal glands.

WEIGHT

12.6 lbs

INTERPRETED BY

Eric Lindquist, DMV
DABVP, Cert. IVUS

IMAGING PERFORMED BY

Brandon Holmes

HOSPITAL NAME

West Newton AC

REFERRING VET

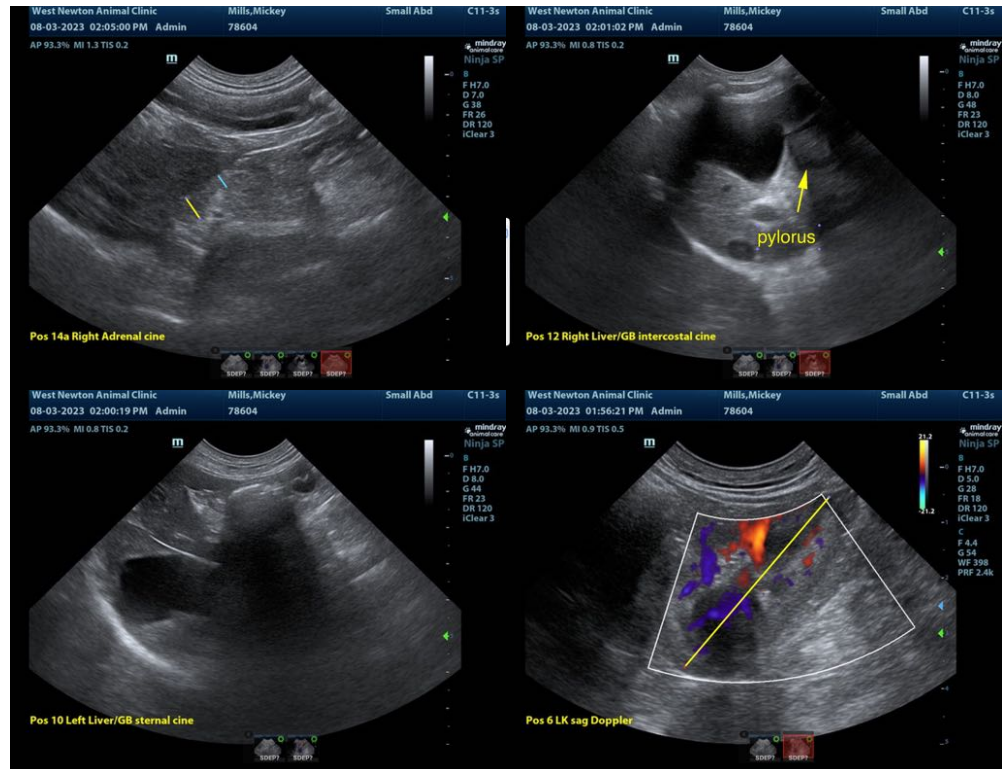
Dr. Holmes

INVOICE

46444

DATE

8/3/23





PATIENT

Mickey Mills

SPECIES

Canine

BREED

Chinese Crested

SEX

Neutered male

AGE

5 years

WEIGHT

12.6 lbs

INTERPRETED BY

Eric Lindquist, DMV
DABVP, Cert. IVUSS

IMAGING PERFORMED BY

Brandon Holmes

HOSPITAL NAME

West Newton AC

REFERRING VET

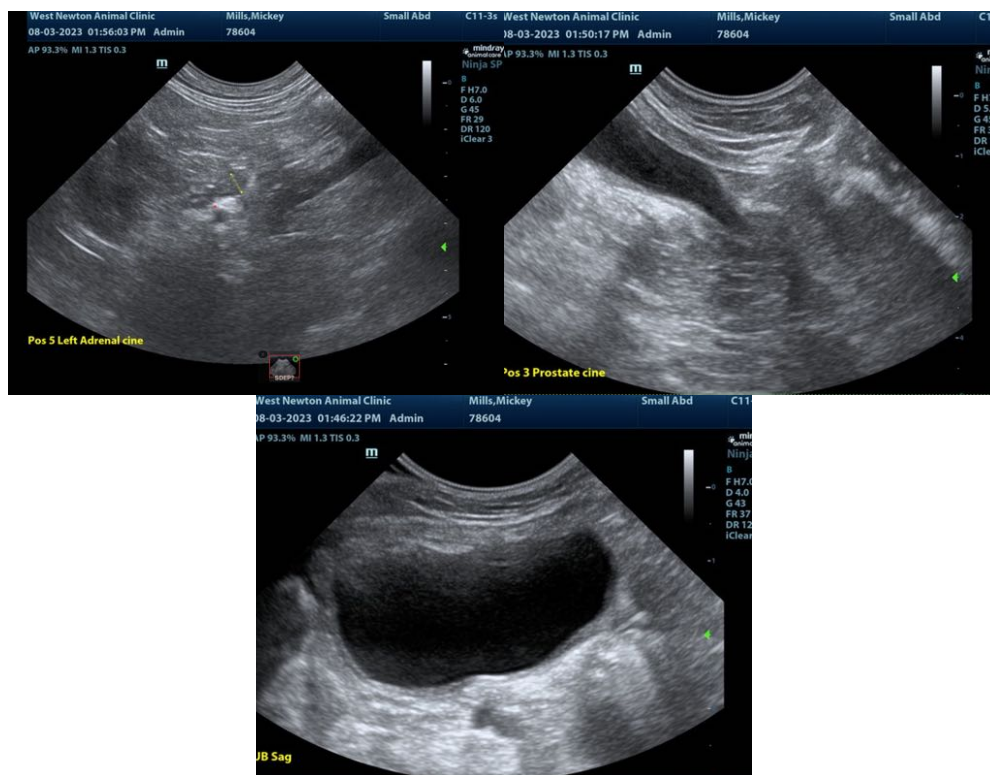
Dr. Holmes

INVOICE

46444

DATE

8/3/23



The information and recommendations provided are based on the images presented by the referring veterinarian/sonographer. No evaluation can be communicated regarding pathology that was not visible in the image/video clips provided.

Thank you for this referral. If the clinical or image interpretation does not parallel your findings or if I can be of any further assistance please contact me.

Eric Lindquist, DMV, DABVP, Cert. IVUSS, CEO of SonoPath.com
info@SonoPath.com