



PATIENT	PRESENTING CLINICAL SIGNS
Kayleigh Hamberger	Vomit with blood, mucous stool lethargy bunching of intestines Current meds Unasyn Metro Pepcid PLYte
SPECIES	ULTRASONOGRAPHIC EXAMINATION OF THE ABDOMEN
Canine	<i>Urinary System</i>
BREED	The urinary bladder , trigone, and pelvic urethra presented normal thicknesses and normal tone. The ureters were not visible which is normal. No uroliths or sediment were visualized and anechoic urine was present. No evidence of inflammatory or neoplastic changes were noted. Ureteral papillae were normal.
Cockapoo	
SEX	The kidneys revealed normal size and structure, corticomedullary definition and ratio for this age. The cortices presented largely uniform texture with normal echogenic relationship to liver and spleen. Medullary structure differed distinctly from the cortex and no evidence of pelvic dilation was present. The capsules were acceptably uniform without significant irregularities. The right kidney measured 3.96 cm.
Spayed Female	
AGE	<i>Adrenal Glands</i>
1	Both adrenal glands were visualized and recognized as having normal shape, size, position and echogenicity for this breed. The phrenic vasculature, glandular echogenicity and detail were unremarkable. Capsule, cortex, and medullary definition were normal for this age patient. The right adrenal gland measured 1.41 cm x 0.48 cm at the caudal pole and 0.68 cm at the cranial pole. The left adrenal gland measured 1.64 cm x 0.40 cm at the caudal pole and 0.41 cm at the cranial pole.
WEIGHT	<i>Spleen</i>
17.4	The spleen presented a smooth homogeneous parenchyma hyperechoic to liver and renal cortical parenchyma. The capsule was smooth without noticeable expansion or deviation from within the spleen or adjacent pathology. The splenic vasculature demonstrated normal volume without signs of congestion or thrombosis. No sonographic evidence of acute or chronic inflammatory, neoplastic, or infarctual changes were noted.
INTERPRETED BY	<i>Liver</i>
Eric Lindquist, DMV	The liver images submitted revealed subjectively normal liver size, contour, and structure. Parenchymal echogenicity was naturally coarse and hypoechoic to the spleen. Vascular and biliary tracts were of normal volume with no evidence of congestion. The gallbladder presented acceptably thin walls with primarily anechoic content. The cystic and common bile ducts were normal. No pathological hepatic lymphadenopathy was evident. No overt structural evidence of inflammatory, infiltrative or regenerative pathology was evident.
DABVP, Cert. IVUSS	
IMAGING PERFORMED BY	<i>Gastrointestinal</i>
Jenn	Examination of the gastrointestinal tract revealed a stomach and intestine free of stasis, of normal wall thickness, acceptable curvilinear mural detail, and peristaltic activity. Small and large intestine demonstrated normal luminal chyme and stool consistency respectively. No obstructive or overt infiltrative disease was noted. No associated abnormal lymphatic activity was noted.
HOSPITAL NAME	
Rockaway AH	
REFERRING VET	
Dr. Bednar	
INVOICE	
44623	
DATE	
8/3/23	



PATIENT *Pancreas*

Kayleigh Hamberger

The base and limbs of the **pancreas** were observed to be largely isoechoic to surrounding omental fat. Pancreatic duct and capsular contour were acceptably normal and parenchyma respected normal curvilinear patterns. No overt evidence of active inflammatory or neoplastic disease was noted.

SPECIES

Canine

ULTRASONOGRAPHIC FINDINGS

- Structurally unremarkable abdomen

BREED

Cockapoo

INTERPRETATION OF THE FINDINGS & FURTHER RECOMMENDATIONS

No evidence of visceral pathology responsible for the clinical history. Supportive GI care should prove effective. Dietary indiscretion, food intolerance, structurally insignificant inflammatory bowel or occult parasitism and occult Addison's are all potentials.

AGE

1

WEIGHT

17.4

INTERPRETED BY

Eric Lindquist, DMV

DABVP, Cert. IVUSS

IMAGING PERFORMED BY

Jenn

HOSPITAL NAME

Rockaway AH

REFERRING VET

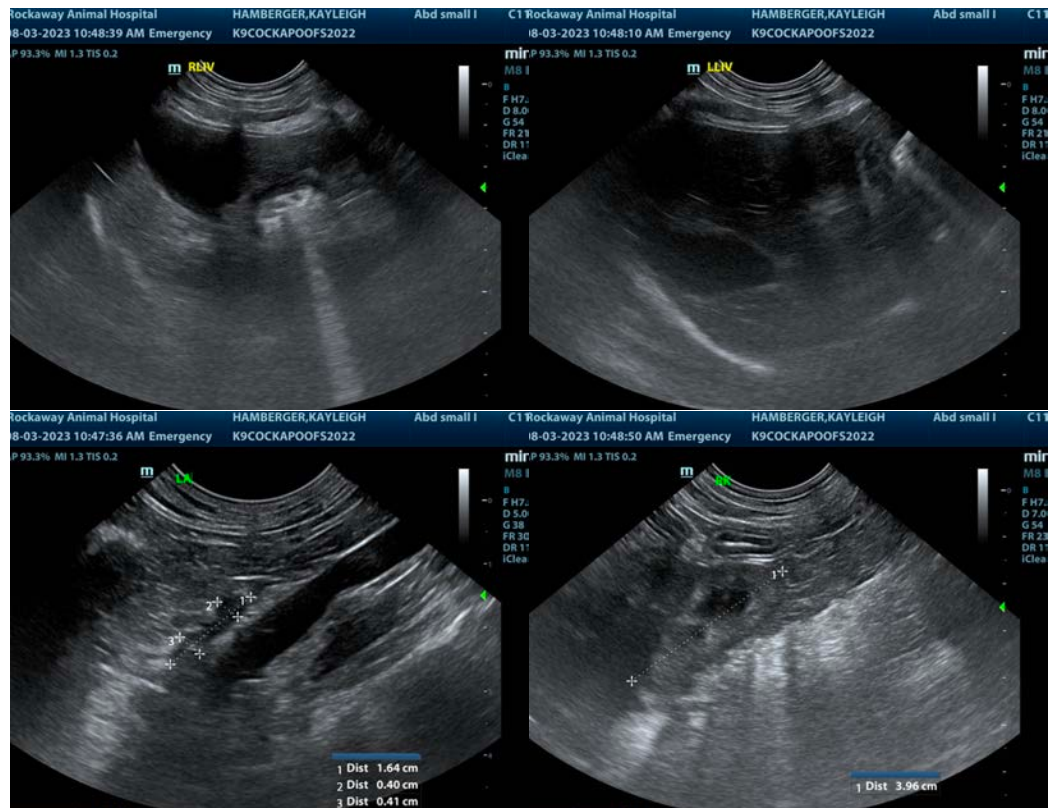
Dr. Bednar

INVOICE

44623

DATE

8/3/23





PATIENT

Kayleigh Hamberger

SPECIES

Canine

BREED

Cockapoo

SEX

Spayed Female

AGE

1

WEIGHT

17.4

INTERPRETED BY

Eric Lindquist, DMV

DABVP, Cert. IVUSS

IMAGING PERFORMED BY

Jenn

HOSPITAL NAME

Rockaway AH

REFERRING VET

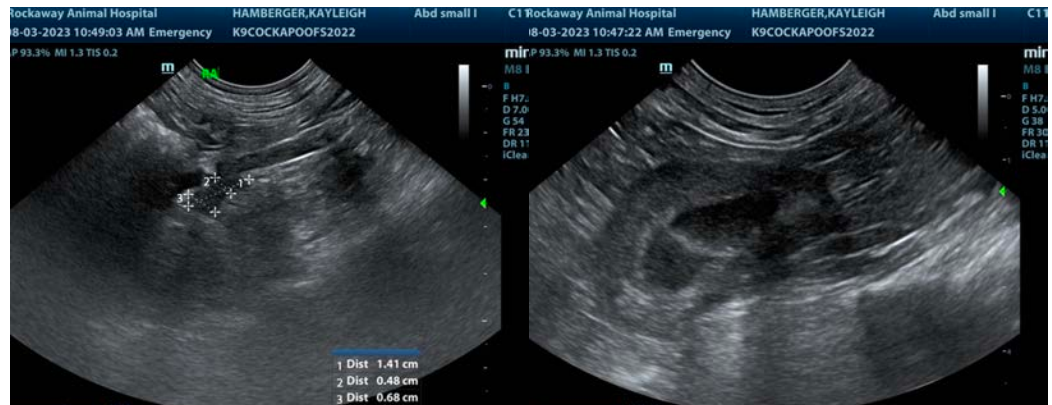
Dr. Bednar

INVOICE

44623

DATE

8/3/23



The information and recommendations provided are based on the images presented by the referring veterinarian/sonographer. No evaluation can be communicated regarding pathology that was not visible in the image/video clips provided.

Thank you for this referral. If the clinical or image interpretation does not parallel your findings or if I can be of any further assistance please contact me.

Eric Lindquist, DMV, DABVP, Cert. IVUSS, CEO of SonoPath.com

info@SonoPath.com