

PATIENT PRESENTING CLINICAL SIGNS

Cleo Berg Bred via AI (4 times) - July 1-5th.

SPECIES LIMITED ULTRASONOGRAPHIC EXAMINATION

Canine The uterus revealed at least 5-6 live fetuses. Normal fetal sac structure. Fetal fluid was anechoic, no evidence of pathology. One fetal sac appeared potentially resorbing.

BREED ULTRASONOGRAPHIC FINDINGS

- 5-6 live fetuses with one possible resorbing fetus

SEX INTERPRETATION OF THE FINDINGS & FURTHER RECOMMENDATIONS

Female No evidence of pathology. Approximately 24-28 days gestation.

AGE

2

WEIGHT

39

INTERPRETED BY

Eric Lindquist, DMV
DABVP, Cert. IVUSS

IMAGING PERFORMED BY

Torch River Vet Mobile

HOSPITAL NAME

Torch Lake Vet Clinic

REFERRING VET

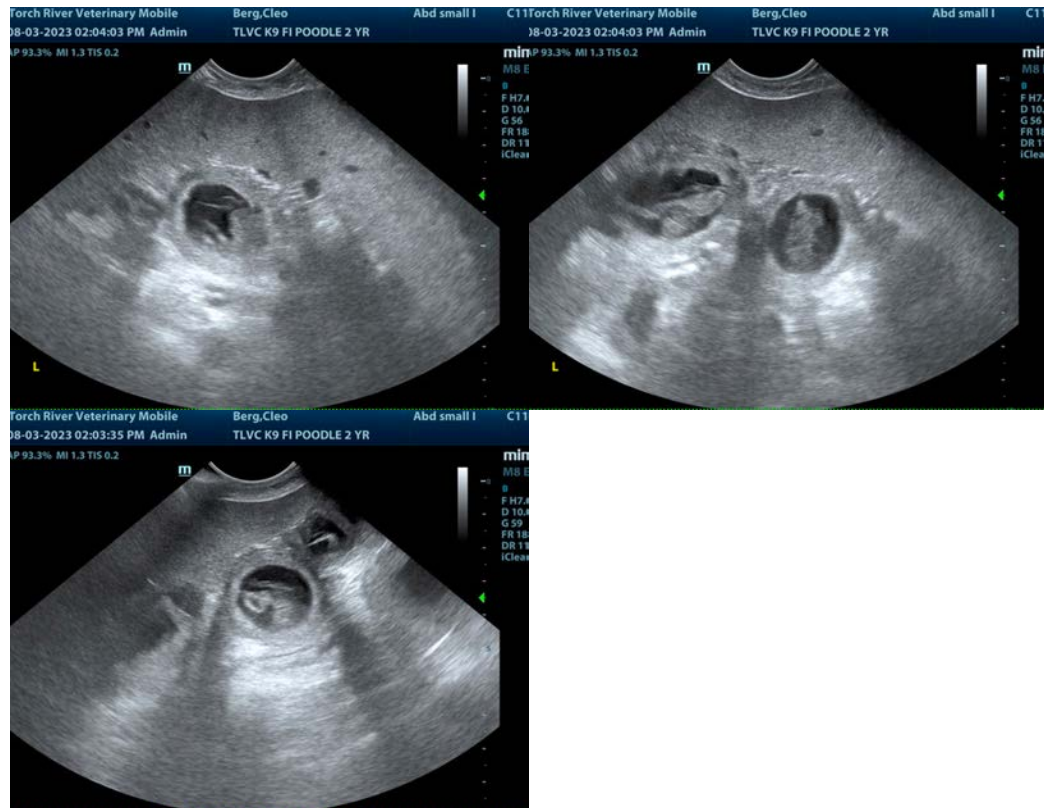
Dr. Adrienne Waffle

INVOICE

44632

DATE

8/3/23



The information and recommendations provided are based on the images presented by the referring veterinarian/sonographer. No evaluation can be communicated regarding pathology that was not visible in the image/video clips provided.

Thank you for this referral. If the clinical or image interpretation does not parallel your findings or if I can be of any further assistance please contact me.

Eric Lindquist, DMV, DABVP, Cert. IVUSS, CEO of SonoPath.com

info@SonoPath.com