



**PATIENT**

Junebug Rumachik

**SPECIES**

Feline

**BREED**

Domestic Shorthair

**SEX**

Spayed female

**AGE**

6 years

**WEIGHT**

5.5 lbs

**INTERPRETED BY**

Eric Lindquist, DMV  
DABVP, Cert. IVUS

**IMAGING PERFORMED BY**

Jill Rumachik

**HOSPITAL NAME**

Clarity Imaging LLC

**REFERRING VET**

Eric Howlett

**INVOICE**

32096

**DATE**

8/3/22

**PRESENTING CLINICAL SIGNS**

History: Pleural effusion noted by Dr. EL during abdominal study. Performed brief echo after noting slightly enlarged VHS on rads.

**ULTRASONOGRAPHIC EXAMINATION**

Pleural effusion was noted with variable areas of minor lung consolidation. The heart was normal to subnormal in volume. There was no evidence of left-sided failure. Contractility, internal diameter, septal and free wall thicknesses appeared normal.

FELINE CARDIAC PARAMETERS	BODY WEIGHT (kg)	HR (BPM)	IVSd (cm)	LVIDd (cm)	LVWd (cm)	FS (%)	EF (%)
NORMAL PARAMETER	-----	150-240	0.3-0.6	1.0-2.1	0.25-0.6	35-67	80-100
PATIENT		NM	0.5	1.1	0.4	35	
FELINE CARDIAC PARAMETERS	LA/AO (Boon)	LA/AO HEART BASE (Sisson)	LA 2D 4-chamber long axis AS to FW (Sisson) (cm)		LVOT VEL. (m/s)	RVOT VEL. (m/s)	IVRT (m/)
NORMAL PARAMETER	<1.5	0.88-1.79	0.7-1.7		<1.6	<1.3	40-60
PATIENT	1.0						NM
Adapted from June Boon, Veterinary Echocardiography, 1998 Sisson D et al. JVIM 1991; 5: 232, Jacobs et al. Am J Vet Res 1985; 46:1705							

**ULTRASONOGRAPHIC FINDINGS**

Pleural effusion.

Normal to subnormal cardiac volume.

**INTERPRETATION OF THE FINDINGS & FURTHER RECOMMENDATIONS**

There was normal to subnormal cardiac volume. There is no evidence of cardiac disease. This is non-cardiogenic pleural effusion with lung consolidation. Pleurocentesis and cytospin is recommended to assess exfoliating neoplasia versus inflammatory disease/pleuritis. Chest CT after pleural drainage would be ideal in this patient for further definition. Thoracic neoplasia/carcinomatosis, lymphomatosis or similar is suspected. There is a potential of pleuritis, yet less likely. There is a mild potential for chylothorax.



**PATIENT**

Junebug Rumachik

**SPECIES**

Feline

**BREED**

Domestic Shorthair

**SEX**

Spayed female

**AGE**

6 years

**WEIGHT**

5.5 lbs

**INTERPRETED BY**

Eric Lindquist, DMV  
DABVP, Cert. IVUSS

**IMAGING PERFORMED BY**

Jill Rumachik

**HOSPITAL NAME**

Clarity Imaging LLC

**REFERRING VET**

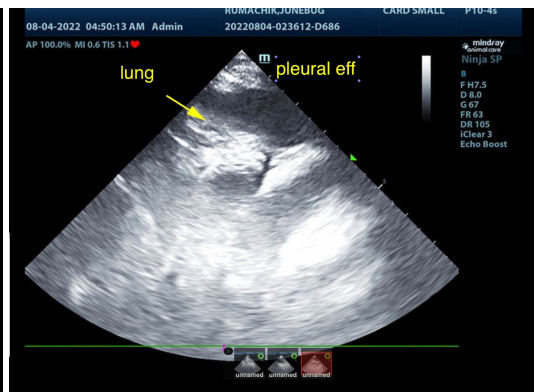
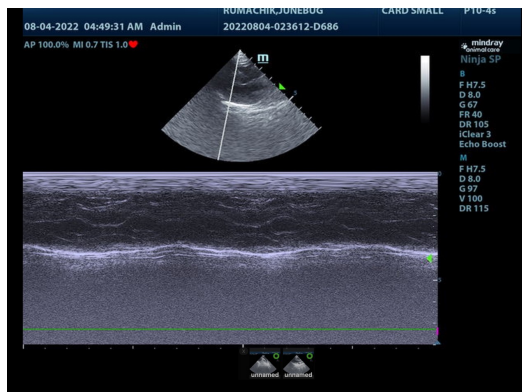
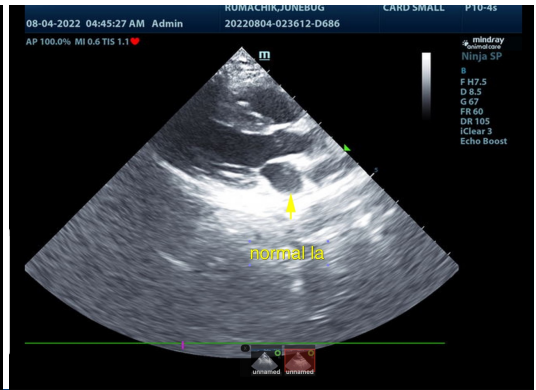
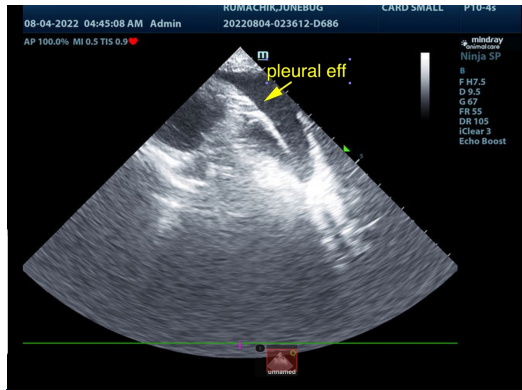
Eric Howlett

**INVOICE**

32096

**DATE**

8/3/22



The information and recommendations provided are based on the images presented by the referring veterinarian/sonographer. No evaluation can be communicated regarding pathology that was not visible in the image/video clips provided.

Thank you for this referral. If the clinical or image interpretation does not parallel your findings or if I can be of any further assistance please contact me.

**Eric Lindquist, DMV, DABVP, Cert. IVUSS, CEO of SonoPath.com**  
info@SonoPath.com