

**DATE PRESENTING CLINICAL SIGNS**

8/28/21 History: Presenting 8/26/21 for anorexia. Moderate weight loss from previous visit (5lbs since 2018). Visible icterus on exam.

PATIENT Current Medications: Since 8/26- Cerenia 6.7mg SID, Ampicillin 75mg IV BID, Metronidazole 100mg IV BID, Mirtazapine transdermal 2mg and IVF.

Lightning Smitley Lab Results: CBC NSF, CHEM ALKP 133, ALT 217, TBIL 3, Glu 165.

Radiographs: N/A

SPECIES Date of Previous IntraPet Ultrasound: No previous.

Sedation: Not needed.

Feline Stat Report: Not requested.

ULTRASONOGRAPHIC EXAMINATION OF THE ABDOMEN**BREED****Urinary System**

DSH

The **urinary bladder**, trigone, and pelvic urethra presented normal thicknesses and normal tone. The ureters were not visible which is normal. No uroliths or sediment were visualized and anechoic urine was present. No evidence of inflammatory or neoplastic changes were noted. Ureteral papillae were normal.

SEX

Neutered Male

The **kidneys** revealed largely normal size and structure, corticomedullary definition and ratio (cortex 1/3 of medulla) were essentially maintained with some age-related loss of curvilinear patterns regarding the capsule and C/M junction. The cortices presented largely uniform texture with some increased echogenicity expected for his age patient. Medullary structure differed distinctly from that of the cortex and no evidence of pelvic dilation was present. The right kidney measured 4.02 cm. The left kidney measured 4.15 cm.

AGE

2012

WEIGHT

15.2 Pounds

Adrenal Glands

Both **adrenal glands** were visualized and recognized as having normal shape, size, position and echogenicity for this breed. The phrenic vasculature, glandular echogenicity and detail were unremarkable. Capsule, cortex, and medullary definition were normal for this age patient. The right adrenal gland measured 0.4 cm. The left adrenal gland measured 0.36 cm.

INTERPRETED BY

Eric Lindquist, DMV
DABVP, Cert. IVUSS

Spleen

The **spleen** presented a smooth homogeneous parenchyma hyperechoic to liver and renal cortical parenchyma. The capsule was smooth without noticeable expansion or deviation from within the spleen or adjacent pathology. The splenic vasculature demonstrated normal volume without signs of congestion or thrombosis. No sonographic evidence of acute or chronic inflammatory, neoplastic, or infarctual changes were noted.

HOSPITAL NAME

Everhart VH

REFERRING VET

Dr. SM

Liver

The **liver** was diffusely hyperechoic to falciform fat. The gallbladder and common bile duct were unremarkable.

INVOICE

25054

Gastrointestinal

The **gastrointestinal tract** revealed minor variable thickening and echogenic submucosal changes most consistent with low grade end result of chronic GI disease such as IBD and may be related to malassimilation of nutrients if any weight loss is present. No obvious neoplastic patterns were noted and luminal content as unremarkable.

Pancreas

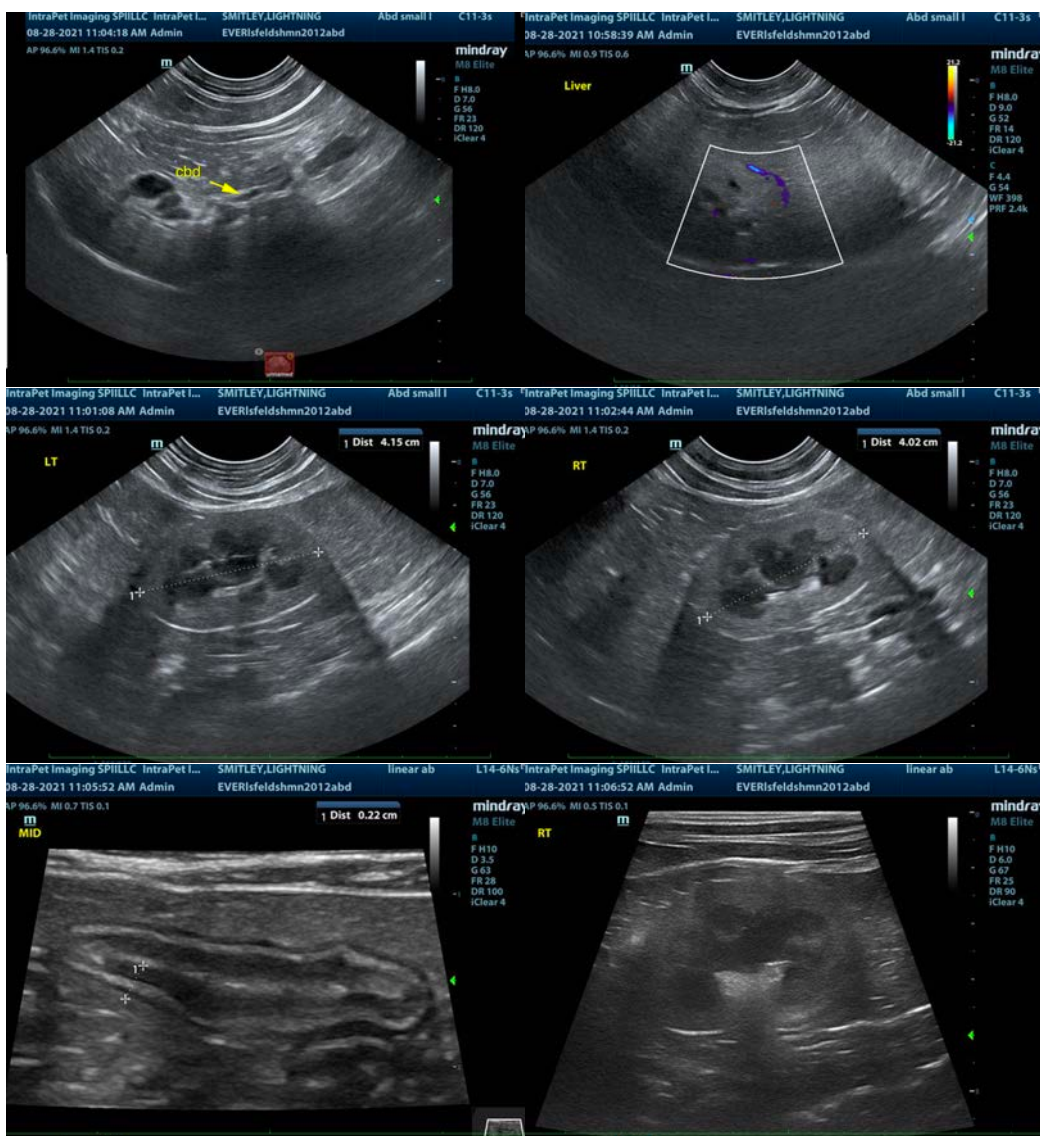
The base and limbs of the **pancreas** were observed to be largely isoechoic to surrounding omental fat. Pancreatic duct and capsular contour were acceptably normal and parenchyma respected normal curvilinear patterns. No overt evidence of active inflammatory or neoplastic disease was noted.

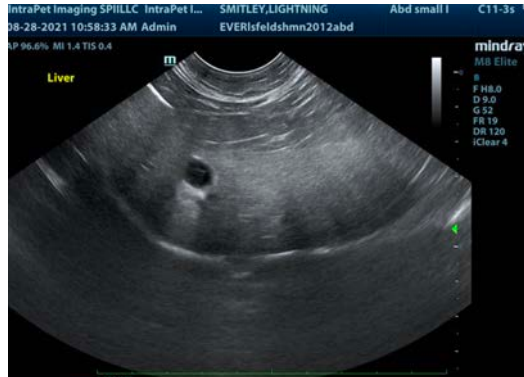ULTRASONOGRAPHIC FINDINGS

- Hepatic lipidosis pattern with age related abdominal changes otherwise

INTERPRETATION OF THE FINDINGS & FURTHER RECOMMENDATIONS

FNA warranted for further definition. No overt evidence of neoplasia. However, an underlying hepatic lymphoma cannot be completely ruled out.





The information and recommendations provided are based on the images presented by the referring veterinarian. No evaluation can be communicated regarding pathology that was not visible in the image/video clips provided.

Thank you for this referral. If the clinical or image interpretation does not parallel your findings or if I can be of any further assistance please contact me.

Eric Lindquist, DMV, DABVP, Cert. IVUSS, CEO of SonoPath.com
info@SonoPath.com