



## PATIENT

Minnie Yabroud

## SPECIES

Canine

## BREED

Toy Fox Terrier

## SEX

Spayed Female

## AGE

10 Years

## WEIGHT

6.8 Pounds

## PRESENTING CLINICAL SIGNS

History: Grade II/VI murmur. Urinating small droplets throughout walk for 6mos.

Abnormal PE/Chem/CBC/UA Results:

## ULTRASONOGRAPHIC EXAMINATION OF THE HEART

CANINE CARDIAC PARAMETERS	MR VMAX (m/s)	TR VMAX (m/s)	LA/AO (Boon method)	LA/AO (Heart Base; Swe)	FS (%)	EF (%)	EPSS (cm)
NORMAL PARAMETER	4.5-5.5	<2.7	1.3	<1.6	28-40	40-100	<0.6
PATIENT	5.8	--	1.3	1.33	38	71	0.23
CANINE CARDIAC PARAMETERS	HR (BPM)	AV VMAX (m/s)	PV MAX (m/s)	BODY WEIGHT (kg)	LA 2D short axis Base view (cm)	LVIDd Avg; 2D and m-mode short axis (cm)	LVIDs Avg; 2D and m-mode short axis (cm)
NORMAL PARAMETER	50-100	0.7-1.7	0.7-1.6	BELOW	BELOW	BELOW	BELOW
PATIENT	116	1.40	.96	--	2.2	2.11	--

## INTERPRETED BY

Eric Lindquist, DMV  
DABVP, Cert. IVUSS

## IMAGING PERFORMED BY

Shari Reffi, CVT

## HOSPITAL NAME

Rockaway AH

## REFERRING VET

Dr. Maniar

## INVOICE

12809

## DATE

8/27/21

## Cardiac Presentation

The echocardiogram in this patient demonstrated normal **left atrial** size based on 3 different LA measurement methods. Chamber volumes and echogenicity were normal. The cranial and caudal **mitral** valve leaflets presented vegetative thickening consistent with endocardiosis. Doppler indicated measurable insufficiency. The **left ventricle** presented thicknesses with linear contour and was not dilated nor restricted. The **myocardium** presented normal echogenicity without subjective evidence of significant fibrotic or ischemic disease. **Contractility** of the ventricular walls was adequate and in normal range for this patient evidenced by the fractional shortening measurement and subjective evaluation of the different regions of the myocardium. Aortic insufficiency was noted at 5.0 m/s. The **right atrium** and auricle revealed normal size, structure and content. No evidence of masses was noted or chamber overload. **Tricuspid** valvular assessment demonstrated adequate linear morphology. The **right ventricle** was of normal size (1/3 diameter of LV), chordae structure, myocardial echogenicity and thickness. **Pulmonic** tract assessment revealed normal valve structure, laminar flow, and diameter (approx.1:1 pa/ao ratio). No visible **pericardial** or free pleura fluid was noted. No echographically detectable evidence of infiltrative disease was visible. The cranial **mediastinum and pericardial regions** were free of masses in the visible window.

## ULTRASONOGRAPHIC FINDINGS

- Stage B1 valvular disease
- Mitral and aortic insufficiency

## INTERPRETATION OF THE FINDINGS & FURTHER RECOMMENDATIONS



**PATIENT**

Minnie Yabroudny

Blood pressure measurements warranted. No therapy recommended at this time. Recheck echo in 6 months or earlier if murmur grade increases or clinical signs initiate.

**SPECIES**

Canine

**BREED**

Toy Fox Terrier

**SEX**

Spayed Female

**AGE**

10 Years

**WEIGHT**

6.8 Pounds

**INTERPRETED BY**

Eric Lindquist, DMV  
DABVP, Cert. IVUS

**IMAGING PERFORMED BY**

Shari Reffi, CVT

**HOSPITAL NAME**

Rockaway AH

**REFERRING VET**

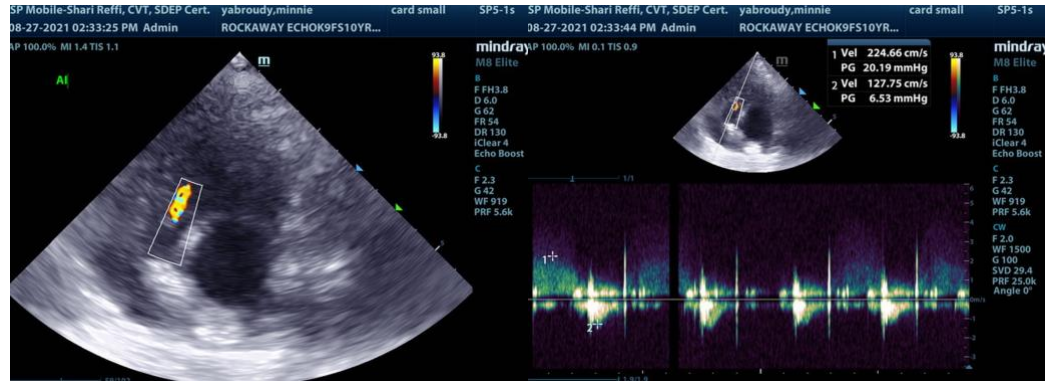
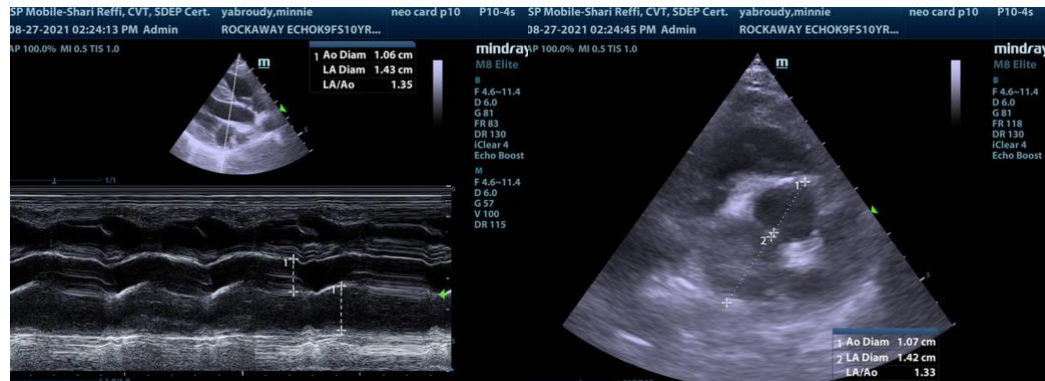
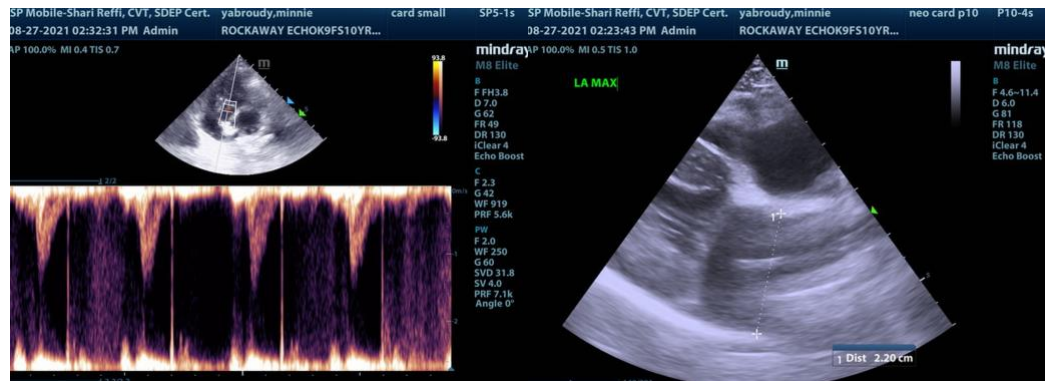
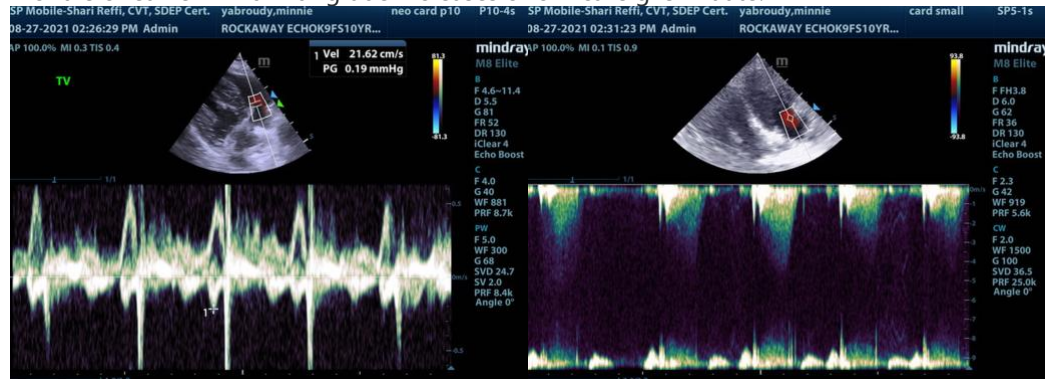
Dr. Maniar

**INVOICE**

12809

**DATE**

8/27/21





## PATIENT

Minnie Yabroudy

## SPECIES

Canine

## BREED

Toy Fox Terrier

## SEX

Spayed Female

## AGE

10 Years

## WEIGHT

6.8 Pounds

## INTERPRETED BY

Eric Lindquist, DMV  
DABVP, Cert. IVUSS

## IMAGING PERFORMED BY

Shari Reffi, CVT

## HOSPITAL NAME

Rockaway AH

## REFERRING VET

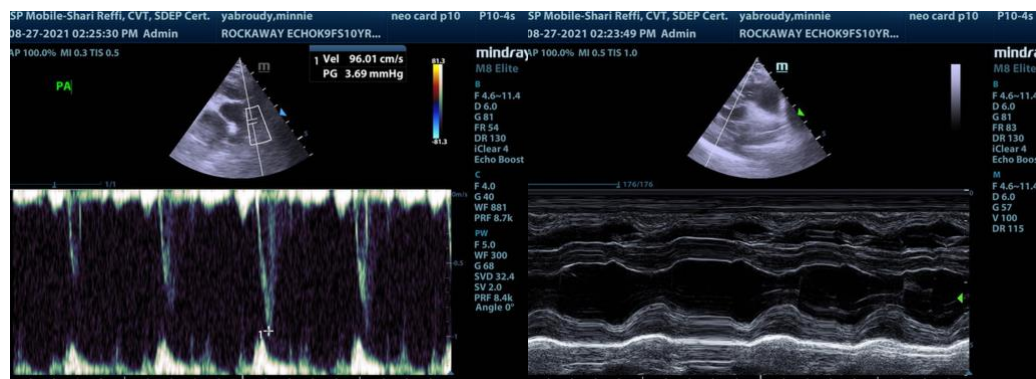
Dr. Maniar

## INVOICE

12809

## DATE

8/27/21



The information and recommendations provided are based on the images presented by the referring veterinarian. No evaluation can be communicated regarding pathology that was not visible in the image/video clips provided.

Thank you for this referral. If the clinical or image interpretation does not parallel your findings or if I can be of any further assistance please contact me.

**Eric Lindquist**, DMV, DABVP, Cert. IVUSS, CEO of SonoPath.com  
info@SonoPath.com