


PATIENT

Chancellor Bowman

PRESENTING CLINICAL SIGNS

enlarged heart on rads; perihilar interstitial pattern. not on any meds

SPECIES

Canine

ULTRASONOGRAPHIC EXAMINATION OF THE HEART
BREED

Labrador Retriever

CANINE CARDIAC PARAMETERS	MR VMAX (m/s)	TR VMAX (m/s)	LA/AO (Boon method)	LA/AO (Heart Base; Swe)	FS (%)	EF (%)	EPSS (cm)
NORMAL PARAMETER	4.5-5.5	<2.7	1.3	<1.6	28-40	40-100	<0.6
PATIENT	6.25		1.3	1.3	26	52	NM
CANINE CARDIAC PARAMETERS	HR (BPM)	AV VMAX (m/s)	PV MAX (m/s)	BODY WEIGHT (kg)	LA 2D short axis Base view (cm)	LVIDd Avg; 2D and m-mode short axis (cm)	LVIDs Avg; 2D and m-mode short axis (cm)
NORMAL PARAMETER	50-100	0.7-1.7	0.7-1.6				
PATIENT	100	2.24	1.1		4.36	4.86	

SEX

Neutered Male

AGE

6 Years

WEIGHT

88 Pounds

Cardiac Presentation

The echocardiogram in this patient demonstrated normal **left atrial** size based on 3 separate methods of LA evaluation. Mitral insufficiency noted. The **left ventricle** presented thicknesses with linear contour and was not dilated nor restricted. The **myocardium** presented normal echogenicity without subjective evidence of significant fibrotic or ischemic disease. **Contractility** of the ventricular walls was adequate and in normal range for this patient evidenced by the fractional shortening measurement and subjective evaluation of the different regions of the myocardium. The **left ventricular outflow** tract velocity was mildly excessive. The **right atrium** and auricle revealed normal size, structure and content. No evidence of masses was noted. **Tricuspid** valvular assessment demonstrated adequate linear morphology and kinesis. The **right ventricle** was of normal size (1/3 diameter of LV), chordae structure, myocardial echogenicity and thickness. **Pulmonary outflow** tract assessment revealed normal valve structure, laminar flow, and diameter (approx. 1:1 pa/ao ratio). No visible **pericardial** or free pleura fluid was noted. The cranial **mediastinum** and **pericardial** and **extra-cardiac** regions were free of masses in the visible window.

INTERPRETED BY

 Eric Lindquist, DMV
 DABVP, Cert. IVUSS

IMAGING PERFORMED BY

Diane McFadden

HOSPITAL NAME

North Warren AH

REFERRING VET

Dr. Corrado

ULTRASONOGRAPHIC FINDINGS

- Mitral insufficiency, compensated
- Minor excessive left ventricular outflow velocity
- Stage B1 valvular disease

INVOICE

25033

INTERPRETATION OF THE FINDINGS & FURTHER RECOMMENDATIONS

No evidence of volume overload. Blood pressure measurements warranted. Recheck echo in 6 months, earlier if murmur grade increases or clinical signs initiate.

DATE

8/27/21



PATIENT

Chancellor Bowman

SPECIES

Canine

BREED

Labrador Retriever

SEX

Neutered Male

AGE

6 Years

WEIGHT

88 Pounds

INTERPRETED BY

Eric Lindquist, DMV
DABVP, Cert. IVUS

IMAGING PERFORMED BY

Diane McFadden

HOSPITAL NAME

North Warren AH

REFERRING VET

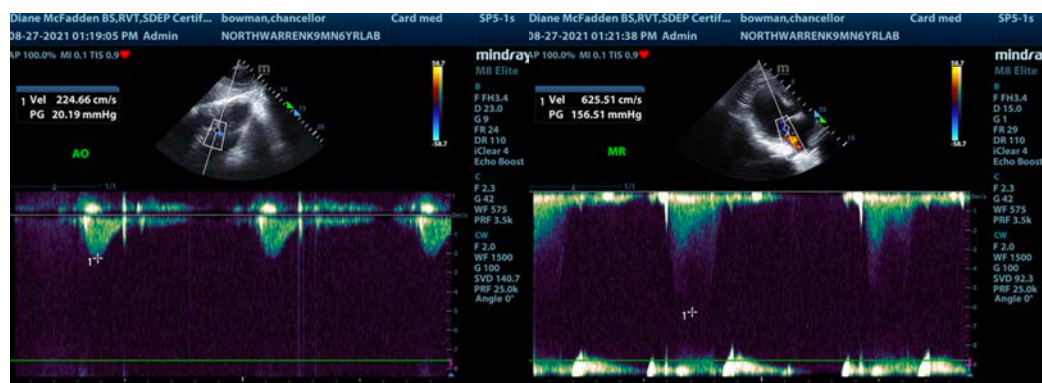
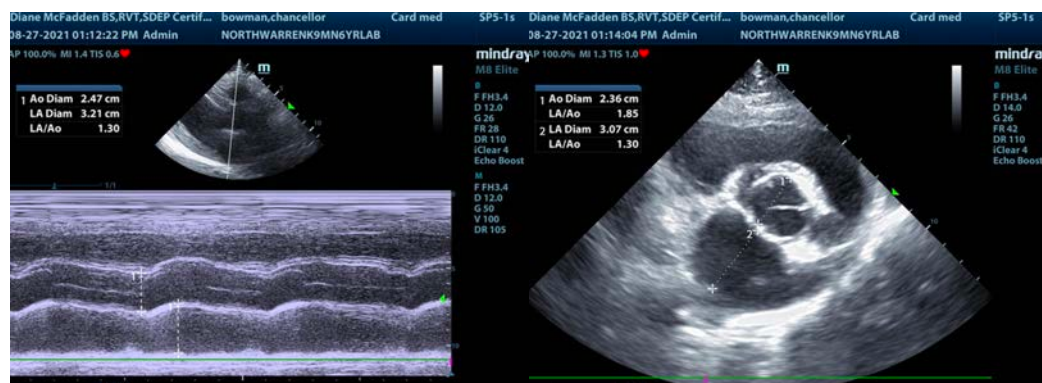
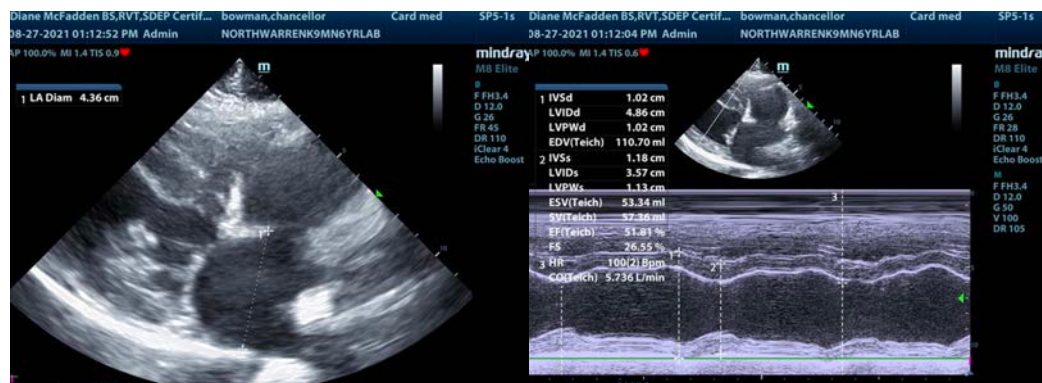
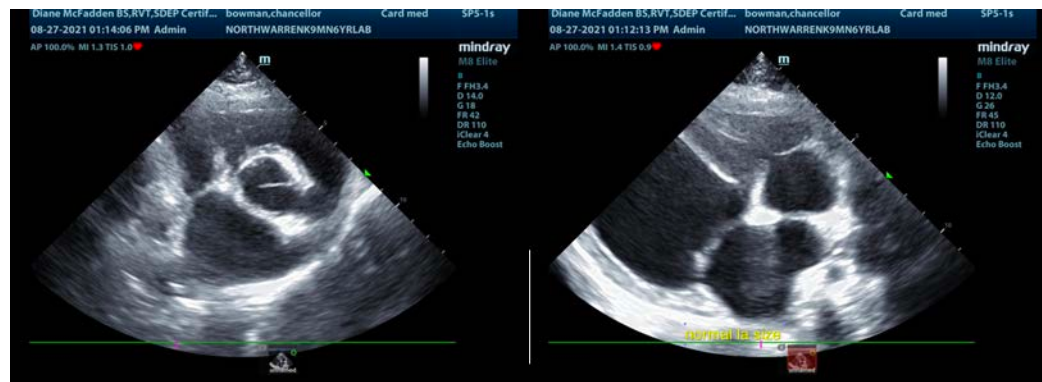
Dr. Corrado

INVOICE

25033

DATE

8/27/21





PATIENT

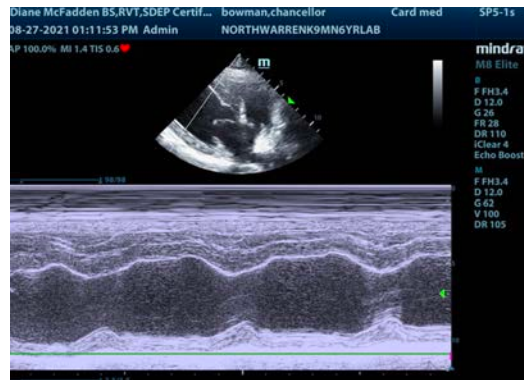
Chancellor Bowman

SPECIES

Canine

BREED

Labrador Retriever



SEX

Neutered Male

AGE

6 Years

WEIGHT

88 Pounds

INTERPRETED BY

Eric Lindquist, DMV
DABVP, Cert. IVUSS

**IMAGING
PERFORMED BY**

Diane McFadden

HOSPITAL NAME

North Warren AH

REFERRING VET

Dr. Corrado

INVOICE

25033

DATE

8/27/21

The information and recommendations provided are based on the images presented by the referring veterinarian. No evaluation can be communicated regarding pathology that was not visible in the image/video clips provided.

Thank you for this referral. If the clinical or image interpretation does not parallel your findings or if I can be of any further assistance please contact me.

Eric Lindquist, DMV, DABVP, Cert. IVUSS, CEO of SonoPath.com
info@SonoPath.com