



**PATIENT PRESENTING CLINICAL SIGNS**

**Cali Hallock** Patient presented for pacing, unable to settle at home. She has a history of straining to urinate, no blood in the urine. On presentation she was BAR, HR 160 bpm, panting. - Patient had a large urinary bladder, straining to urinate with droplets coming out - lateral radiograph taken to r/o GDV. concern for urinary mass seen

**SPECIES**

Canine

Abnormal PE/Chem/CBC/UA Results: Please see attached rads. - Mild neutrophilia with left shift. There is hypoglycemia 3.33 mmol/L and mild hypochloremia 108 mmol/L - UA: USG 1.010, pH 8.0; no signs of inflammation or infection

**BREED**

Boxer

Chest and Abdominal Radiographs: Unremarkable

**SEX**

Spayed Female

**ULTRASONOGRAPHIC EXAMINATION OF THE ABDOMEN**

**Urinary System**

The **urinary bladder** itself was unremarkable. However, it was deviated by an undifferentiated hypoechoic mass in the region of the uterine stump. The mass measured approximately 3.0 cm x 3.0 cm and deviated the urethra and cystourethral junction as well as trigone. The mass is poorly defined. The mass impinges on the colon dorsally and the bladder ventrally, where a clean separation could not be made.

**AGE**

10 Years

The **kidneys** revealed largely normal size and structure, corticomedullary definition and ratio (cortex 1/3 of medulla) were essentially maintained with some age-related loss of curvilinear patterns regarding the capsule and C/M junction. The cortices presented largely uniform texture with some increased echogenicity expected for his age patient. Medullary structure differed distinctly from that of the cortex. The right kidney measured 6.08 cm. The left kidney measured 6.26 cm with pyelectasia of 2.0 cm x 1.0 cm.

**WEIGHT**

30.9 kg

**INTERPRETED BY**

Eric Lindquist, DMV  
DABVP, Cert. IVUSS

**Adrenal Glands**

Both **adrenal glands** were visualized and recognized as having normal shape, size, position and echogenicity for this breed. The phrenic vasculature, glandular echogenicity and detail were unremarkable. Capsule, cortex, and medullary definition were normal for this age patient. The left adrenal gland measured 2.15 cm x 0.64 cm at the caudal pole and 0.43 cm at the cranial pole. The right adrenal gland measured 2.07 cm x 1.05 cm at the cranial pole and 0.7 cm at the caudal pole.

**IMAGING PERFORMED BY**

Crystal Hill

**Spleen**

The **spleen** presented a smooth homogeneous parenchyma hyperechoic to liver and renal cortical parenchyma. The capsule was smooth without noticeable expansion or deviation from within the spleen or adjacent pathology. The splenic vasculature demonstrated normal volume without signs of congestion or thrombosis. No sonographic evidence of acute or chronic inflammatory, neoplastic, or infarctual changes were noted.

**HOSPITAL NAME**

Hamilton Region EC

**REFERRING VET**

Dr. Gallienne

**Liver**

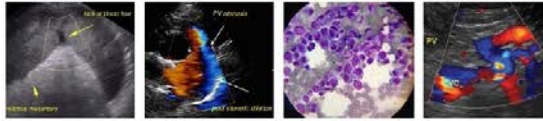
The **liver** images from right and left intercostal as well as subcostal views revealed subjectively normal liver size, contour, and structure. Some age-related parenchymal remodeling was noted but likely not clinically significant at this time. Vascular and biliary tracts were of normal volume and no evidence of congestion was noted. The gallbladder presented some dependent debris with essentially normal contour. The cystic and common bile ducts were normal. No overt evidence of active inflammatory, infiltrative or regenerative pathology was noted but should be paired with current or past LE elevations regarding any clinical significance to this presentation. The hepatic lymph nodes were unremarkable.

**INVOICE**

25006

**DATE**

8/27/21



**PATIENT** *Gastrointestinal*

Cali Hallock Examination of the **gastrointestinal tract** revealed a stomach and intestine free of stasis, of normal wall thickness, acceptable curvilinear mural detail, and peristaltic activity. Small and large intestine demonstrated normal luminal chyme and stool consistency respectively. No obstructive or overt infiltrative disease was noted. No associated abnormal lymphatic activity was noted.

**SPECIES**

Canine

**Pancreas**

**BREED**

Boxer

The base and limbs of the **pancreas** were observed to be largely isoechoic to surrounding omental fat. Pancreatic duct and capsular contour were acceptably normal and parenchyma respected normal curvilinear patterns. No overt evidence of active inflammatory or neoplastic disease was noted.

**ULTRASONOGRAPHIC FINDINGS**

**SEX**

Spayed Female

- Undefined mass at the uterine stump deviating the lower urinary tract - suspect uterine stump origin, possible colonic or urethral origin, however both of those structures appear fairly normal.

**INTERPRETATION OF THE FINDINGS & FURTHER RECOMMENDATIONS**

**AGE**

10 Years

Recommend exploratory surgery in this patient. However, complete resection may be difficult depending upon the exact origin. I do not believe this is lymph node origin, as it is solitary and somewhat tubular, which would suggest uterine stump origin such as leiomyosarcoma. CT with contrast of the pelvis and caudal abdomen may be optimal for potential surgical planning unless direct exploratory is planned.

**WEIGHT**

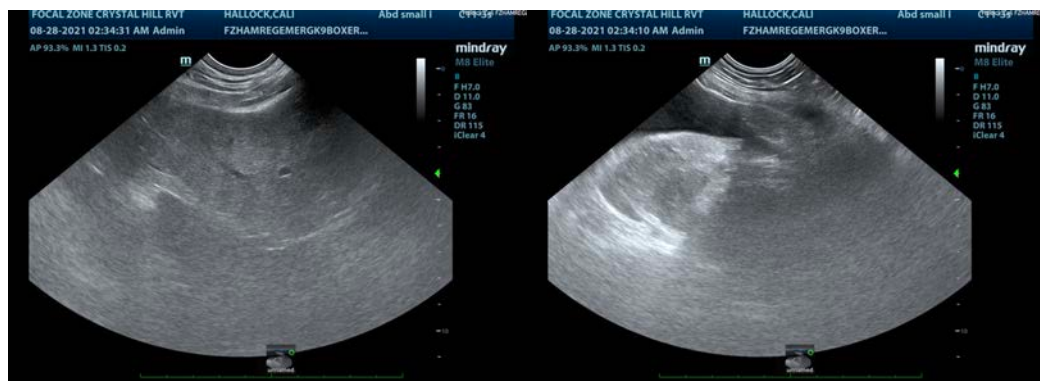
30.9 kg

**INTERPRETED BY**

Eric Lindquist, DMV  
DABVP, Cert. IVUSS

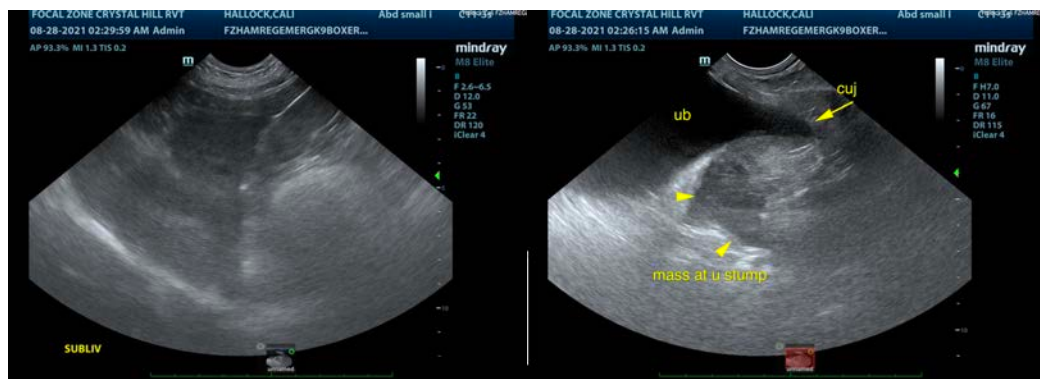
**IMAGING PERFORMED BY**

Crystal Hill



**HOSPITAL NAME**

Hamilton Region EC



**REFERRING VET**

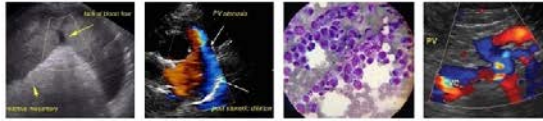
Dr. Gallienne

**INVOICE**

25006

**DATE**

8/27/21



**PATIENT**

Cali Hallock

**SPECIES**

Canine

**BREED**

Boxer

**SEX**

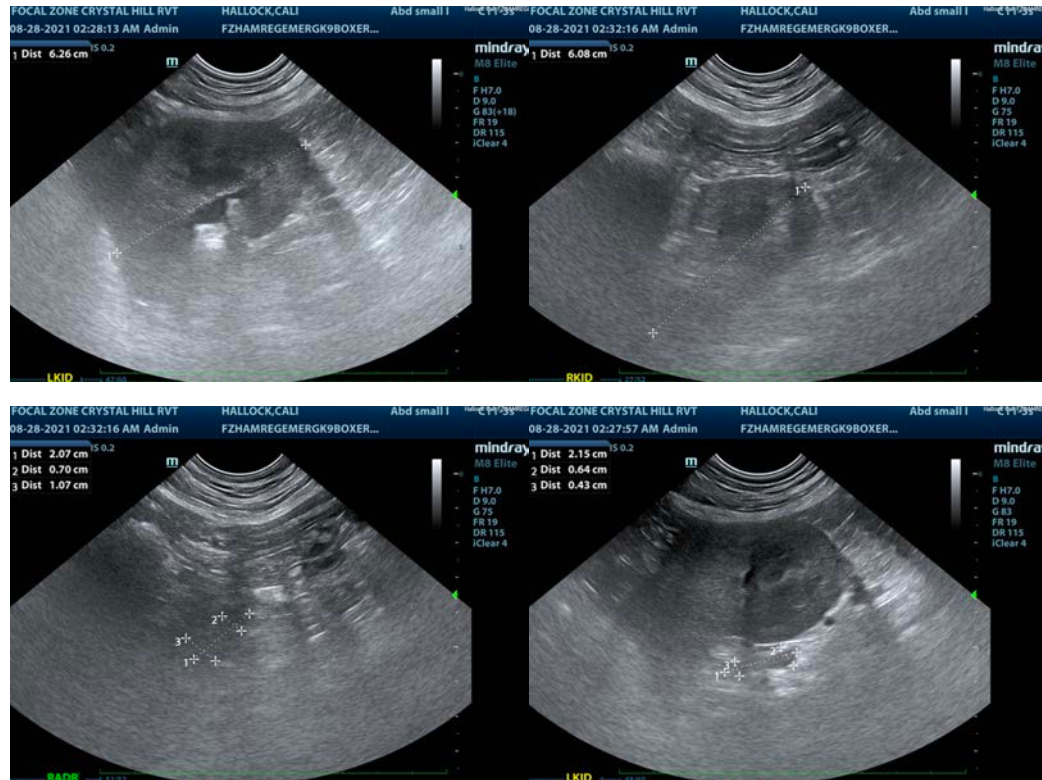
Spayed Female

**AGE**

10 Years

**WEIGHT**

30.9 kg



**INTERPRETED BY**

Eric Lindquist, DMV  
DABVP, Cert. IVUSS

**IMAGING PERFORMED BY**

Crystal Hill

**HOSPITAL NAME**

Hamilton Region EC

**REFERRING VET**

Dr. Gallienne

**INVOICE**

25006

**DATE**

8/27/21

The information and recommendations provided are based on the images presented by the referring veterinarian. No evaluation can be communicated regarding pathology that was not visible in the image/video clips provided.

Thank you for this referral. If the clinical or image interpretation does not parallel your findings or if I can be of any further assistance please contact me.

**Eric Lindquist, DMV, DABVP, Cert. IVUSS, CEO of SonoPath.com**  
Eric.Lindquist@SonoPath.com