



PATIENT

Wiggins Dierks

SPECIES

Canine

BREED

French Bulldog

SEX

Neutered Male

AGE

4 Years

WEIGHT

14.4 kg

INTERPRETED BY

Eric Lindquist, DMV
DABVP, Cert. IVUSS

**IMAGING
PERFORMED BY**

Dave Stasiuk, RDMS,
RDCS

HOSPITAL NAME

Chris Belan VS

REFERRING VET

Southern Alberta VE

INVOICE

12785

DATE

8/26/21

PRESENTING CLINICAL SIGNS

History: Seizing. Elevated liver enzymes.

Abnormal PE/Chem/CBC/UA Results:

ULTRASONOGRAPHIC EXAMINATION OF THE ABDOMEN

Urinary System

The **urinary bladder**, trigone, and pelvic urethra presented normal thicknesses and normal tone. The ureters were not visible which is normal. No uroliths or sediment were visualized and anechoic urine was present. No evidence of inflammatory or neoplastic changes were noted. Ureteral papillae were normal.

The **kidneys** revealed normal size and structure, corticomedullary definition and ratio for this age. The cortices presented largely uniform texture with normal echogenic relationship to liver and spleen. Medullary structure differed distinctly from the cortex and no evidence of pelvic dilation was present. The capsules were acceptably uniform without significant irregularities. The right kidney measured 5.64 cm. The left kidney measured 5.46 cm.

Adrenal Glands

Both **adrenal glands** were visualized and recognized as having normal shape, size, position and echogenicity for this breed. The phrenic vasculature, glandular echogenicity and detail were unremarkable. Capsule, cortex, and medullary definition were normal for this age patient. The right adrenal gland measured 0.54 cm in width. The left adrenal gland measured 0.37 cm.

Spleen

The **spleen** presented a smooth homogeneous parenchyma hyperechoic to liver and renal cortical parenchyma. The capsule was smooth without noticeable expansion or deviation from within the spleen or adjacent pathology. The splenic vasculature demonstrated normal volume without signs of congestion or thrombosis. No sonographic evidence of acute or chronic inflammatory, neoplastic, or infarctual changes were noted. Caudal folding of the spleen was noted.

Liver

The **liver** was slightly subnormal in size. Parenchymal echogenicity was naturally coarse and hypoechoic to the spleen. Vascular and biliary tracts were of normal volume with no evidence of congestion. The gallbladder presented acceptably thin walls with primarily anechoic content. The cystic and common bile ducts were normal. No pathological hepatic lymphadenopathy was evident. No overt structural evidence of inflammatory, infiltrative or regenerative pathology was evident.

Gastrointestinal

Examination of the **gastrointestinal tract** revealed a stomach and intestine free of stasis, of normal wall thickness, acceptable curvilinear mural detail, and peristaltic activity. Small and large intestine demonstrated normal luminal chyme and stool consistency respectively. No obstructive or overt infiltrative disease was noted. No associated abnormal lymphatic activity was noted.

Pancreas



PATIENT

Wiggins Dierks

The base and limbs of the **pancreas** were observed to be largely isoechoic to surrounding omental fat. Pancreatic duct and capsular contour were acceptably normal and parenchyma respected normal curvilinear patterns. No overt evidence of active inflammatory or neoplastic disease was noted.

SPECIES

Canine

ULTRASONOGRAPHIC FINDINGS

- Acute hepatic insult, structurally unremarkable liver other than slight subnormal size

BREED

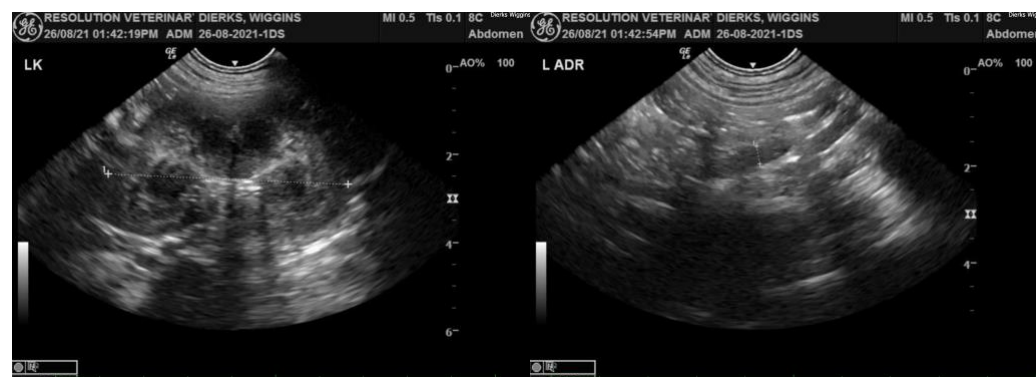French Bulldog

INTERPRETATION OF THE FINDINGS & FURTHER RECOMMENDATIONS

If ALT is major component of the liver enzyme elevation, bile acid profile warranted. No obvious portosystemic shunts. Brain CT with contrast would be ideal as well as leptospirosis titers

SEX

Neutered Male

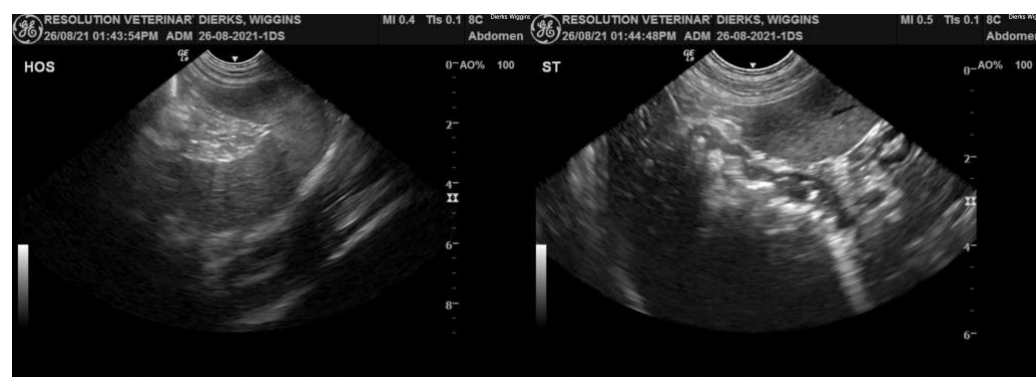


AGE

4 Years

WEIGHT

14.4 kg



INTERPRETED BY

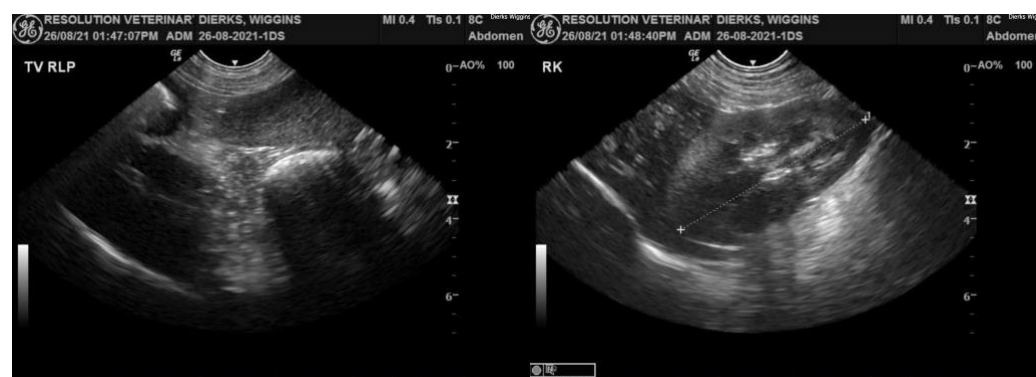
Eric Lindquist, DMV
DABVP, Cert. IVUSS

IMAGING PERFORMED BY

Dave Stasiuk, RDMS,
RDCS

HOSPITAL NAME

Chris Belan VS



REFERRING VET

Southern Alberta VE

INVOICE

12785

DATE

8/26/21



PATIENT

Wiggins Dierks

SPECIES

Canine

BREED

French Bulldog

SEX

Neutered Male

AGE

4 Years

WEIGHT

14.4 kg

INTERPRETED BY

Eric Lindquist, DMV
DABVP, Cert. IVUSS

**IMAGING
PERFORMED BY**

Dave Stasiuk, RDMS,
RDCS

HOSPITAL NAME

Chris Belan VS

REFERRING VET

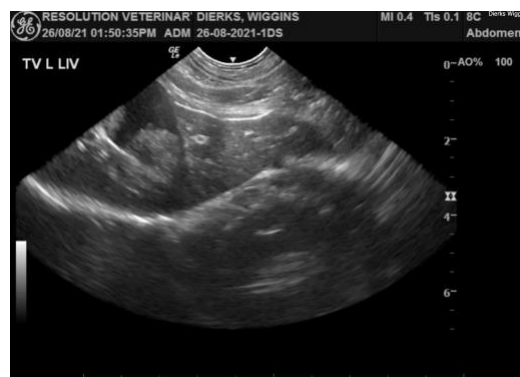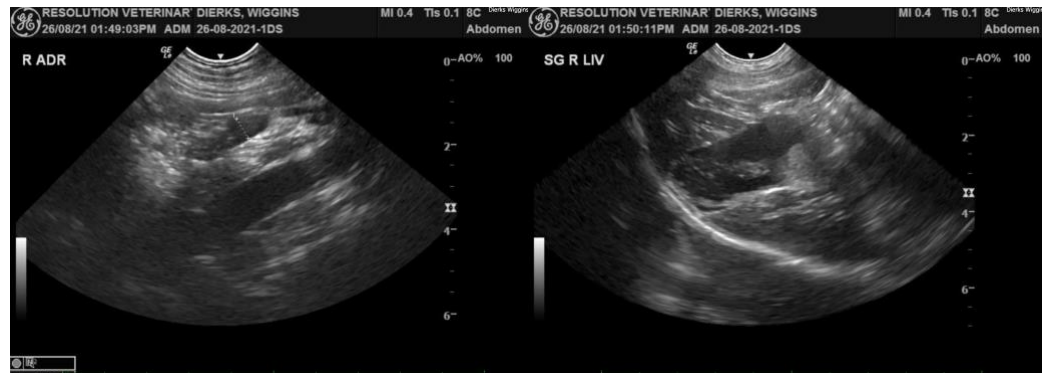Southern Alberta VE

INVOICE

12785

DATE

8/26/21



The information and recommendations provided are based on the images presented by the referring veterinarian. No evaluation can be communicated regarding pathology that was not visible in the image/video clips provided.

Thank you for this referral. If the clinical or image interpretation does not parallel your findings or if I can be of any further assistance please contact me.

Eric Lindquist, DMV, DABVP, Cert. IVUSS, CEO of SonoPath.com
info@SonoPath.com