



**PATIENT PRESENTING CLINICAL SIGNS**

Panda Fausto intermittent ataxia, looks "lost" intermittently hx of splenectomy in June likely benign

**SPECIES ULTRASONOGRAPHIC EXAMINATION OF THE HEART & ABDOMEN**

Canine

BREED

Jack Russell

SEX

Male

AGE

9 Years

WEIGHT

26

CANINE CARDIAC PARAMETERS	MR VMAX (m/s)	TR VMAX (m/s)	LA/AO (Boon method)	LA/AO (Heart Base; Swe)	FS (%)	EF (%)	EPSS (cm)
NORMAL PARAMETER	4.5-5.5	<2.7	1.3	<1.6	28-40	40-100	<0.6
PATIENT			1.15	--	35	--	0.1
CANINE CARDIAC PARAMETERS	HR (BPM)	AV VMAX (m/s)	PV MAX (m/s)	BODY WEIGHT (kg)	LA 2D short axis Base view (cm)	LVIDd Avg; 2D and m-mode short axis (cm)	LVIDs Avg; 2D and m-mode short axis (cm)
NORMAL PARAMETER	50-100	0.7-1.7	0.7-1.6				
PATIENT	--	--	0.6		2.58	2.5	

**Cardiac Presentation**

The echocardiogram in this patient demonstrated normal **left atrial** size based on 3 separate methods of LA evaluation. The cranial and caudal **mitral** valve leaflets presented normal linear structure, extension in systole, and union in diastole with normal kinesis. The **left ventricle** presented thicknesses with linear contour and was not dilated nor restricted. The **myocardium** presented normal echogenicity without subjective evidence of significant fibrotic or ischemic disease. **Contractility** of the ventricular walls was adequate and in normal range for this patient evidenced by the fractional shortening measurement and subjective evaluation of the different regions of the myocardium. The **left ventricular outflow** tract demonstrated normal laminar flow and subjective structural integrity. The **right atrium** and auricle revealed normal size, structure and content. No evidence of masses was noted. **Tricuspid** valvular assessment demonstrated adequate linear morphology and kinesis. The **right ventricle** was of normal size (1/3 diameter of LV), chordae structure, myocardial echogenicity and thickness. **Pulmonary outflow** tract assessment revealed normal valve structure, laminar flow, and diameter (approx. 1:1 pa/ao ratio). No visible **pericardial** or free pleura fluid was noted. The cranial **mediastinum and pericardial and extra-cardiac regions** were free of masses in the visible window.

**Urinary System**

The **urinary bladder**, trigone, and pelvic urethra presented normal thicknesses and normal tone. The ureters were not visible which is normal. No uroliths or sediment were visualized and anechoic urine was present. No evidence of inflammatory or neoplastic changes were noted. Ureteral papillae were normal.

The **kidneys** revealed largely normal size and structure, corticomedullary definition and ratio (cortex 1/3 of medulla) were essentially maintained with some age-related loss of curvilinear patterns regarding the capsule and C/M junction. The cortices presented largely uniform texture with some increased echogenicity expected for his age patient. Medullary structure differed distinctly from that of the cortex

**INTERPRETED BY**

Eric Lindquist, DMV DABVP, Cert. IVUSS

**IMAGING PERFORMED BY**

Jenn

**HOSPITAL NAME**

Rockaway AH

**REFERRING VET**

Dr. Maniar

**INVOICE**

24969

**DATE**

8/26/21



**PATIENT**

Panda Fausto

and no evidence of pelvic dilation was present. Cortical infarcts and minor remodeling noted. The right kidney measured 4.81 cm.

**Adrenal Glands**

**SPECIES**

Canine

Both **adrenal glands** were visualized and recognized as having normal shape, size, position and echogenicity for this breed. The phrenic vasculature, glandular echogenicity and detail were unremarkable. Capsule, cortex, and medullary definition were normal for this age patient. The right adrenal gland measured 1.64 cm x 1.35 cm at the cranial pole and 0.77 cm at the caudal pole. The left adrenal gland measured 1.36 cm x 0.43 cm at the caudal pole and 0.49 cm at the cranial pole.

**BREED**

Jack Russell

**Spleen**

The region of the **splenic fossa** was unremarkable, no evidence of pathology.

**SEX**

Male

**Liver**

The **liver** was uniformly swollen with minor, excessive gallbladder debris and over distension with dependent and suspended bile without evidence of overt mucocele formation. However, excessive sludge was present. The liver presented coarse architecture with mildly increased portal markings and subtle, mixed echogenic changes. This is consistent with vacuolar hepatopathy and some level of remodeling and history of inflammatory component. There was no overt suspicion of neoplasia. No evidence of metastatic disease.

**AGE**

9 Years

**WEIGHT**

26

**Gastrointestinal**

Examination of the **gastrointestinal tract** revealed a stomach and intestine free of stasis, of normal wall thickness, acceptable curvilinear mural detail, and peristaltic activity. Small and large intestine demonstrated normal luminal chyme and stool consistency respectively. No obstructive or overt infiltrative disease was noted. No associated abnormal lymphatic activity was noted.

**INTERPRETED BY**

Eric Lindquist, DMV  
DABVP, Cert. IVUSS

**Pancreas**

The base and limbs of the **pancreas** were observed to be largely isoechoic to surrounding omental fat. Pancreatic duct and capsular contour were acceptably normal and parenchyma respected normal curvilinear patterns. No overt evidence of active inflammatory or neoplastic disease was noted.

**IMAGING PERFORMED BY**

Jenn

**ULTRASONOGRAPHIC FINDINGS**

**HOSPITAL NAME**

Rockaway AH

- Normal echocardiogram, no evidence of primary or metastatic pathology
- Geriatric abdomen

**INTERPRETATION OF THE FINDINGS & FURTHER RECOMMENDATIONS**

No evidence of return of the prior pathology.

**REFERRING VET**

Dr. Maniar



**INVOICE**

24969

**DATE**

8/26/21



**PATIENT**

Panda Fausto

**SPECIES**

Canine

**BREED**

Jack Russell

**SEX**

Male

**AGE**

9 Years

**WEIGHT**

26

**INTERPRETED BY**

Eric Lindquist, DMV  
DABVP, Cert. IVUSS

**IMAGING PERFORMED BY**

Jenn

**HOSPITAL NAME**

Rockaway AH

**REFERRING VET**

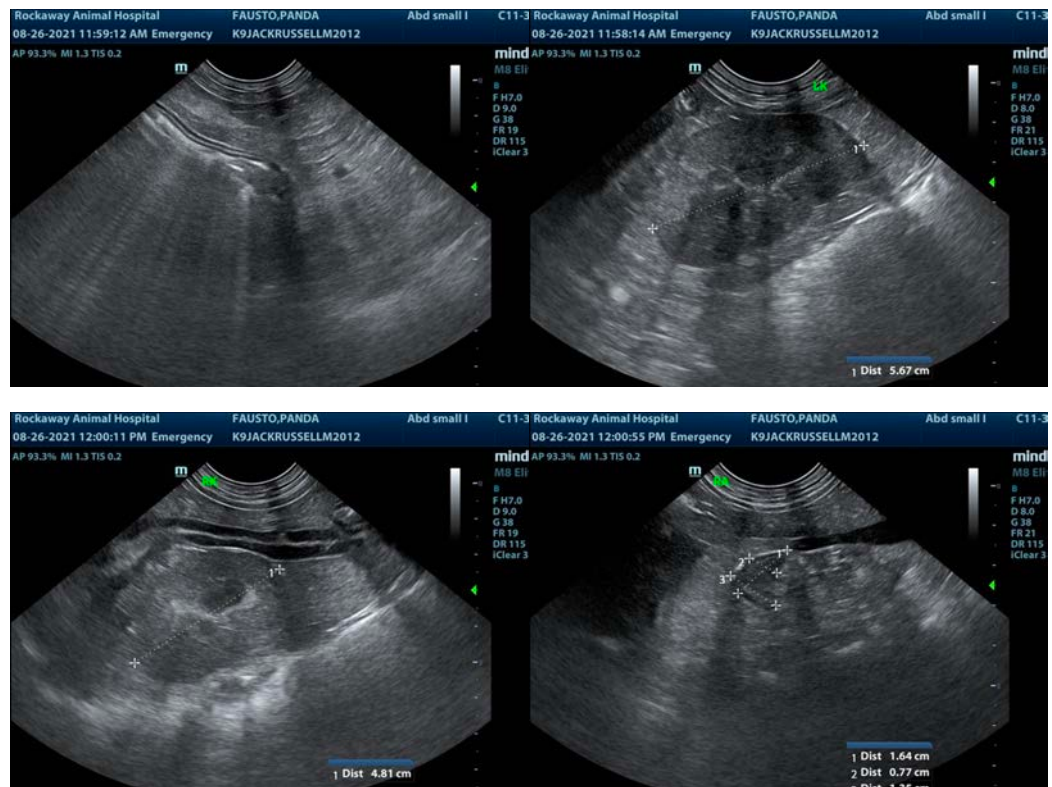
Dr. Maniar

**INVOICE**

24969

**DATE**

8/26/21



The information and recommendations provided are based on the images presented by the referring veterinarian. No evaluation can be communicated regarding pathology that was not visible in the image/video clips provided.

Thank you for this referral. If the clinical or image interpretation does not parallel your findings or if I can be of any further assistance please contact me.

Eric Lindquist, DMV, DABVP, Cert. IVUSS, CEO of SonoPath.com  
[info@SonoPath.com](mailto:info@SonoPath.com)