



PATIENT

Mowgli Dranoff

PRESENTING CLINICAL SIGNS

History: HGE, vomiting, suspect urethral calculi

SPECIES

Canine

BREED

Terrier Mix

SEX

Neutered male

AGE

6 years

WEIGHT

8 lbs

INTERPRETED BY

Eric Lindquist, DMV
DABVP, Cert. IVUSS

IMAGING PERFORMED BY

Jenn

HOSPITAL NAME

Rockaway AH

REFERRING VET

Dr. Maniar

INVOICE

91519

DATE

8/25/21

ULTRASONOGRAPHIC EXAMINATION OF THE HEART

The **left atrium and left ventricular** volume was subnormal. Contractility was poor. The cranial and caudal **mitral valve** leaflets presented normal linear structure and kinetics. The **left ventricular outflow** tract demonstrated normal laminar flow and subjective structural integrity. The **right atrium** and auricle revealed normal size, structure and content. No evidence of masses was noted or chamber overload. **Tricuspid** valvular assessment demonstrated adequate linear morphology and kinetics. The **right ventricle** was of normal size (1/3 diameter of LV), chordae structure, myocardial echogenicity and thickness. **Pulmonic** tract assessment revealed normal valve structure, laminar flow, and diameter (approx. 1:1 pa/ao ratio). No visible **pericardial** or free pleura fluid was noted or extra cardiac pathology in the visible planes. The cranial **mediastinum and pericardial regions** were free of masses in the visible window.

FELINE CARDIAC PARAMETERS	BODY WEIGHT (kg)	HR (BPM)	IVSd (cm)	LVIDd (cm)	LVWd (cm)	FS (%)	EF (%)
NORMAL PARAMETER	-----	150-240	0.3-0.6	1.0-2.1	0.25-0.6	35-67	80-100
PATIENT		NM					
FELINE CARDIAC PARAMETERS	LA/AO (Boon)	LA/AO HEART BASE (Sisson)	LA 2D 4-chamber long axis AS to FW (Sisson) (cm)	LVOT VEL. (m/s)	RVOT VEL. (m/s)	IVRT (m/)	
NORMAL PARAMETER	<1.5	0.88-1.79	0.7-1.7	<1.6	<1.3	40-60	
PATIENT		0.7	1.2 max		1.0	NM	
Adapted from June Boon, Veterinary Echocardiography, 1998 Sisson D et al. JVIM 1991; 5: 232, Jacobs et al. Am J Vet Res 1985; 46:1705							

ULTRASONOGRAPHIC EXAMINATION OF THE ABDOMEN

Urinary System

The **urinary bladder**, trigone, and pelvic urethra presented normal thicknesses and normal tone. The ureters were not visible which is normal. No uroliths or sediment were visualized and anechoic urine was present. No evidence of inflammatory or neoplastic changes was noted. Ureteral papillae were normal.



PATIENT

Mowgli Dranoff

The **kidneys** revealed normal size and structure, corticomedullary definition and ratio for this age. The cortices presented largely uniform texture with normal echogenic relationship to liver and spleen. Medullary structure differed distinctly from the cortex and no evidence of pelvic dilation was present. The capsules were acceptably uniform without significant irregularities. The left kidney measured 3.59 cm.

SPECIES

Canine

Adrenal Glands

BREED

Terrier Mix

Both **adrenal glands** were visualized and recognized as having normal shape, size, position and echogenicity for this breed. The phrenic vasculature, glandular echogenicity and detail were unremarkable. Capsule, cortex, and medullary definition were normal for this age patient.

SEX

Neutered male

Spleen

AGE

6 years

The **spleen** presented a smooth homogeneous parenchyma hyperechoic to liver and renal cortical parenchyma. The capsule was smooth without noticeable expansion or deviation from within the spleen or adjacent pathology. The splenic vasculature demonstrated normal volume without signs of congestion or thrombosis. No sonographic evidence of acute or chronic inflammatory, neoplastic, or infarctual changes was noted.

WEIGHT

8 lbs

Liver

INTERPRETED BY

Eric Lindquist, DMV
DABVP, Cert. IVUSS

The **liver** was uniform and slightly subnormal in size. The hepatic veins were not dilated. The liver had slight, chronic changes. The gallbladder and common bile duct were unremarkable.

IMAGING PERFORMED BY

Jenn

Gastrointestinal

Examination of the **gastrointestinal tract** revealed a stomach free of stasis, of normal wall thickness, acceptable curvilinear mural detail, and peristaltic activity. There was a large amount of free fluid with dilated portions of intestine. Enhanced mesentery was noted throughout the mid abdomen.

HOSPITAL NAME

Rockaway AH

Pancreas

The **pancreas** was obscured by enhanced omentum.

REFERRING VET

Dr. Maniar

ULTRASONOGRAPHIC FINDINGS

Undefined ascites.

INVOICE

91519

Minor, heterogenous hepatic changes. No evidence of passive congestion.

Dilated intestine. Concern for possible intestinal perforation or abdominal neoplasia such as lymphomatosis or similar.

DATE

8/25/21

Volume contracted heart with poor contractility, consistent with shock.



PATIENT

Mowgli Dranoff

INTERPRETATION OF THE FINDINGS & FURTHER RECOMMENDATIONS

Plasma expanders are recommended. Abdominocentesis and cytopsin is warranted to assess for neoplastic cells +/- exploratory laparotomy.

SPECIES

Canine

*Preliminary report given at 10 pm 8/26/21

BREED

Terrier Mix

SEX

Neutered male

AGE

6 years

WEIGHT

8 lbs

INTERPRETED BY

Eric Lindquist, DMV
DABVP, Cert. IVUSS

IMAGING PERFORMED BY

Jenn

HOSPITAL NAME

Rockaway AH

REFERRING VET

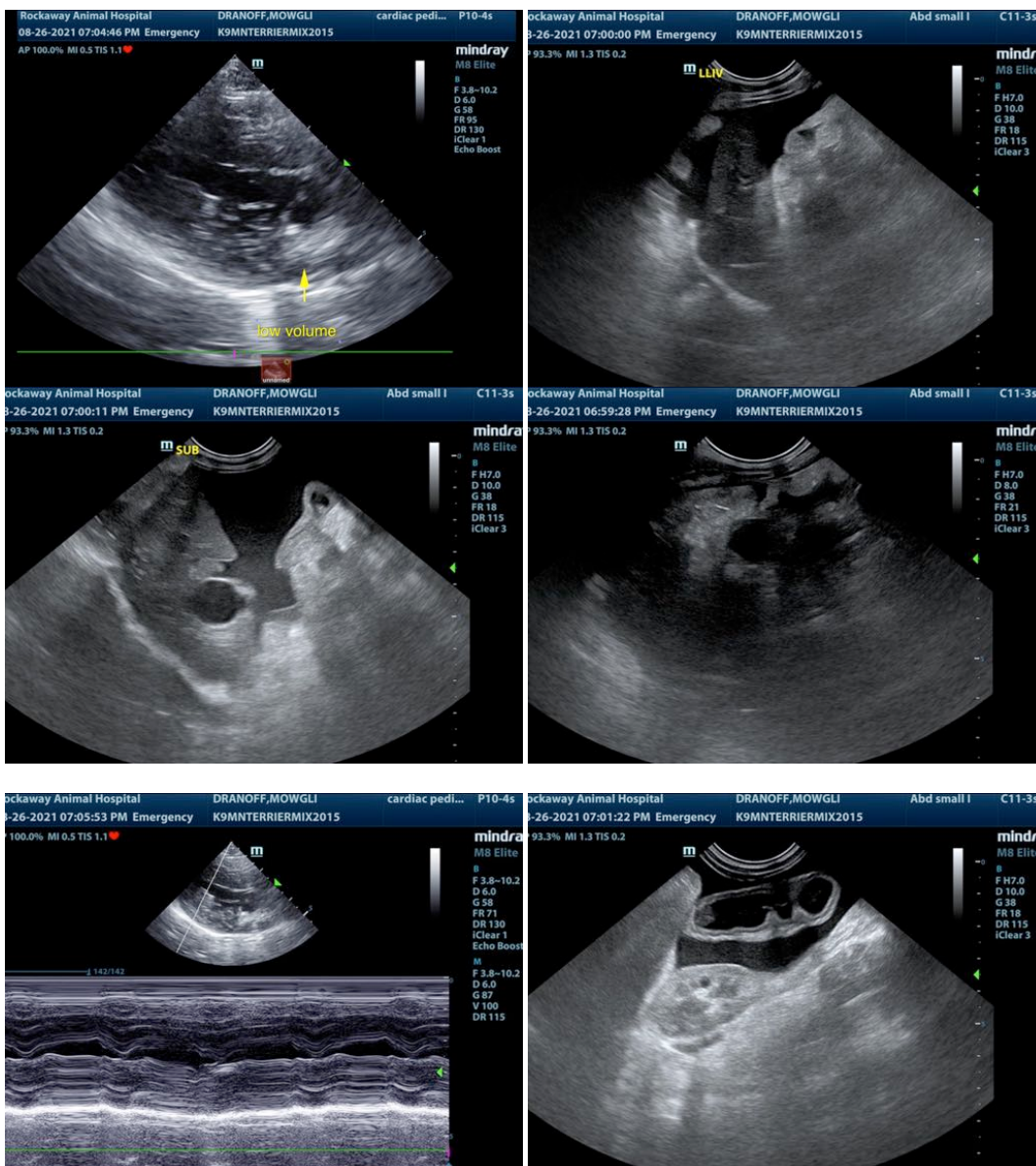
Dr. Maniar

INVOICE

91519

DATE

8/25/21





PATIENT

Mowgli Dranoff

SPECIES

Canine

BREED

Terrier Mix

SEX

Neutered male

AGE

6 years

WEIGHT

8 lbs

INTERPRETED BY

Eric Lindquist, DMV
DABVP, Cert. IVUSS

**IMAGING
PERFORMED BY**

Jenn

HOSPITAL NAME

Rockaway AH

REFERRING VET

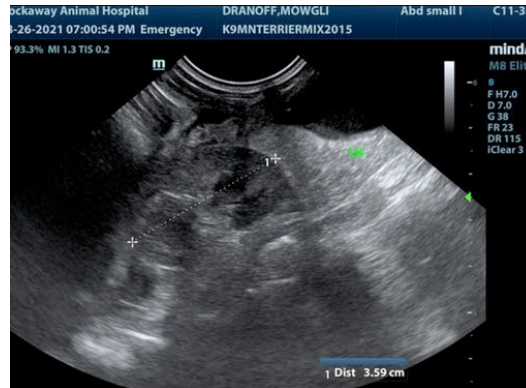
Dr. Maniar

INVOICE

91519

DATE

8/25/21



The information and recommendations provided are based on the images presented by the referring veterinarian. No evaluation can be communicated regarding pathology that was not visible in the image/video clips provided.

Thank you for this referral. If the clinical or image interpretation does not parallel your findings or if I can be of any further assistance please contact me.

Eric Lindquist, DMV, DABVP, Cert. IVUSS, CEO of SonoPath.com
info@SonoPath.com